

Care of women with female genital mutilation/ cutting

Jasmine Abdulcadi^{a, c}, Christiane Margairaz^{b, c}, Michel Boulvain^a, Olivier Irion^a

^a Department of Obstetrics and Gynaecology, University Hospitals of Geneva, Geneva, Switzerland

^b Department of Community Medicine and Primary Care, University Hospitals of Geneva, Geneva, Switzerland

^c Working Group on FGM/C, University Hospitals of Geneva, Geneva, Switzerland

Correspondence:

Olivier Irion, MD

Department of Obstetrics and Gynaecology

University Hospitals of Geneva

30, bd de la Cluse

CH-1211 Geneva 14

Switzerland

olivier.irion@hcuge.ch

Summary

In multi-ethnic European society medical professionals are faced with an increasing number of women originating from countries where female genital mutilations/cuttings (FGM/C) are practised. Recent studies, however, emphasise the lack of knowledge on this subject. This review article aims to present FGM/C as a complex socio-healthcare and multidisciplinary issue, outlining the definition, classification, epidemiology and anthropologico-legal aspects of FGM/C. It explains the approach to be adopted to FGM/C women, focusing on defibulation, clitoral restoration/repair and re-infibulation. Finally, it reports on the discussions surrounding *pricking/nicking* and the proposals for alternative rituals in recent years.

Key words: female genital mutilation; female genital cutting; FGM/C; infibulation; defibulation; reinfibulation; pricking; alternative ritual

Introduction

In multi-ethnic European society medical professionals are often confronted with patients with female genital mutilations/cuttings (FGM/C) in view of the increasing number of women originating from countries where this practice exists. In Switzerland, in particular, it is estimated that African women from these countries number approx. 10 500 and 6000–7000 among them have undergone FGM/C.

Medical professionals and cultural mediators should receive training on this subject, in terms of both communication and mediation with these patients, their partners and communities, aimed at preventing these practices and cur-

ing the related complications effectively. Information on health and the host country's laws, education, intercultural dialogue and promotion of women's health and rights are fundamental elements.

Countries such as Switzerland, United Kingdom, Sweden, Italy, Germany and Belgium have gradually introduced guidelines, whereas, at the same time, countries such as Italy, Sweden, Austria and United Kingdom, for instance, have enacted specific legislation to prevent and punish FGM/C.

This article is intended to describe the complex socio-healthcare and multidisciplinary issue of FGM/C.

Definition

The term “female genital mutilation” (also referred to as “female genital cutting” and “female genital mutilation/cutting”) concerns all procedures involving partial or total removal of the external female genitalia or other damage to the female genital organs for non-medical reasons [1].

Classification

The classification WHO 2007 is reported in table 1. It will be noticed that, in this new classification, the stretching of the clitoris and of the labia minora (Malawi, Burundi, Rwanda and Uganda) is absent.

Epidemiology

FGM/C is an ancient tradition with strong ties to cultural and ethnic identity. It crosses national frontiers and can be countrywide, as in Somalia, or concentrated in some areas which correspond to specific ethnic groups. FGM/C exists in Central and East Africa (Sudan, Nigeria, Ivory Coast, Uganda, Mali, Benin, Burkina Faso, Egypt, Ethiopia, Eritrea, Somalia, Djibouti), in Indonesia, Malaysia, part of the Persian Gulf, among some ethnic minorities in Yemen, Oman, Iran, Iraq and among immigrant communities in Europe, Canada, United States, Australia and New Zealand.

In 2008, the WHO estimated that between 100 and 140 million women have undergone female genital mutilations in the world and that every year some 3 million female children are mutilated in Africa. Countries with the highest

prevalence are Somalia (97.9% of women), Egypt (95.8%), Guinea (95.6%), Sierra Leone (94%), Djibouti (93.1%), Mali (91.6%) and Eritrea (88.7%). In countries such as India, Indonesia, Iraq, Israel, Malaysia and United Arab Emirates, official estimates are not available. Due to the activism of feminist groups, action taken by local governments and the campaigns led by the NGOs and international organisations, the dimension of the phenomenon is continuously changing [2].

In Switzerland, an estimate of 2001 showed that of 10 501 African women originating from countries where FGM/C are performed, 72% were more than 15 years old. It is estimated that about 6000 of those 10 501 women have undergone FGM/C [3]. They chiefly live in the French-speaking part of Switzerland (mainly in Geneva and Lausanne), but also in Zurich and Bern. As in other European countries, these data are an extrapolation based on the total population originating from these countries and on the prevalence of mutilation in each one. Their home countries are principally Somalia, Ethiopia and Eritrea, which are high prevalence regions where the most common type of FGM/C is infibulation [4]. Mutilated women from non-African countries were not included in this survey.

Anthropological aspects

Female genital mutilations/cuttings are very ancient practices, known since the time of the pharaohs (type III, infibulation, is still sometimes called *pharaonic circumcision*). The word *infibulation* derives from the Latin word *fibula*, the brooch used by the Romans to fix the toga, which was also used on slaves' genitals to prevent them from engaging in sexual activity.

They are not prescribed by any religion. They are wrongly associated only with Islam but also exist among Christians (Copts, Orthodox, Protestants) as well as Jews (Falashas in Ethiopia and their descendants in Israel) and Animists. Anthropologists speak of genital mutilations as an active institution determining basic relations and exchanges within the social organisation of these communities. In patriarchal societies like these the tradition of female genital mutilation ensures control of female sexuality, chastity (essential for marriage) and the honour of the community. In addition, it represents a deeply rooted social convention which confers social status on the child and her family. Non-conformity

with the practice leads to stigma, exclusion and shame. According to these traditions, mutilation is performed to allow the child to become a woman. The rite ensures honour, value, identity, pride and a sense of belonging to the cultural and social group. It is thought to protect virginity and chastity, shielding women from their sexual drives, and it guarantees marriage [5, 6]. Furthermore, infibulation is associated with beauty. Centuries of genital modifications have changed the aesthetic perception in these communities [7], and even if external genitalia are a hidden part, the fact of being soft, without hair, secretions and odour is considered sexually attractive [8]. The beliefs associated with FGM/C are manifold, some of them typical of certain countries: in Somalia it is an initiation rite where the child becomes an adult, and in Sudan one of the purposes is to decrease the vaginal opening to increase the man's sexual pleasure. In certain groups it is feared that without circumcision the clitoris may grow excessively and thus become a danger for the baby during delivery, or for the husband during sexual intercourse [5], or that it is a masculine part to be eliminated [9].

Depending on the type and traditions of a community, FGM/C are performed at different ages (during the first weeks of life, childhood, adolescence or before pregnancy). In some regions, after each delivery, a woman will be re-infibulated if the scar has been previously opened to give birth [5].

Sometimes, parents know that FGM/C can lead to health problems but they cannot see any alternative, thinking that their daughters would not be accepted by the family, the community or a future husband. For Western medical professionals and in particular physicians, although respectful of other cultures, these traditions do not have the same social, gender, aesthetic, and personal implications as for the patient but rather legal, biological and ethical implications – unnecessary psychophysical damage and violation of fundamental human rights and laws [10].

Legal aspects

Both African and Western countries have gradually introduced specific norms relating to female genital mutilations/cuttings.

In Africa, between 1994 and 2003, Ghana, Djibouti, Burkina Faso, Ivory Coast, Tanzania, Togo, Senegal, Kenya,

Table 1: Classification WHO 2007 [1].

Type I: Partial or total removal of the clitoris* and/or the prepuce (clitoridectomy).	Type Ia: removal of the clitoral hood or prepuce only Type Ib: removal of the clitoris* with the prepuce.
Type II: Partial or total removal of the clitoris* and the labia minora, with or without excision of the labia majora (excision).	Type IIa: removal of the labia minora only Type IIb: partial or total removal of the clitoris* and the labia minora Type IIc: partial or total removal of the clitoris*, the labia minora and the labia majora.
Type III: Narrowing of the vaginal orifice with creation of a covering seal by cutting and appositioning the labia minora and/or the labia majora, with or without excision of the clitoris (infibulation).	Type IIIa: removal and apposition of the labia minora Type IIIb: removal and apposition of the labia majora.
Type IV: Unclassified.	All other harmful procedures to the female genitalia for non-medical purposes, for example, pricking, piercing, incising, scraping and cauterisation.

* Notice that when total removal of the clitoris is reported, it refers to the total removal of the *external part of the body of the clitoris*.

Benin, Chad and Niger introduced laws against FGM/C, followed by Ethiopia in 2004 and Egypt in 2008. However, FGM/C are still performed clandestinely [11, 12].

Due to the arrival of immigrants from countries where FGM/C are practised, Western countries such as USA, Sweden, Norway, United Kingdom, Belgium, Italy, Spain, Austria and Denmark have also introduced specific norms governing female genital mutilations/cuttings [13]. These include not only penalising of FGM/C, but also recommendations on health promotion, care of circumcised patients and training of medical professionals. In Europe there are three main tendencies in particular:

- enactment of legislation specifically directed against FGM/C (Sweden, Norway, United Kingdom);
- introduction of a specific article, act or reference concerned with FGM/C (Austria, Belgium, Italy, Spain, Denmark);
- punishment of FGM/C based on existent laws on bodily injury (Switzerland, France, Germany, Finland, Greece, Netherlands) [13].

In Switzerland, as in other countries, there is no specific law against FGM/C. However, performing FGM/C is forbidden. It is considered a crime against bodily integrity (article 122 of the Swiss Criminal Code) [15]. (Note added in print: On December 16th, 2010, the Swiss Parliament approved the introduction in the penal law of a specific article to punish the authors of FGM/C [article 124].) Two legal documents (Niggli and Berkemeier 2007; Trechsel and Schlauri 2004) issued by UNICEF Switzerland have differentiated cases depending on the type of mutilation. Type II and Type III are considered serious bodily injuries and are mentioned in article 122 of the Swiss Criminal Code (automatic legal proceedings; offence punishable by a maximum 10-year prison sentence or at least a 180-day fine). On the other hand, Type I and Type IV need to be judged case by case; for example in cases of *pricking* or removal of the hood of the clitoris, it is necessary to evaluate possible short or long-term psychophysical consequences [16, 17]. In this case the mutilation can be treated as a simple or a serious body injury (article 123 of the Swiss Criminal Code, prosecution following a complaint, and punishable by a maximum 3-year prison sentence or a fine).

It is important to stress that in Switzerland it is not only forbidden to perform FGM/C, but also to plan it, for example in the case of immigrants living in Switzerland who plan to do it abroad during children's holidays.

When a medical professional observes a mutilation on a minor, he has the right to alert the Juvenile Court (article 364 of the Swiss Criminal Code) [18]. This right may even be an obligation in certain cantons, and hence it is advisable to be well informed concerning local laws, for example by seeking advice from the cantonal medical officer (*médecin cantonal*) [15].

In 2008, two verdicts in connection with FGM/C were handed down in Switzerland. In one case the mutilation was done in the host country and in the second abroad, in Africa [19, 20].

On 12 February 2009, the Legal Affairs Committee of the National Council (lower house of Parliament) unanimously adopted a pre-project for an article of the Criminal Code specially designed to repress FGM/C. A specific group was

tasked with refining the final version of the project, which was approved on 30 April 2010 [14].

The Swiss Academy of Medical Science and the Children's Rights Convention, ratified by Switzerland in 1997, also condemn FGM/C.

In other countries the situation is different. In France, between 1985 and 2006 some 40 cases related to FGM/C [21] came to court; none in United Kingdom, where the British authorities have the power to protect children by forbidding travel abroad without the permission of the court (section 47 Children's Act 1989) [13].

Health consequences

The medical complications of FGM/C depend on different factors:

1. Hygienic and socio-economic conditions in which the practice is performed (rural versus urban and less developed versus more affluent settings).
2. Pre-existing health and nutritional status of the baby or child (disease, malnutrition).
3. Modalities of execution. Experience and competence of the operator: traditional practitioner vs medical professional. Material employed: unsterilised or surgical single-use tools: surgical thread vs agave or acacia thorns. Hygienic conditions: availability of water, antibiotics and medication to heal the injury during the post-mutilation period. Number of interventions: in case of infibulation, when the opening is considered too wide, the mutilation can be performed a second time with fresh risk of complications.
4. Type of mutilation. In the case of infibulation, the urethral orifice and part of the vaginal opening are covered by the scar. In a virgin infibulated woman the small opening left for the menstrual blood and the urine is not wider than 2–3 mm; in sexually active women and after the delivery the vaginal opening is wider but the urethral orifice is often still covered by the scar.
5. Possible psychological, physical and psychophysical complications connected with FGM/C.

FGM/C complications may be immediate or long term. Some mutilated women may suffer from medical and/or psychological complications without considering them to be related to FGM/C but rather as the "normal condition" of being a woman. For this reason physicians should approach these patients carefully and sensitively, without emotionally hurting them or judging their culture.

Immediate complications may be extreme pain; urinary burning and acute urinary retention; haemorrhage, anaemia, shock or even death, depending on the bleeding; infection and dehiscence of the injury, which can be stitched several times; urinary tract infections and septicemia; tetanus, infectious diseases such as HIV or hepatitis in the case of unsterilised instruments used in more than one operation without disinfection.

Late complications are those that are more often seen in Western countries and depend on the type of mutilation. In the case of infibulation, the most frequent complication is severe dysmenorrhoea, due to the mechanical obstacle

to menstrual flow, inflammatory and/or psychosomatic factors. In addition, when the vaginal opening of a virgin infibulated woman is too narrow, the blood can stagnate in the vagina or in the uterus, causing haematocolpos and haematometra. Other possible long-term complications are chronic pelvic infections; chronic or repeated vaginitis, especially after the first sexual intercourses; repeated urinary infections, drop by drop and prolonged micturition (especially in virgin infibulated women) and dysuria because of the difficult flow of urine, which may stagnate behind the scar and cause the formation of small stones; cutaneous or sebaceous retention cysts in the scar, which can reach considerable dimensions or become an abscess in the event of infection [22]; cli-toral retention cysts [23]; superficial and deep dyspareunia, especially at the beginning of sexual activity when penetration is painful and difficult for both partners.

During labour it may be difficult to evaluate cervical dilatation, monitor the progress of presentation and insert a urinary catheter [22]. Women with FGM/C are significantly more likely than those without FGM/C to have adverse obstetric outcomes, and the risks seem to be greater with more extensive types of mutilation [24]. The second stage of labour may be prolonged, with negative effects on the foetus. There is a risk of perineal or anal sphincter lacerations, sometimes responsible for incontinence and fistulae (more common in developing countries than in Western countries). Third-degree lacerations and emergency caesarean section are significantly more frequent in the group of women with FGM/C than in the control group [25].

In some countries, such as Sudan and Somalia, re-infibulation (re-stitching of the scar of the infibulation previously opened to allow the delivery) may be performed after the delivery [22].

Psychological complications depend on the socio-cultural context, the experience of mutilation and the woman's degree of awareness. The circumcision may be considered positively (pride, beauty, cleanliness, faithfulness to one's husband, respect for tradition) and in this case every physical, psychological and sexual complication is often denied because being circumcised is seen as normal [26]. On the other hand, young or adult women who underwent FGM/C and then moved to Western countries where they grew up or have lived, can experience psychological consequences after being confronted with cultural differences between their country of origin and their host country. Realising that FGM/C are not a universal tradition, that it is sometimes viewed extremely negatively, and that they are considered to be mutilated can be a shock. Important internal conflicts may arise [27] concerning their identity and loyalty to their own culture. They may experience feelings such as humiliation, powerlessness, inhibition, sense of betrayal of the family and shame. Furthermore, the change of the image and of the perception of their genitalia may cause a "psychological mutilation" regarding their sexuality (inhibition of orgasm and sexual problems independent of the real physical damage) [7]. The physician should be particularly alert to these possible psychosexual complications.

The real implications for sexuality may be diverse and, in the case of sexual dysfunctions, it should not be assumed that the physical mutilation is the only incurable cause;

on the contrary, the patient's total situation should be considered. Sexual problems can and must be treated in conjunction with appropriate sexual therapy, involving the partner if possible. In the case of infibulation, defibulation should be proposed [10, 26, 28].

A recent study showed that societies should give top priority to preventing FGM/C, not only to fight against a human rights violation and discrimination against women, but also to avoid the costs to the society and the healthcare system: in 6 African countries investigated, each mutilated child represents a future of possible health complications, costs and life years lost. The costs of government efforts to prevent FGM/C will be offset by savings from preventing obstetric, gynaecological and psychosexual complications [29].

FGM/C patient care

Women with FGM/C may see a professional for various reasons, but there are three particular subjects to be dealt with: defibulation; clitoral restoration/repair and re-infibulation.

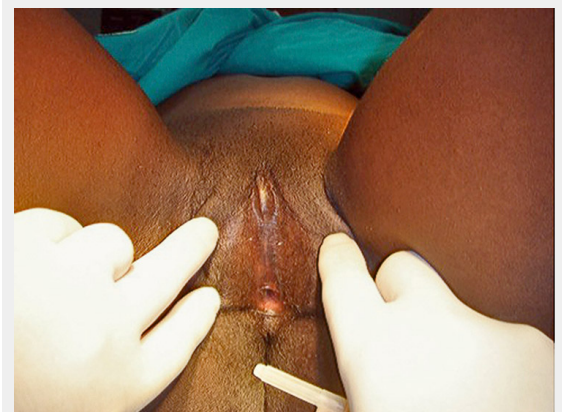

Figure 1

FGM/C type IIIb (virgin). Photo courtesy of Reference Centre for Preventing and Curing FGM, Department of Gynaecology, Perinatology and Physiology of Reproduction of Florence, Italy.

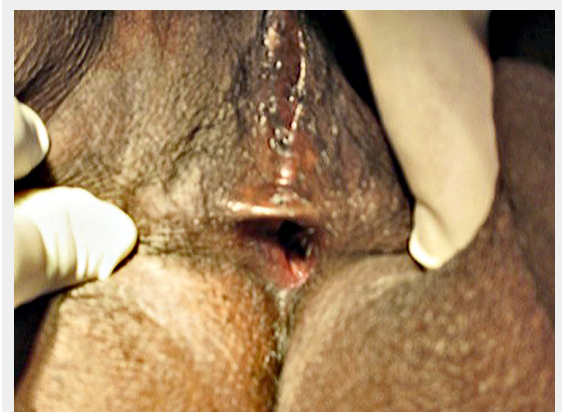


Figure 2

FGM/C type IIIb (sexually active). Photo courtesy of Reference Centre for Preventing and Curing FGM, Department of Gynaecology, Perinatology and Physiology of Reproduction of Florence, Italy.

Defibulation is a surgery that exposes the vaginal opening and the urethral meatus (partial defibulation) and the clitoral tissue and sometimes the whole intact body of the clitoris (total defibulation) which were covered by the scar of the infibulation. Technically speaking, it is usually a simple procedure. However, it requires very special and complex care as the patient may experience doubts, resistances or fear of exclusion from her own community. Furthermore, it is a medical procedure which promotes women's health by allowing gynaecological screenings such as the PAP test, instrumental exams such as hysteroscopy, transvaginal ultrasound or insertion of a urinary catheter. It renders vaginal delivery easier, decreases the risk of urogenital infections and is part of the psychosexual therapy of dysfunctions such as painful penetration and dyspareunia.

There are two different defibulation techniques. Both are ambulatory and can be performed with local or general anaesthesia: surgery with scissors or scalpel is the commonest and simplest. It should be employed when the infibulation scar is thin and uncomplicated and when it is possible to rebuild the previous anatomy of external mutilated genitals in the best possible way. When the scar is thick or a keloid, in the presence of retention cysts and in the absence of tissue to rebuild the labia, it may be preferable to choose laser surgery. After defibulation, accurate hygiene, daily care with anaesthetic, antibiotic and/or oestrogen creams to avoid re-sealing of the edges of the scar during the healing process, which lasts about one week, are recommended. The patient is advised to urinate in warm water, sometimes disinfected, to avoid burning sensations during urination.

The consultations preceding defibulation are of fundamental importance for discussion, information and education of the couple and their families, and for checking what they know or think about the physiological anatomy of the female genitalia. The questions about physical virginity are frequent in this cultural context and it is necessary to explain carefully what it is in appropriate language, without suggesting or leaving wrong ideas about it. It is advisable, for example, to explain the existence of different physiological shapes of the hymen and the possible impact of sexual intercourse on it. When the patient asking for defibulation

is a virgin woman consulting with her future husband and/or parents, it should be explained to them that the operation has no impact on the hymen. It is also the appropriate time to explain that female genital mutilations are illegal, dangerous and harmful practices and that they are not recommended by any religion. The couple can be made responsible for the care of their future female children's integrity. The dialogue should be conducted without condemnation or sense of superiority, answering any question the patient puts. It is important to give explanations and information about the vulvar anatomy after the operation, coming to an agreement with the patient on the level of the scar opening. Many women, such as Somali patients, do not want to feel "completely opened" and ask for the incision to be stopped just above the urethral meatus to ensure normal micturition. It is important to inform the patient that the urine flow will become continuous and faster, to prevent her from being frightened by this new feeling. Written informed consent is required.

In some contexts only a few married women accept or ask for defibulation with the husband's agreement. The operation is then kept secret to avoid exposing the husband to ridicule from their own family and community, as the defloration of the scar is an important demonstration of virility: a man who allows his wife to be "opened" by a surgeon is criticised. However, young women start to ask spontaneously to be "opened" before the planned wedding and to improve their health. This happens especially when women talk among themselves about the benefits of defibulation [30, 31].

Defibulation can be performed during pregnancy. In this case, the choice of the right moment is controversial because there are few studies on this topic and no official recommendations. It can be performed during the first trimester after the dating ultrasound [30, 31] or later, during the second trimester or at the moment of labour, depending on the centre's recommendations or guidelines. In Switzerland, in most cases, an intra-partum defibulation is chosen [15]. Intra-partum defibulation is carried out with scissors or scalpel along the median line of the scar up to the urinary meatus or the clitoral tissue, suturing the edges with simple haemostatic or continuous stitches after delivery. The necessity of episiotomy is evaluated during the second stage of labour [15, 30–32]. Defibulation during pregnancy is advised by some authors to make vaginal examinations easier, to have healed genitalia with a physiological vaginal orifice and avoid excessive bleeding and possible complications at delivery, especially when a less experienced team is involved. Also advised is separation of the timing of the body change linked to defibulation from the timing of delivery, to give the woman a breathing space to accustom herself to the anatomical and physiological changes in her genitalia, avoiding the request for re-infibulation after delivery [33, 34]. Other studies advise intra-partum defibulation to avoid anaesthesia or surgery during pregnancy, as there are no statistically significant differences in the duration of labour, rates of episiotomy and vaginal lacerations, APGAR scores, blood loss and duration of stay in hospital between women who needed intra-partum defibulation and women without FGM/C [25, 35], and most women seem to prefer the option of defibulation

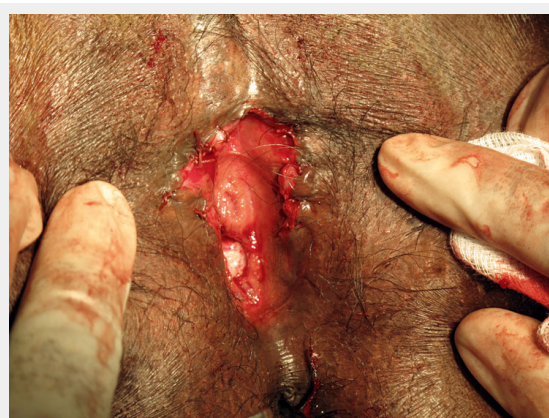

Figure 3

Partial defibulation in FGM/C type IIIb. Photo courtesy of Reference Centre for Preventing and Curing FGM. Department of Gynaecology, Perinatology and Physiology of Reproduction of Florence, Italy.

during labour [15, 25]. Other studies are necessary to clarify what is the best option in terms of patient satisfaction and outcome.

It sometimes happens that an infibulated woman asks to be “re-closed” after delivery. For this reason it is very important to have discussed this with the woman and her husband before delivery. It must be explained that in Switzerland, as in other European countries, re-infibulation is illegal but that the genital anatomy will be restored in its most physiological form without leaving the vaginal opening “too wide” and thus possibly causing psychosexual distress for the couple and pushing the woman to travel to her country to be re-infibulated [22, 36]. According to the Swiss guidelines requests for restoration of a narrow orifice should not be accepted, emphasising the possible complications and potential health problems [15, 22]. If the patient still asks for re-infibulation despite efforts and explanations, in the exceptional case of partial closure an orifice wide enough must be left to allow physiological urine and menstruation flow, sexual intercourse and gynaecological examinations [22].

The anatomical and physiological change during the postpartum period must be explained to the patients. If they agree, perineal re-education with Kegel exercises can be advised [33].

Some patients may consult with a request for clitoral restoration or clitoral repair. As shown by Foldes, women ask for this especially when they think they have lost their female identity and are looking for a “normal appearance” for their genitalia or for “what they have lost” [37]. Identity is often a complicated issue for these patients caught between two cultures. It is important to clarify their request and advise them in detail to avoid false or disproportionate expectations from this operation. It is important, for example, to correct the common false idea of having lost the entire clitoris, and explain that in reality they are referring to the visible (external) part of the clitoris and not to the whole organ, which is strictly connected to the vagina [26]. In addition, a pre-surgery consultation with a psychologist should be systematically offered [37].

Pricking/nicking and proposals for alternative rituals

The prevailing attitude to female genital mutilations/cuttings in Western countries has been characterised by zero tolerance [38]. *Pricking* is a procedure in which the prepuce of the clitoris is pierced without removal of tissue and is included in the WHO classification of 2007 in category IV with other forms such as *piercing*, *scraping* and *incising*, arguing that this term could actually be used to legitimise or cover up more invasive procedures of Type I to III [1, 39]. Nevertheless, in some African regions, *pricking* has replaced more severe forms of mutilation [40], and since the 1990s has been proposed as an alternative ritual or symbolic procedure in some Western medical centres. Four cases have been reported.

In the Netherlands, in 1992, the Ministry of Welfare, Health and Culture suggested that doctors should be allowed to perform *pricking* as a ritual [38]. Better known is the case of Seattle in 1996, where doctors at the *Harborview Medical Center* suggested a symbolic procedure to be performed on Somali girls’ clitoral hood to enable the parents to con-

sider their girls circumcised. They argued that the “medically safe *pricking*” of the clitoris by a physician was preferable to the much more severe mutilations that girls might risk travelling to their home country, and less invasive than male circumcision of male children [38]. The *Harborview Medical Center* in Seattle, Washington, serves a largely immigrant community, including a substantial number of Somali immigrants and refugees. After initial rejection, confronted with the immigrants’ requests for female circumcision, a proposal to perform a ritual or symbolic circumcision was forwarded by the hospital’s review committee, which included a urologist, medical ethicists, paediatricians, an obstetrician-gynaecologist, hospital administrators and a plastic surgeon. The committee discussed the matter with the Somali community and the final compromise was a symbolic *nick* on the prepuce of the clitoris conducted under local anaesthetic. Children should be old enough to understand the procedure and give consent in combination with informed consent of the parents. This proposal caused a public outcry that blocked it [41].

A similar proposal was presented in 2003 at the *Reference Centre for Preventing and Curing FGM of the Department of Gynaecology, Perinatology and Reproduction Physiology* of Florence, Italy, which has been working with FGM/C patients and immigrant communities for many years. It was directed to the families with girls at risk of FGM/C when it appeared evident that educational and information strategies to prevent this practice were ineffective [42]. It was also claimed that it could have been a transitional step before the practice was abandoned in the second generation. The *alternative ritual* was a prick with a small needle (insulin needle) on the skin which covers the clitoris (prepuce) under temporary local anaesthesia by specific anaesthetic cream for children old enough to give their consent [42]. The proposal, as in Seattle, came from the immigrant communities and was presented after studies and discussions involving psychologists, anthropologists, sexologists, gynaecologists, other medical doctors and immigrants. It was submitted to the Law Faculty of Florence and then to the Bioethic Committee and judged ethical, legal, deontological, efficacious and fair [7, 43]. The ritual was then presented as a symbolic alternative accepted by the communities and at the same time legal in the host country. In Florence, as in Seattle and in the Netherlands, major polemics and protests defending zero tolerance against every type of genital manipulation, especially from feminist associations and the media, stopped the introduction of *pricking*.

Similar events were reported recently in the USA, where in April 2010 the *American Academy of Pediatricians (AAP)* claimed that it might be more effective if Federal and State laws enabled paediatricians to reach out to families by offering a *ritual nick* as a possible compromise, suggesting that it would not be physically harmful and much less extensive than newborn male genital cutting. In this policy statement the *AAP* says, as used to be stressed in Seattle and in Florence, that there is reason to believe that offering this compromise may build trust between hospitals and immigrant communities, save girls from undergoing disfiguring and life-threatening procedures in their native countries, and play a role in the eventual eradication of FGM/C

[44]. Protests and reactions started after this statement and discussions are still ongoing.

Conclusions

Any form of female genital mutilation/cutting is a human rights violation that should be abandoned. Every woman has the right to psychophysical and sexual health, and every circumcised woman should also have the right to be examined and treated by a physician or a gynaecologist correctly trained in this subject. These patients often have specific medical, gynaecological, obstetric, and psychophysical problems, associated with their personal experience of circumcision, migration and life. However, as in other European countries, in the five Swiss medical schools FGM/C are not included in the pre-graduate curriculum [45] and recent studies emphasise that there is a lack of knowledge on the subject among gynaecologists: many of whom are not familiar with the classification and management of FGM/C [46]. In addition, considering the possible consequences for overall psychophysical health, a multidisciplinary approach is recommended in collaboration with paediatricians, who can play a central role in prevention [47]. It is necessary to continue studying, educating, increasing awareness and teaching medical professionals to guarantee optimum prevention and care for women with FGM/C.

Funding / potential competing interests

No funding; no competing interests.

References

- 1 Eliminating Female genital mutilation – An interagency statement (OHCHR, UNAIDS, UNDP, UNECA, UNESCO, UNFPA, UNHCR, UNICEF, UNIFEM, WHO), WHO. 2008.
- 2 Female Genital Mutilation/female genital cutting: a statistical report. New York, UNICEF. 2005.
- 3 World Health Organization. Management of pregnancy, childbirth and the postpartum period in the presence of female genital mutilation. Report of a WHO technical consultation. Geneva: October 15–17, 1997. Department of Gender, Women and Health. Department of Reproductive Health and Research Family and Community Health World Health Organization. 2001.
- 4 Thierfelder C, Tanner M, Bodiang CM. Female genital mutilation in the context of migration: experience of African women with the Swiss health care system. *Eur J Public Health*. February 2005.
- 5 Grassi Gallo P, Viviani. Alle radici delle Modificazioni Etniche dei Genitali Femminili. In: *Corpi e simboli. Immigrazione sessualità e mutilazioni genitali femminili in Europa*. a cura di Morrone A., Vulpiani P. Armando Editore Press. 2005.
- 6 Pasquinelli C. *Infibulazione. Il corpo violato* Meltemi Editore, Roma. 2007.
- 7 Catania L, Abdulcadir OH. Ferite per sempre. Le mutilazioni genitali femminili e la proposta del rito simbolico alternativo. *Derive e Appropi*. Roma 2005.
- 8 Gruenbaum E. Socio-cultural dynamics of female genital cutting: Research findings, gaps, and directions. *Cult Health Sex*. 2005.
- 9 Ahmadu F. Rites and wrongs: An insider/outsider reflects on power and excision. In: *Shell-Duncan B, Herlund Y, eds. Female circumcision in Africa: Culture, controversy, and change*. London: Lynne Rienner Publishers. 2000.
- 10 Catania L. Female Circumcision and the Orgasm Puzzle. [Personal Presentation]. 11th Annual Meeting American Anthropological Association. San Francisco. California, 19th–23rd November 2008.
- 11 Moscardi S. Diritto Penale e Multiculturalismo. Il divieto delle pratiche di mutilazione degli organi genitali femminili. Tesi di Laurea in Diritto Penale. Facoltà di Giurisprudenza. Università degli Studi di Firenze. AA 2008–09.
- 12 Botti Federica, *Manipolazioni del corpo e mutilazioni genitali femminili*, Bologna, Bonomia University Press, 2009.
- 13 Krása K. Human rights for women: the ethical and legal discussion about Female Genital Mutilation in Germany in comparison with other Western European countries. *Med Health Care Philos*. April 2010.
- 14 Rapport de la Commission des affaires juridiques du Conseil national. Initiative parlementaire. Réprimer explicitement les mutilations sexuelles commises en Suisse et commises à l'étranger par quiconque se trouve en Suisse. Avril 2010.
- 15 Hohlfeld P, Thierfelder C, Jäger F (pour le groupe de travail MGF). Mutilations génitales féminines. Recommandations suisses à l'intention des professionnels de la santé. *Schweizerische Ärztezeitung / Bulletin des médecins suisses / Bollettino dei medici svizzeri* Nr 16. 2005.
- 16 Trechsel S, Schlauri R. Les mutilations génitales féminines en Suisse, expertise juridique commandée par UNICEF. Zurich: Comité Suisse pour l'Unicef. 2004.
- 17 Niggli MA, Berkemeier A. La question de la punissabilité de la mutilation génitale féminine des types I et IV, expertise juri-dique commandée par UNICEF. Zurich: Comité Suisse pour l'Unicef. 2007.
- 18 Code Pénal Suisse. http://www.admin.ch/ch/fr/rs/311_0/index3.html
- 19 http://sprechzimmer.ch/sprechzimmer/Frauen/Genitalverstummelungen_Erstes_Urteil_in_der_Schweiz.php
- 20 www.nzz.ch/nachrichten/zueroch/eltermpaar_wegen_beschneidung_seiner_tochter_verurteilt_1.769848.html
- 21 Poldermans S. Combating Female Genital Mutilation in Europe, A Comparative Analysis of Legislative and Preventative Tools in the Netherlands, France, the United Kingdom, and Austria. Master of Law European Master's Degree in Human Rights and Democratization Academic year 2005/2006 <http://www.stopfgm.net/dox/SPoldermansFGMinEurope.pdf>
- 22 Abdulcadir J, Orlando V. La promozione della salute delle donne con mutilazioni. *Io Uomo*. Dicembre 2009.
- 23 Rouzi AA. Epidermal clitoral inclusion cysts: not a rare complication of female genital mutilation. *Hum Reprod*. 2010.
- 24 WHO study group on female genital mutilation and obstetric outcome, Banks E, Meirik O, Farley T, Akande O, Bathija H, Ali M. Female genital mutilation and obstetric outcome: WHO collaborative prospective study in six African countries. *Lancet*. 2006 Jun.
- 25 Wuest S, Raio L, Wyssmueller D, Mueller MD, Stadlmayr W, Surbek DV, Kuhn A. Effects of female genital mutilation on birth outcomes in Switzerland. *BJOG*. 2009.
- 26 Catania L, Abdulcadir OH, Puppo V, Baldaro Verde J, Abdulcadir J, Abdulcadir D. Pleasure and Orgasm in Women with Female Genital Mutilation/Cutting (FGM/C) *J Sex Med*. 2007.
- 27 Johnsdotter S, Essen B. Sexual health among young Somali women in Sweden: Living with conflicting culturally determined sexual ideologies. Paper presented at International Network to Analyze, Communicate and Transform the Campaign against Female Genital Cutting, Female Genital Mutilation, Female Circumcision (INTACT) Conference on Advancing Knowledge on Psycho-sexual effects of FGM/C: Assessing the Evidence. Alexandria, Egypt, October 10–12. 2004.
- 28 Nour NM, Michels KB, Bryant AE. Defibulation to treat female genital cutting: effect on symptoms and sexual function. *Obstet Gynecol*. 2006.
- 29 Adam T, Bathija H, David Bishai, Bonnenfant Y, Darwish M, Huntington D, Johansen E for the FGM Cost Study Group of the World Health Organization. Estimating the obstetric costs of female genital mutilation in six African countries. *Bulletin of the World Health Organization*. Volume 88, Number 4. April 2010.
- 30 Abdulcadir OH, Catania L. La Deinfibulazione. *Toscana Medica*, n. 1 Gennaio 2006.
- 31 Abdulcadir OH, Catania L. Deinfibulazione terapeutica. *Il Ginecologo Rivista di Ostetricia e Ginecologia* Vol.1, n. 2, Giugno 2006.

- 32 Johnson C, Nour NM. Surgical techniques: defibulation of Type III female genital cutting. *J Sex Med.* 2007.
- 33 Catania L. Defibulation: A practice to improve the quality of infibulated women's life. Female and male genital surgeries: Critical intersections/astonishing issues. In: Abstract Book of the 10th Annual Meeting American Anthropological Association. Critical Intersections/Dangerous Issues, San Jose, California. American Anthropological Association: Arlington, VA; November 15–19 2006.
- 34 Sirigatti S, Catania L, Simone S, Casale S, Abdulcadir OH. Preliminary research into the psychosexual aspects of the operation of defibulation. In: Denniston GC, Grassivaro Gallo P, Hodges FM, Milos MF, Viviani F, eds. *Bodily integrity and politics of circumcision.* New York, NY: Springer; 2006.
- 35 Rouzi AA, Aljhadali EA, Amarin ZO, Abduljabbar HS. The use of in-trapartum defibulation in women with female genital mutilation. *BJOG.* 2001.
- 36 Adams KE. What's "normal": Female Genital Mutilation, Psychology, and Body Image. *Journal of the American Medical Women's Association.* 2004.
- 37 Foldes P, Louis-Sylvestre C. Results of Surgical Clitoral Repair after Ritual Excision: 453 cases. *Gynecol Obstet Fertil.* 2006.
- 38 Johnsdotter S, Essen B. Genitals and ethnicity: the politics of genital modifications. *Reprod Health Matters.* May 2010.
- 39 Female Genital Cutting in Somalia. Reasons for continuation and strategies for eradication. Hergeisa, Somalia, WHO. 2002.
- 40 Budiharsana M. Female circumcision in Indonesia: extent, implications and possible interventions to uphold women's health rights. Jakarta. Population Council 2004.
- 41 Lambelet Coleman D. The Seattle Compromise: Multicultural Sensitivity and Americanization. *Duke Law Journal,* 1998.
- 42 Catania L, Abdulcadir OH. Si può proporre un rito alternativo, eticamente e legalmente accettabile, in una strategia di lotta efficace contro le MGF?. *Toscana Medica* n. 10. Nov–Dic 2003.
- 43 Commissione Regionale di Bioetica. Toscana. Prevenzione delle Mutilazioni Genitali Femminili (MGF): Liceità etica, deontologica e giuridica della partecipazione dei medici alla pratica di un rito alternativo. 9 Marzo 2004 http://www.regione.toscana.it/regione/multimedia/RT/documents/2009/11/04/649e0be56f02089f0922d47484723373_mgf.pdf
- 44 Policy Statement. Ritual Genital Cutting of Female Minors. COMMITTEE ON BIOETHICS. Paediatrics published online Apr 26, 2010.
- 45 Jaeger F, Schulze S, Hohlfeld P. Female genital mutilation in Switzerland: a survey among gynaecologists. *Swiss Med Wkly.* 2002.
- 46 Leye E, Ysebaert I, Deblonde J, Claeys P, Vermeulen G, Jacquemyn Y, Temmerman M. Female genital mutilation: knowledge, attitudes and practices of Flemish gynaecologists. 2008.
- 47 Jaeger F, Caflisch M, Hohlfeld P. Female genital mutilation and its prevention: a challenge for paediatricians. *Eur J Pediatr.* 2009.