

Diagnostic yield of flexible bronchoscopy in current clinical practice

Ladina Joos, Nicola Patuto, Prashant N. Chhajed, Michael Tamm

Pulmonary Medicine, Department of Internal Medicine, University Hospital, Basel, Switzerland

Summary

Background: Flexible bronchoscopy is a procedure commonly performed for diagnostic and therapeutic purposes. The aim of this study was to assess the diagnostic yield and the safety of routine bronchoscopy techniques including transbronchial needle aspiration and transbronchial biopsy at a university hospital in Switzerland.

Methods: 616 consecutive bronchoscopies performed at the Pulmonary Medicine Department (University Hospital Basel) over a period of 6 months were analysed retrospectively using bronchoscopy reports and hospital charts. Diagnostic procedures included bronchial washings, bronchoalveolar lavage, bronchial brushings, transbronchial needle aspiration and transbronchial biopsies.

Results: 430 bronchoscopies had a diagnostic,

186 a therapeutic indication. The overall diagnostic yield was 57% (245/430). Bronchoscopy performed for suspected tumours confirmed malignancy in 43% of cases. Bronchoscopy in suspected infection and tuberculosis identified pathogenic organisms in 46% and 27% of cases, respectively. The diagnostic yield for central and peripheral TBNA was 37.8 and 43.6%, respectively. Complications were very rare (n = 10, 1.6%) and were only minor.

Conclusion: This study demonstrates that routine bronchoscopy techniques including transbronchial needle aspiration and transbronchial biopsy are safe and have a high diagnostic yield.

Key words: bronchoscopy; TBNA diagnostic yield

Introduction

Flexible bronchoscopy is a minimally invasive procedure, which is commonly performed in clinical respiratory practice for various indications. The diagnostic yield of bronchoscopy is regarded high, however it varies considerably depending on indication and techniques used during bronchoscopy [1–4]. The last decades have seen introduction of several diagnostic innovations in the bronchoscopy suite which include endobronchial ultrasound, autofluorescence bronchoscopy and electromagnetic navigation [5, 6]. These modalities have been introduced with the aim to increase the diagnostic yield of bronchoscopy. However, such innovations are mainly limited to specialised centres and do not reflect the application of this technique in routine clinical practice. Trans-

bronchial needle aspiration (TBNA) has commonly been referred to as an advanced or interventional bronchoscopy procedure [7]. In recent years TBNA has been used as a routine in our bronchoscopy suite and all residents are trained in this technique [8]. We believe that despite various recent innovations, the diagnostic yield of routine bronchoscopy techniques presently is high and centres without facilities for advanced bronchoscopy techniques should continue to optimally use the current routine armamentarium. We therefore performed this study to assess the diagnostic yield of routine bronchoscopy techniques including transbronchial needle aspiration and transbronchial biopsy in the “current clinical practice”.

Patients and methods

We evaluated retrospectively all 616 consecutive flexible bronchoscopies performed in our bronchoscopy suite over a period of six months. Patients included outpatients as well as inpatients from different departments of the hospital. We evaluated 4 different aspects in each patient: indication, diagnosis obtained by bronchoscopy, final diagnosis and bronchoscopy-related complications. The final diagnosis was obtained from hospital or outpatient charts.

Flexible bronchoscopy was performed using a standard flexible bronchoscope (Pentax Precision Instrument Corp; Orangeburg, NY; or Olympus America Inc; Melville, NY) under local anaesthesia and combined sedation using midazolam and hydrocodone (5 mg) [9, 10]. Midazolam was administered in incremental boluses of 1 or 2 mg. All patients received oxygen supplementation at 2 to 4 litres per minute. Oxygen desaturation to less than 90% was treated with increase in oxygen to 6 litres per minute, jaw support and/or nasopharyngeal tube insertion. During the procedure, diagnostic material was obtained by bronchial washings, broncho-alveolar lavage (BAL), transbronchial needle aspiration (TBNA; lymph nodes or lung), bronchial brushings, endobronchial biopsy or transbronchial biopsy, as decided by the bronchoscopist on a case-by-case basis. Bronchial secretions or washings were obtained commonly during most procedures by instilling 10 ml or more of sterile isotonic NaCl solution into the bronchus of interest followed by immediate aspiration into a trap. Specimens were sent to the laboratory for bacterial, fungal or viral culture, and for cytological analysis. For bronchoalveolar lavage, 3 × 50 ml of pyrogen-free-sterile 0.9% NaCl solution was instilled into the middle lobe or lingula in patients with diffuse disease and in patients with heterogeneous disease into the segment with the most prominent radiological infiltrate. BAL fluid was recovered by suction or gravity. 10 ml of BAL fluid were sent for bacterial, mycobacterial, and fungal culture and 5–10 ml for virus culture. The rest was sent for cytology analysis. Mouth flora and *Candida* grown from BAL were not regarded as relevant pathogens and therefore not included in the analysis.

TBNA was performed using MW 522 needle catheters (Mill-Rose Laboratories; Mentor, OH). The retractable 22-gauge needle with a length of 13 mm lies within a catheter of 1.8 mm outer diameter with a rounded hub at its distal end. The needle is connected to a wire with a flexible, 10-cm-long portion at its distal end [11]. Dur-

ing bronchoscopy, the catheter is guided under fluoroscopic control if peripheral lesions are sampled. After the needle is advanced into the tissue, suction is applied with a 20-ml syringe via a side port at the proximal end of the catheter. Once the sample is collected, the needle is flushed with 2 ml of 0.9% saline into a test tube. A histological specimen was obtained from lymph nodes with a similar 19-gauge needle.

Transbronchial biopsy was performed under fluoroscopic guidance. The bronchoscope was wedged in the desired segment and maintained in that position throughout the biopsy. The biopsy forceps was then passed through the suction channel and extended to the lung periphery. As the patient exhaled, the forceps was advanced 1 to 2 cm in an open position, closed, and then removed from the bronchoscope to obtain the specimen. This procedure was repeated three to five times to obtain adequate samples. Post-bronchoscopy chest x-ray was performed routinely 4 hours after TBB.

Bronchial secretion samples were centrifuged at 1500 rpm for 5 min, the supernatant was poured off, and the sediment of material was pipetted on several slides and fixed with 95% alcohol. Centrifuged BAL preparations were routinely stained with Giemsa and special stains (eg, silver methenamine for detection of fungi or *Pneumocystis carinii*). Lavage cell smears and Millipore filter preparations were obtained to gain further information about *P. carinii* infection or viral inclusions. Immunofluorescence or immunocytochemical methods were performed for the analysis of cell subgroups where appropriate [12]. Transbronchial needle aspirates and brushings were collected in a test tube in 0.9% normal saline and a few drops of 95% alcohol were added to the sample. Forceps biopsy specimens were fixed in formaldehyde solution, embedded in paraffin, and sectioned. Cytological specimens were stained routinely by the Papanicolaou technique and histological specimens were stained with haematoxylin and eosin. All the specimens were interpreted by a cytopathologist. Rapid onsite pathology was not available.

Complications were categorised as minor or major according to the BTS guidelines [10].

Data were collected retrospectively using bronchoscopy reports and corresponding hospital or outpatient charts and entered into Excel spread sheets (Microsoft® Excel 97). Calculations and graphs were done using Excel.

Results

The mean age of the 616 patients was 59 years (± 15 y, range 17–94 y) and 63.5% of patients were male. Seventy-six patients (17.8%) were immunocompromised. Of the 616 bronchoscopies performed, 186 (30.2%) were for therapeutic and 430 (69.8%) for diagnostic indications. Therapeutic bronchoscopies, which consisted mainly of bronchial cleaning (48%) and palliative measures (40%), were not included in the analysis of diagnostic yield. Diagnostic indication categories are summarised in table 1. Most of the diagnostic bronchoscopies were performed for suspected malignancy (45%) and suspected infection (27%).

In addition to bronchial secretions and endobronchial biopsies, a total of 234 BAL, 139 TBNA

(100 central, 39 peripheral aspirates), 12 mediastinal core biopsies and 58 TBB were performed in both diagnostic and therapeutic indication groups. For the diagnostic indication group, a total of 217 BAL, 137 TBNA (98 central, 39 peripheral aspirates), 12 mediastinal core biopsies and 56 TBB were performed. Of the 98 central TBNA, 37 were diagnostic, whereas 17 of 39 peripheral TBNA lead to a diagnosis (diagnostic yield of 37.8 and 43.6%, respectively). Four of the 12 mediastinal core biopsies delivered the correct diagnosis (2 lymphoma, renal cell carcinoma, NSCLC).

Malignancy was found in 83 cases (43.2%) of 192 bronchoscopies in patients with suspected carcinoma. Concomitant infection occurred in 8

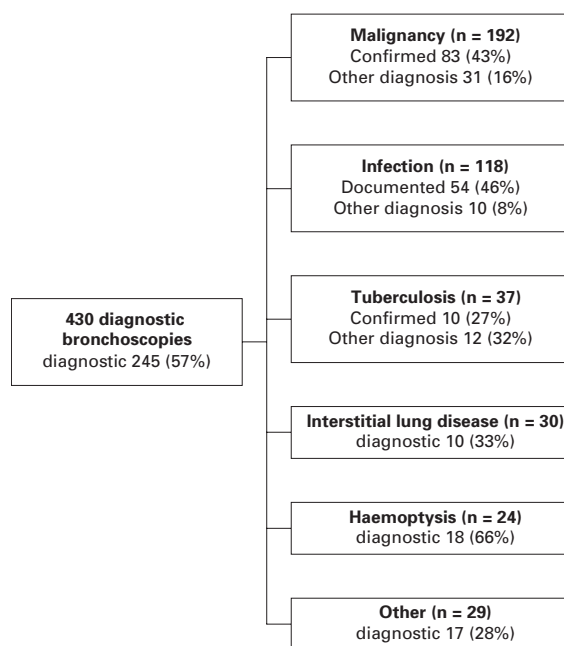
Table 1

Overview of bronchoscopies performed for different indication categories

	Number	% of diagnostic indications	% of all bronchoscopies
Suspected malignancy	192	45.0	31.2
Suspected infection	118	27.6	19.2
Suspected tuberculosis	37	8.4	6.0
Interstitial pulmonary diseases	30	7.0	4.9
Haemoptysis	24	5.6	3.9
Suspected aspiration	12	2.8	1.8
Chronic cough	11	2.5	1.7
Chest trauma	6	1.4	1.0
Total	430	100	69.8

Figure 1

Diagnostic yield of flexible bronchoscopy (FFB) in 430 patients.



cases. Malignancy was correctly excluded in 51 patients (26.6%). In 27 (14.1%) cases, malignancy was missed and found by further investigations. In 31 cases (16.1%), an alternative diagnosis was found, which included infection, interstitial pulmonary disease, aspiration pneumonia, radiation pneumonitis, granulomatous disease and unspecific inflammation. The overall diagnostic yield of

flexible bronchoscopy for detection of proven malignancy was 75.5%. In macroscopically visible malignancy, the diagnostic yield increased to 92.1%.

We performed 118 bronchoscopies for suspected infections, and 76 (64%) of these patients were immunocompromised. We found pathogenic organisms in 50% of cases. Overall, we found pathogenic microorganisms in 150 of a total of 616 bronchoscopies (24.3%). A wide variety of microorganisms were documented. Of a total of 129 bronchoscopies performed in 76 immunocompromised patients, 47 (36.4%) were positive for infectious pathogens. These included bacteria (n = 24), cytomegalovirus (n = 14), other viruses (n = 2), *Pneumocystis jirovecii* (n = 2) and *aspergillus* (n = 5).

M. tuberculosis was found in 10 of 37 patients with suspected tuberculosis. Its detection by bronchoscopy failed in 2 cases. Other bacteria were found in 13, and an alternative diagnosis in 3 patients.

There were no major complications during the study period. Minor complications included laryngo- and bronchospasm (n = 2), minor pneumothorax (n = 1), nausea and vomiting (n = 1), self-limiting arrhythmia (n = 1), and paradox reaction on midazolam (n = 1). There was no relevant bleeding after TBNA during the study period.

A summary of the diagnostic yield is given in figure 1.

Discussion

In this retrospective analysis of 616 consecutive bronchoscopies performed at a tertiary care centre in Switzerland over a period of 6 months, we found a high overall diagnostic yield of 57% (245/430). The diagnostic yield of bronchoscopy for detection of malignancy was 75.5%. These results are comparable with a recent systematic review, where the diagnosis of endobronchial disease by bronchoscopy in 30 studies showed the highest yield for endobronchial biopsy (74%), followed by cytobushing (59%) and washing (48%) [13]. The diagnostic yield in our study was highest in cases with a macroscopically visible tumour (92%), com-

parable to the data of Popovich et al. [14]. A previous study in our centre demonstrated a diagnostic yield of 51% for peripheral lesions [15], and in a very recent study, a combination of routine bronchoscopy methods including TBNA revealed a diagnostic yield of 50% even in small radiological lesions less than or equal to three centimetres [16]. The findings of the present study confirm our belief that the diagnostic yield of routine bronchoscopy techniques is high, particularly in lung cancer patients and hence they should be continued to be optimally applied in patient management.

Pathogenic microorganisms were present in 24.3% of all bronchoscopies. Of a total of 129 bronchoscopies performed in 76 immunocompromised patients, 47 (36.4%) were positive for infectious pathogens. Thirty-seven bronchoscopies were performed in patients with suspected tuberculosis. *M. tuberculosis* was found in 10 cases by smear and/or positive culture, however, its detection failed in 2 cases, resulting in a sensitivity of 83%. This is a satisfactory result considering the fact that patients were preselected due to their inability to deliver sputum or due to previously negative sputum samples. The sensitivity is comparable to a recent prospective study [17]. Furthermore, infectious pathogens other than mycobacteria were detected in a high percentage of patients. These findings suggest that bronchoscopy has an important value for diagnosis and exclusion of pulmonary infections.

In patients with suspected interstitial lung diseases, a specific diagnosis was obtained in a third of cases. Diagnoses included sarcoidosis ($n = 7$), extrinsic allergic alveolitis ($n = 2$), and eosinophilic pneumonia ($n = 1$). In these patients, more invasive diagnostic procedures such as thoracoscopic or open lung biopsies could be avoided and therefore, limiting the costs and morbidity. However, these data also confirm the limitation of TBB for the differential diagnosis of interstitial lung disease [4].

The overall yield of TBNA for lymph node sampling and peripheral lesions was 40%. This diagnostic yield might come across as low compared to other studies. We believe that the relatively low yield of TBNA is due to its routine use including patients who might have a low probability for disease. This belief is supported by a recent meta-analysis on TBNA which concluded that sensitivity of TBNA depends to a large extent on the study methods and patient population [18]. In populations with a lower prevalence of mediastinal metastasis, the sensitivity of TBNA is much lower than reported in recent lung cancer guidelines [18]. There were no complications attributed to TBNA

in this study. Our experience and data support that TBNA should be categorised as a routine diagnostic tool and should be optimally used to enhance patient management.

The assessment of the safety of flexible bronchoscopy was a further aim of our study. Overall, bronchoscopy-related complications were rare ($n = 10$, 1.6%) and included only minor, non-life-threatening complications. There was no case of major life-threatening complication in this patient cohort. In a large retrospective study, minor complication rates amounted to 0.8%, and major life-threatening complication rates to 0.5% [19]. The difference in minor complications could be attributed to some cases of mild desaturation, which are not regarded as complications by some authors. However, the number of complications may also be underestimated due to underreporting of minor complications in inpatients after their transfer to hospital wards. We recently analysed the benefit and safety of sedatives and local anaesthesia in large prospective studies. Our data provide evidence that the combination of midazolam and hydrocodone markedly reduces cough during bronchoscopy without causing relevant hypoxia [9], while the addition of nebulized lidocaine does not provide an additional benefit [20].

To summarise, routine flexible bronchoscopy techniques continue to be safe procedures even with the inclusion of TBNA and TBB and have a high diagnostic yield in current clinical practice. TBNA is a safe procedure and should be adopted for routine use in the bronchoscopy suite.

Correspondence:

Ladina Joos, MD

*Pulmonary Medicine and Pulmonary
Cell Research*

University Hospital Basel

Petersgraben 4

CH-4031 Basel

Switzerland

E-Mail: ljoos@uhbs.ch

References

- Mak VH, Johnston ID, Hetzel MR, Grubb C. Value of washings and brushings at fiberoptic bronchoscopy in the diagnosis of lung cancer. *Thorax* 1990;45:373–6.
- Gellert AR, Rudd RM, Sinha G, Geddes DM. Fiberoptic bronchoscopy: effect of multiple bronchial biopsies on diagnostic yield in bronchial carcinoma. *Thorax* 1982;37:684–7.
- Descombes E, Gardiol D, Leuenberger P. Transbronchial lung biopsy: an analysis of 530 cases with reference to the number of samples. *Monaldi Arch Chest Dis* 1997;52:324–9.
- The diagnosis, assessment and treatment of diffuse parenchymal lung disease in adults. *Thorax* 1999;54 Suppl 1:S1–14.
- Yasufuku K, Chiyo M, Sekine Y, Chhajed PN, Shibuya K, Iizasa T, et al. Real-time endobronchial ultrasound-guided transbronchial needle aspiration of mediastinal and hilar lymph nodes. *Chest* 2004;126:122–8.
- Chhajed PN, Lee P, Tamm M. Advances in bronchoscopy – new and upcoming bronchoscopic methods at the dawn of the 21st century. *J Assoc Physicians India* 2004;52:970–4.
- Bolliger CT, Mathur PN, Beamis JF, Becker HD, Cavaliere S, Colt H, et al. ERS/ATS statement on interventional pulmonology. *European Respiratory Society/American Thoracic Society. Eur Respir J* 2002;19:356–73.
- Chhajed PN, Bernasconi M, Gambazzi F, Bubendorf L, Rasch H, Kneifel S, et al. Combining bronchoscopy and PET for the diagnosis of the small pulmonary nodule. *Chest* 2005; in Press.
- Stolz D, Chhajed PN, Leuppi JD, Brutsche M, Pflimlin E, Tamm M. Cough suppression during flexible bronchoscopy using combined sedation with midazolam and hydrocodone: a randomised, double blind, placebo controlled trial. *Thorax* 2004;59:773–6.
- British Thoracic Society guidelines on diagnostic flexible bronchoscopy. *Thorax* 2001;56(Suppl 1):i1–21.

- 11 Salathe M, Soler M, Bolliger CT, Dalquen P, Perruchoud AP. Transbronchial needle aspiration in routine fiberoptic bronchoscopy. *Respiration* 1992;59:5-8.
- 12 Chhajed PN, Tamm M, Glanville AR. Role of flexible bronchoscopy in lung transplantation. *Semin Respir Crit Care Med* 2004;25:413-23.
- 13 Schreiber G, McCrory DC. Performance characteristics of different modalities for diagnosis of suspected lung cancer: summary of published evidence. *Chest* 2003;123:115S-28S.
- 14 Popovich J Jr, Kvale PA, Eichenhorn MS, Radke JR, Ohorodnik JM, Fine G. Diagnostic accuracy of multiple biopsies from flexible fiberoptic bronchoscopy. A comparison of central versus peripheral carcinoma. *Am Rev Respir Dis* 1982;125:521-3.
- 15 Reichenberger F, Weber J, Tamm M, Bolliger CT, Dalquen P, Perruchoud AP, et al. The value of transbronchial needle aspiration in the diagnosis of peripheral pulmonary lesions. *Chest* 1999;116:704-8.
- 16 Chhajed PN, Bernasconi M, Gambazzi F, Bubendorf L, Rasch H, Kneifel S, et al. Combining bronchoscopy and positron emission tomography for the diagnosis of the small pulmonary nodule < or = 3 cm. *Chest* 2005;128:3558-64.
- 17 Conde MB, Soares SL, Mello FC, Rezende VM, Almeida LL, Reingold AL, et al. Comparison of sputum induction with fiberoptic bronchoscopy in the diagnosis of tuberculosis: experience at an acquired immune deficiency syndrome reference center in Rio de Janeiro, Brazil. *Am J Respir Crit Care Med* 2000;162:2238-40.
- 18 Holty JE, Kuschner WG, Gould MK. Accuracy of transbronchial needle aspiration for mediastinal staging of non-small cell lung cancer: a meta-analysis. *Thorax* 2005.
- 19 Pue CA, Pacht ER. Complications of fiberoptic bronchoscopy at a university hospital. *Chest* 1995;107:430-2.
- 20 Stolz D, Chhajed PN, Leuppi J, Pflimlin E, Tamm M. Nebulized lidocaine for flexible bronchoscopy: a randomized, double-blind, placebo-controlled trial. *Chest* 2005;128:1756-60.

The many reasons why you should choose SMW to publish your research

What Swiss Medical Weekly has to offer:

- SMW's impact factor has been steadily rising, to the current 1.537
- Open access to the publication via the Internet, therefore wide audience and impact
- Rapid listing in Medline
- LinkOut-button from PubMed with link to the full text website <http://www.smw.ch> (direct link from each SMW record in PubMed)
- No-nonsense submission – you submit a single copy of your manuscript by e-mail attachment
- Peer review based on a broad spectrum of international academic referees
- Assistance of our professional statistician for every article with statistical analyses
- Fast peer review, by e-mail exchange with the referees
- Prompt decisions based on weekly conferences of the Editorial Board
- Prompt notification on the status of your manuscript by e-mail
- Professional English copy editing
- No page charges and attractive colour offprints at no extra cost

Editorial Board

Prof. Jean-Michel Dayer, Geneva
 Prof. Peter Gehr, Berne
 Prof. André P. Perruchoud, Basel
 Prof. Andreas Schaffner, Zurich
 (Editor in chief)
 Prof. Werner Straub, Berne
 Prof. Ludwig von Segesser, Lausanne

International Advisory Committee

Prof. K. E. Juhani Airaksinen, Turku, Finland
 Prof. Anthony Bayes de Luna, Barcelona, Spain
 Prof. Hubert E. Blum, Freiburg, Germany
 Prof. Walter E. Haefeli, Heidelberg, Germany
 Prof. Nino Kuenzli, Los Angeles, USA
 Prof. René Lutter, Amsterdam, The Netherlands
 Prof. Claude Martin, Marseille, France
 Prof. Josef Patsch, Innsbruck, Austria
 Prof. Luigi Tavazzi, Pavia, Italy

We evaluate manuscripts of broad clinical interest from all specialities, including experimental medicine and clinical investigation.

We look forward to receiving your paper!

Guidelines for authors:

http://www.smw.ch/set_authors.html

Impact factor Swiss Medical Weekly



All manuscripts should be sent in electronic form, to:

EMH Swiss Medical Publishers Ltd.
 SMW Editorial Secretariat
 Farnsburgerstrasse 8
 CH-4132 Muttenz

Manuscripts: submission@smw.ch
 Letters to the editor: letters@smw.ch
 Editorial Board: red@smw.ch
 Internet: <http://www.smw.ch>