

Hepatopulmonary syndrome and portopulmonary hypertension

Robert Naeije

Erasmus University Hospital, Brussels, Belgium

Summary

Liver disease affects the lungs. The majority of patients exhibit mild to moderate arterial hypoxaemia essentially attributable to an alteration in ventilation/perfusion matching and limited by an increase in ventilation. A minority (some 10%) of patients exhibit a "hepatopulmonary syndrome" defined by severe hypoxaemia with arterial PO_2 below 60 mm Hg, dyspnoea, cyanosis, digital clubbing, orthodeoxia, platypnoea and demonstrable pulmonary vascular dilatations causing a true pulmonary shunt and a diffusion/perfusion imbalance. The hepatopulmonary syndrome is incurable but resolves over time after liver transplantation. An even lower proportion of patients, approximately 1%, develop pulmonary hypertension. Clinically this "portopulmonary hyperten-

sion" resembles primary pulmonary hypertension, with dyspnoea and fatigue as the main symptoms, histopathology and response to prostacyclin therapy. Portopulmonary hypertension is irreversible. Liver transplantation mortality in patients with portopulmonary hypertension ranges from 50 to 100%. The common cause of the hepatopulmonary syndrome and portopulmonary hypertension is portal hypertension and portosystemic shunting, indicating that vasoactive and angiogenic factors originating from the liver normally control the pulmonary circulation.

Key words: liver cirrhosis; portal hypertension; hypoxaemia; pulmonary hypertension; hepatopulmonary syndrome

Introduction

Liver disease affects the lungs. The most common pulmonary consequence of liver disease is altered gas exchange resulting in hypoxaemia. This has been termed the "hepatopulmonary syndrome". Liver disease is sometimes associated with an abnormal increase in pulmonary vascular resistance (PVR), resulting in pulmonary hyperten-

sion. This has been named "portopulmonary hypertension". The common determinant of the hepatopulmonary syndrome and portopulmonary hypertension is portal hypertension and portosystemic shunting. Most cases of portal hypertension develop as a consequence of liver cirrhosis.

Hypoxaemia of liver cirrhosis: importance of the problem

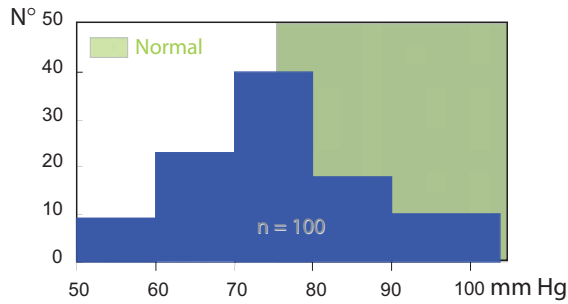
To evaluate the frequency and importance of altered pulmonary gas exchange in severe liver disease, we reviewed blood gases and pulmonary haemodynamics in 100 consecutive patients with proven liver cirrhosis and no cardiac or pulmonary disease, who had been referred to our laboratory for hepatic vein catheterisation, transvenous liver biopsy or haemodynamic evaluation prior to surgery [1]. The majority have been previously reported upon in studies on drug treatment of portal hypertension [2-4] or hypoxic pulmonary vasoconstriction [5]. Seventy-one of the patients were men and 29 women. The mean age was 53

years (range 33-79). Eighty-seven of the patients were alcoholics and 12 had hepatitis. Chest x-rays and electrocardiograms were unremarkable. The diagnosis of liver cirrhosis rested on history, physical examination, liver function tests and liver biopsy in all patients.

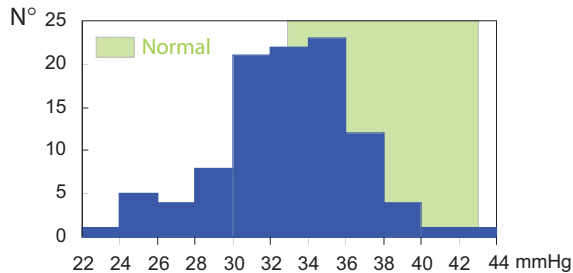
The distributions of arterial PO_2 (PaO_2) and arterial PCO_2 ($PaCO_2$) are shown in Figures 1 and 2. It is apparent that about half of the patients had lower than normal PaO_2 and $PaCO_2$. Accordingly, there was an increase in alveolar to arterial PO_2 gradient ($AaPO_2$) amounting to 34 ± 1 mm Hg (mean \pm SE), compared with 14 ± 1 mm Hg in 32

Figure 1

Distribution of arterial PO_2 values in 100 consecutive patients with liver cirrhosis. Shaded area: limits of normal. From [1].

**Figure 2**

Distribution of arterial PCO_2 values in 100 consecutive patients with liver cirrhosis. Shaded area: limits of normal. From [1].



healthy young adult controls. It is worth noting that in this large series of unselected patients with liver cirrhosis the alteration in gas exchange appeared on the whole fairly moderate, with only 10% of patients presenting PaO_2 lower than 60 mm Hg likely to be associated with clinically detectable cyanosis. The patients' calculated arterial and mixed venous oxygen saturations (SaO_2 and SvO_2) were on average 95.6% and 73.1% respectively, compared with measured 96.7% and 72.4% respectively in normal controls at the same normal PaO_2 and PvO_2 , indicating a slight rightwards displacement of the oxyhaemoglobin dissociation curve. There was no correlation between PaO_2 and clinical signs of liver disease, including spider naevi, or standard liver function tests including serum bilirubin, albumin and ammonia, or the hepatic venous pressure gradient as a measure of portal pressure. Arterial PCO_2 correlated directly with serum albumin and inversely with portal pressure, but did not correlate with other standard liver function tests.

Mechanisms of hypoxaemia of liver cirrhosis

The frequent occurrence of decreased arterial oxygenation in patients with liver disease long ago intrigued clinicians. In 1935 Snell reported on a series of 35 patients with either diseases of the liver parenchyma or biliary tract obstruction, in whom arterial oxygen saturations (SaO_2) were with few exceptions lower than 94%, and suggested this could be explained by decreased affinity of haemoglobin for O_2 [6]. Although conflicting data have been reported [7, 8], a rightward shift of the O_2 -haemoglobin dissociation curve has indeed been shown to occur in liver cirrhosis [9–11], and this was also apparent in our own series of 100 patients [1]. The rightwards displacement of the O_2 -haemoglobin dissociation curve in liver cirrhosis has been shown to be related to an increase in red cell 2–3 diphosphoglycerate [12]. While Snell thought of hypoxaemia as decreased arterial O_2 saturation [6], it may be noted that a decreased affinity of haemoglobin for O_2 results in diminished mixed venous blood O_2 content, which in turn is an extrapulmonary cause of reduced PaO_2 .

Possible causes of arterial hypoxaemia are hypoventilation, abnormal diffusion, altered ventilation/perfusion (VA/Q) relationships and a true shunt ($\text{VA}/\text{Q} = 0$). Hypoventilation is excluded, since increased ventilation and respiratory alkalosis are constant findings in advanced liver disease [7, 8, 13–15]. Normal oxygen diffusion capacity has been reported in several studies [7, 14, 16]. A diffusion defect has repeatedly been ruled out by normally reduced AaPO_2 gradients with low O_2 breathing [5, 8, 14, 16, 17]. A true shunt varying between 6 and 22%, depending on patient selection and methodology, has been measured under

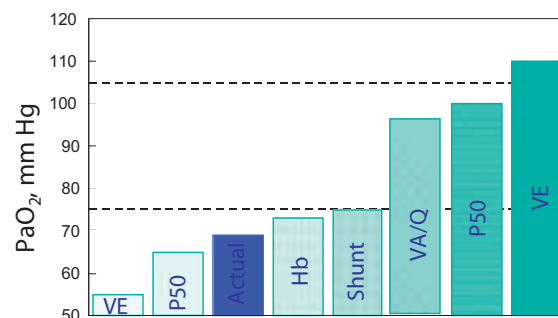
pure O_2 breathing [15–19]. However, more precise measurements using radioactive inert gases of low solubility such as krypton⁸⁵ (Kr^{85}) and tritium (H^3) have shown shunt to be either normal or only slightly increased in the majority of patients [18, 20]. Thus, although in some cases a true shunt may play a role, a VA/Q mismatch appears to be the most common cause of hypoxaemia in liver disease. This view has also been supported by measurements of arterial-to-alveolar partial pressure of nitrogen gradient (aAPN_2) [21] and VA/Q calculations [13].

When a true shunt contributes to the hypoxaemia of liver cirrhosis and a right-to-left cardiac shunt has been ruled out, the possibility remains that it could be portopulmonary. Anastomoses between the pulmonary veins and the portal venous system have indeed been demonstrated by post-mortem injection studies [22] and by recovery of Kr^{85} or H^3 in arterial blood after injection into the duodenum or the splenic pulp [18, 20, 23]. However, the O_2 saturation of portal blood is high, and it can be calculated that a portopulmonary shunt should exceed 20% of cardiac output, i.e. the whole portal flow, to account for reductions in arterial oxygenation seen in most patients with advanced liver disease [24].

What is the cause of altered VA/Q matching in liver cirrhosis? Ruff et al. attempted to answer this question by using radioactive xenon (Xe^{133}) to determine the topographical distribution of ventilation and perfusion in 10 seated patients without ascites [25]. The patients had normal lung volumes and reduced carbon monoxide (CO) diffusion capacity (DL_{CO}), 8 had decreased PaO_2 and increased

Figure 3

Measured and calculated arterial PO_2 (PaO_2) in 10 patients with liver cirrhosis. Columns show the mean actual value and the effects of normalisation procedures performed using the mathematical model of the multiple inert gas elimination technique. Thus, PaO_2 decreases after normalisation of circulating haemoglobin (Hb) and P_{50} , increases after normalisation of shunt and ventilation/perfusion (VA/Q) imbalance, and increases even further after addition of measured increases in ventilation (VE) and P_{50} . From [28].



AaPO_2 and aAPN_2 , and 3 had an increased true shunt when breathing pure O_2 . Closing volumes were found to be elevated above normal in all patients and greater than functional residual capacity in 8, who thus had airway closure and gas trapping during normal tidal volume breathing. Direct measurements in 5 of the patients confirmed the presence of abnormal gas trapping in the lower zones both at residual volume and at functional residual capacity, and showed a marked reduction in VA/Q to less than 0.5 at the lung bases, primarily as a result of decreased ventilation due to airway closure. The authors suggest that increased closing volumes in liver cirrhosis could be due to mechanical compression of small airways by dilated blood vessels and/or interstitial oedema.

Another explanation for VA/Q imbalance in liver cirrhosis has been proposed by Daoud et al. [26]. The authors investigated 10 patients with advanced alcoholic cirrhosis by right and left heart catheterisation in normoxia and during brief periods of hypoxic breathing (fraction of inspired O_2 , F_iO_2 , 0.08–0.14), and found that acute inspiratory hypoxia failed to increase PVR while similar severity of acute inspiratory hypoxia increased PVR in controls. This result suggested that at least part of VA/Q imbalance and resulting hypoxaemia in liver cirrhosis could be due to a loss of hypoxic regulation of pulmonary perfusion. Hypoxaemia in liver cirrhosis could therefore be explained by abnormalities of both ventilation distribution and perfusion distribution. The fact remains that in low VA/Q areas a much smaller decrease in ventilation than an increase in perfusion is required to lower VA/Q (in fact, ten times less if $\text{VA}/\text{Q} = 1/10$). On the other hand, inhibition of hypoxic pulmonary vasoconstriction is not a universal finding in liver cirrhosis [5, 27, 28]. Inhibition of hypoxic pulmonary vasoconstriction, associated with low PVR and high cardiac output, is in fact only to be found in patients with most advanced liver disease and shunt-induced hypoxaemia [27]. Thus, in the majority of patients with liver cirrhosis there is a VA/Q imbalance chiefly caused by abnormal distribution of ventilation, aggravated on the perfusion side by loss of hypoxic pulmonary vasoconstriction in a minority of the most severely ill patients.

It has been suggested by Rodman et al. that portal hypertension rather than altered liver function may account for abnormal gas exchange in liver cirrhosis [8]. One of their patients did indeed have a normal liver but portal vein thrombosis and arterial O_2 saturation of 87.1%. However, the cause may rather be portosystemic shunting, since surgical portocaval anastomosis has not been shown to improve blood gases [21]. Kennedy and Knudsen reported on a patient who developed hypoxaemia 4 years after therapeutic portocaval shunting [29].

Arterial hypoxaemia in liver cirrhosis is in most instances not sufficiently severe to account for the constantly observed hyperventilation [7, 8, 13–15]. We and others found no correlation between ammonia levels and ventilation [1, 7]. The cause of increased ventilation in liver cirrhosis is still imperfectly understood.

More recent studies have investigated the mechanisms of abnormal gas exchange in liver cirrhosis using the multiple inert gas elimination technique [27, 28, 30, 31]. While this approach does not allow measurement of the topographical distributions of VA and of Q independently but expresses the distribution of VA and of Q as a function of VA/Q, it has the advantage of accurately measuring true shunt using the less soluble gas SF_6 , and allows quantification of all the pulmonary and extrapulmonary determinants of PaO_2 . In patients with mild to moderate hypoxaemia multiple inert gas elimination studies have shown that hypoxaemia is essentially caused by low VA/Q regions, without distinguishing between decreased VA or relatively increased Q as a cause, no or minimal shunt, and no detectable diffusion limitation [27, 28]. The mathematical model of the method was used to quantify all the pulmonary (ventilation, diffusion, low VA/Q, and true shunt) and extrapulmonary (haemoglobin, P_{50}) determinants of PaO_2 . The results are summarised in Figure 3. They show the major role of low VA/Q, which is enhanced by increased P_{50} and decreased haemoglobin but markedly counterbalanced by increased ventilation, and the negligible effect of increased true shunt [28]. In patients with severe hypoxaemia shunt became prominent, accounting for up to half of the hypoxaemia, and a slight diffusion limitation could be evidenced [30, 31].

The hepatopulmonary syndrome

In 1884 Fluckiger reported a case of advanced liver disease, probably of syphilitic origin, with cyanosis and digital clubbing but without evidence of cardiac or pulmonary disease [32]. Cirrhotic patients may indeed present with frank cyanosis, exertional dyspnoea, clubbing of the fingers and severe hypoxaemia [5, 29, 33–39]. In these patients chest x-rays are frequently abnormal, with pulmonary vascular prominence or diffuse reticulonodular densities in the peripheral pulmonary fields [37]. Assuming the erect position may accentuate hypoxaemia (“orthodeoxia”) [29, 38] or produce dyspnoea (“platypnea”) [38], and hypoxaemia may also be aggravated by exercise [29, 37]. In these patients breathing pure O₂ may or may not reveal a true shunt, while flow through dilated pulmonary vessels can be confirmed by various techniques such as pulmonary angiography [34], Kr⁸⁵ or H³ injections [18], intravenous radioactive technetium-labelled macroaggregated albumin followed by whole body scanning [38], or postmortem injections with micropaque gelatin suspensions [36, 37]. The variable effects of pure O₂ breathing can be accounted for by variable contributions of a diffusion/perfusion defect or a true shunt [39–43]. In the event of a diffusion/perfusion imbalance, high inspired PO₂ may sufficiently increase alveolar PO₂ for the O₂ molecules to diffuse to the centre of dilated pulmonary capillaries. Increased pulmonary blood flow on exercise may prevent this alveolocapillary PO₂ equilibrium [44]. In true pulmonary shunt no gas exchange is possible between the shunted blood flow and the alveolar space. When visualised, pulmonary arteriovenous shunts are localised predominantly in the lung bases, a fact which accounts for orthodeoxia due to the effects of gravity.

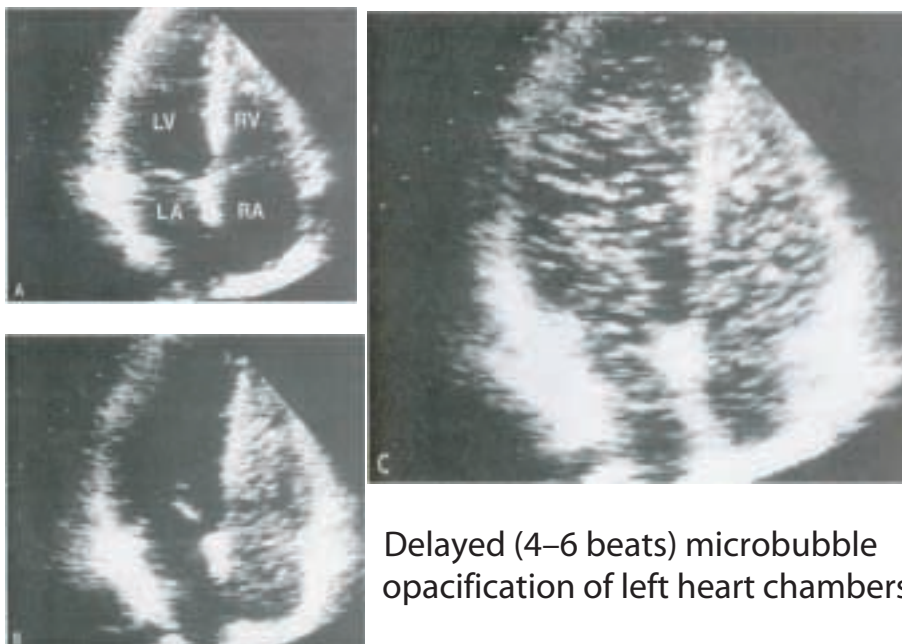
The term “hepatopulmonary syndrome” was first proposed by Kennedy and Knudson to describe cyanosis which developed 4 years after surgical porto-caval shunt in a patient with liver cirrhosis [29]. Whether or not the hepatopulmonary syndrome represents the extreme of a continuum from low VA/Q to shunt and diffusion/perfusion disequilibrium is unclear. The hepatopulmonary syndrome has been defined by the triad of liver cirrhosis, widespread pulmonary vasodilatation and AaPO₂ in excess of 20 mm Hg breathing room air [42, 43]. This definition is unsatisfactory, since the syndrome is also seen in association with portal hypertension without liver cirrhosis, and because in the presence of widespread pulmonary vasodilatation AaPO₂ is usually much higher than 20 mm Hg. The normal limits of AaPO₂ are wider than is generally believed, because PAO₂ is a calculated “ideal” value from the simplified form of the alveolar gas equation and an assumption on the respiratory quotient. The AaPO₂ gradient may exceed 20 mm Hg in healthy subjects with perfectly normal lungs [1]. A recent study showed that the positive predictive value for hepatopulmonary syndrome is about 30% for AaPO₂ above 20 mm Hg but 100% for a PaO₂ below 65 mm Hg breathing room air [45].

Accordingly, we prefer to define the hepatopulmonary syndrome more clinically, by the coexistence of dyspnoea, cyanosis (which requires PaO₂ below 60 mm Hg), possibly with digital clubbing, orthodeoxia and platypnea due to portal hypertension and associated portosystemic shunting, and demonstrable pulmonary vascular dilatations. The incidence of hepatopulmonary syndrome as defined by these more stringent criteria is some 10% in patients hospitalised for liver cirrhosis [1],

Figure 4

Echocardiographic M-mode image of microbubble appearance in left ventricle of a patient with hepatopulmonary syndrome.

Diagnostic imaging: contrast-enhanced echocardiography



Delayed (4–6 beats) microbubble opacification of left heart chambers

and 10–20% in patients who are candidates for liver transplantation [46]. Currently pulmonary vascular dilatations are easily identified by contrast echocardiography [47]. As illustrated in Figure 4, microbubbles are injected intravenously and appear in the left heart chambers after 4–6 beats if there are abnormal pulmonary vascular dilatations.

The cause of hepatopulmonary syndrome is not precisely known. Clinical studies point to a decrease in pulmonary vascular tone and reactivity with the progression of liver disease [39–43]. Rats with bile duct ligation-induced cirrhosis exhibit features of the hepatopulmonary syndrome, with low systemic and pulmonary vascular resistances, increased AaPO₂, and loss of hypoxic pulmonary vasoconstriction [48]. A role for increased endogenous production of the potent vasodilating mediator nitric oxide (NO) has been postulated, on the basis of increased expressions of NO synthase reported in experimental liver cirrhosis in rats [49] and increased exhaled NO correlated with AaPO₂ in patients with liver cirrhosis [50]. Other observations point to the normal control exercised by the liver on pulmonary angiogenesis. Diffuse pulmonary arteriovenous malformations and vascular

dilatations angiographically and histologically similar to hepatopulmonary syndrome are observed after anastomosis of the superior vena cava to the right pulmonary artery [51], the vascular abnormalities reversing after surgical redirection of hepatic venous flow to the pulmonary vascular bed [52]. There is thus a still unidentified hepatic factor which limits excessive angiogenesis in the pulmonary circulation and may become insufficient in advanced liver disease [43].

The prognosis of hepatopulmonary syndrome is poor, with one year survival rates between 16 and 38% once PaO₂ is lower than 50 mm Hg [40–43]. No drug therapy has proved efficacious. As mentioned above, hepatopulmonary syndrome is commonly seen in patients on a waiting list for liver transplantation. While definitely an operative risk, hepatopulmonary syndrome progressively reverses over weeks to months after successful liver transplantation [40–43]. Reversal of hepatopulmonary syndrome after liver transplantation is slowest, and possibly incomplete, in patients with the largest preoperative shunts and pulmonary vascular dilatations [40–43].

Portopulmonary hypertension

Mantz and Craig reported in 1951 on a woman aged 53 with a history of haematemesis who was admitted for hoarseness and dyspnoea and who died from refractory right heart failure following exploratory laparotomy [53]. Autopsy disclosed a normal liver, portal thrombosis, extensive portosystemic shunting and right ventricular hypertrophy. Microscopically there were multiple microemboli in the small pulmonary arteries, which suggested to the authors that pulmonary hypertension in their patient had been caused by recurrent microemboli from the portal venous system. However, typical lesions of primary pulmonary hypertension, including plexiform lesions, were also found. It has since been realised that portal hypertension is an important predisposing factor for primary pulmonary hypertension.

Primary pulmonary hypertension is a syndrome involving dyspnoea, fatigue, chest pain and syncope, characterised by an increase in pulmonary vascular resistance (PVR) of unknown cause [54]. In 1998, a World Health Organisation-sponsored expert consensus conference held in Evian, France, extended the concept of primary pulmonary hypertension, on the basis of similar clinical course, histopathology and response to treatment, to a series of associated conditions which included congenital left-to-right shunt, connective tissue disease, human immunodeficiency virus infection and portal hypertension, and coined the term “pulmonary arterial hypertension” (PAH) [55]. The incidence of PAH in patients with portal hypertension is difficult to assess

but is reported to be as high as 2% [43]. In a retrospective series of 436 patients with the diagnosis of primary pulmonary hypertension, 13% were also diagnosed with portal hypertension [43]. The definition of PAH may be a problem in patients with liver disease who may also present with high cardiac output. Pulmonary arterial hypertension is defined as mean pulmonary artery pressure above 25 mm Hg at rest and 30 mm Hg on exercise [54]. Bearing in mind that the pulmonary artery pressure-flow relationship normally shows a slope of 2–2.5 mm Hg/L/min [56], it is evident that a cirrhotic patient with a high cardiac output is likely to be wrongly diagnosed as having portopulmonary hypertension. This at least partly explains why PAH has been diagnosed in up to 20% of patients with advanced liver disease [57]. We therefore prefer to diagnose portopulmonary hypertension as a mean pulmonary artery pressure above 25 mm Hg at rest, together with a PVR in excess of 250 dyne.s.cm⁻⁵, both being safely above the upper limit of normal including correction for age [56], and a hepatic venous pressure gradient above 10 mm Hg (upper limit of normal is believed to be 5 mm Hg). One patient in our previously reported series of 100 consecutive cirrhotics [1] was diagnosed as having portopulmonary hypertension using these stringent criteria.

Patients with portopulmonary hypertension are clinically similar to those with primary pulmonary hypertension, except for being 5–10 years older on average, with an equal sex ratio (against a 2:1 female to male ratio), a somewhat less advanced

New York Heart Association functional class, a lower mean pulmonary artery pressure (5–10 mm Hg) and higher cardiac output (1 L/min) [43]. Somewhat surprisingly, survival in portopulmonary hypertension was also found to be better, with a median survival time of 57 months against 31 months ($p < 0.05$) in a large retrospective series before the advent of prostacyclin therapy [43].

What can be done for the patient with portopulmonary hypertension? Drug therapy with chronic intravenous prostacyclin is feasible [43, 58] and improves functional state, exercise capacity and survival as reported in purely primary pulmonary hypertension. However, even if stabilised or improved by prostacyclin therapy, pulmonary hypertension remains a serious contraindication to liver transplantation. Overall mortality of liver transplantation in patients with pulmonary hypertension is as high as 35% [57]. According to a re-

cent study from the Mayo Clinic, cardiopulmonary mortality of liver transplantation is 100% if mean pulmonary artery pressure exceeds 50 mm Hg, and is as high as 50% if mean pulmonary artery pressure is between 35 and 50 mm Hg and PVR greater than 250 dyne.s.cm⁻⁵ [59]. No regression of pulmonary hypertension has been reported after liver transplantation. It is not known whether combined liver-lung transplantation may be a reasonable option for some patients.

Correspondence:

Dr. R. Naeije

Department of Physiology

Erasmie Campus, CP 604

B-1070 Brussels

E-Mail: rnaeije@ulb.ac.be

References

- Naeije R, Mélot C, Hallemans R, Mols P, Lejeune P. Pulmonary hemodynamics in liver cirrhosis. *Semin Respir Med* 1985;7: 164–71.
- Hallemans R, Naeije R, Mols P, Mélot C, Reding P. Treatment of portal hypertension with isosorbide dinitrate, alone or in combination with vasopressin. *Crit Care Med* 1983;11:536–40.
- Naeije R, Hallemans R, Mols P, Mélot C, Reding P. Effects of vasopressin and somatostatin on hemodynamics and blood gases in patients with liver cirrhosis. *Crit Care Med* 1982;10:578–82.
- Mols P, Hallemans R, Van Kuyk M, Mélot C, Lejeune P, Ham H, et al. Hemodynamic effects of vasopressin, alone and in combination with nitroprusside, in patients with liver cirrhosis and portal hypertension. *Ann Surg* 1984;199:176–81.
- Naeije R, Hallemans R, Mols P, Mélot C. Hypoxic pulmonary vasoconstriction and liver cirrhosis. *Chest* 1981;80:570–4.
- Snell AM. The effects of chronic disease of the liver on the composition and physicochemical properties of blood: changes in the serum proteins, reduction in the oxygen saturation of the arterial blood. *Ann Intern Med* 1935;9:690–711.
- Heineman HO, Emirgil C, Mijnsen JP. Hyperventilation and arterial hypoxemia in cirrhosis of the liver. *Am J Med* 1960;28: 239–46.
- Rodman T, Sobel M, Close HP. Arterial oxygen saturation and the ventilation-perfusion defect of Laennec's cirrhosis. *N Engl J Med* 1960;263:73–7.
- Keys A, Snell AM. Respiratory properties of the arterial blood in normal men and in patients with disease of the liver: position of the oxygen dissociation curve. *J Clin Invest* 1938;17:59–67.
- Caldwell PRB, Fritts HW, Courmand A. Oxyhemoglobin dissociation curve in liver cirrhosis. *J Appl Physiol* 1965;20: 316–20.
- Zimmon DS. Oxyhemoglobin dissociation in patients with hepatic encephalopathy. *Gastroenterology* 1967;52:747–54.
- Astrup J, Rorth M. Oxygen affinity of hemoglobin and red cell 2,3-diphosphoglucerate in hepatic cirrhosis. *Scand J Clin Lab Invest* 1973;31:311–5.
- Karetsky MS, Mithoefer JC. The cause of hyperventilation and arterial hypoxia in patients with cirrhosis of the liver. *Am J Med Sci* 1967;254:797–804.
- Abelman WH, Kramer GE, Verstraeten JM, Gravalles Ma, Mc Neely WF. Cirrhosis of the liver and decreased arterial oxygen saturation. *Arch Intern Med* 1961;108:102–8.
- Massumi RA, Rios JC, Tickin HE. Hemodynamic abnormalities and venous admixture in portal cirrhosis. *Am J Med Sci* 1965;250:275–83.
- Williams MH. Hypoxemia due to venous admixture in cirrhosis of the liver. *J Appl Physiol* 1960;15:253–4.
- Bashour FA, Cochran P. Alveolar-arterial oxygen tension gradients in cirrhosis of the liver. *Am Heart J* 1966;71:734–40.
- Mellemgaard K, Winkler K, Tygstrup N, Georg J. Sources of veno-arterial admixture in portal hypertension. *J Clin Invest* 1963;42:1399–405.
- Wilson RH, Ebert RV, Borden CW, Pearson RT, Johnson RS, Falk A, et al. The determinations of blood flow through non ventilated portions of the normal and diseased lung. *Am Rev Tuberc* 1953;68:177–87.
- Fritts W, Hardewig A, Rochester DF, Durand J, Courmand A. Estimation of pulmonary arteriovenous shunt flow using intravenous injections of T-1824 and Kr⁸⁵. *J Clin Invest* 1960;39: 1841–50.
- Cotes JE, Field GB, Brown GJA, Read AE. Impairment of lung function after portocaval anastomosis. *Lancet* 1968;1:952–5.
- Calabresi P, Abelman WH. Porto-caval and porto-pulmonary anastomosis in Laennec's cirrhosis and in heart failure. *J Clin Invest* 1957;36:1257–65.
- Shaldon S, Caesar J, Chiandussi L, Williams HS, Sheville E, Sherlock S. The demonstration of porto-pulmonary anastomosis in portal cirrhosis with the use of radioactive Krypton (Kr⁸⁵). *N Engl J Med* 1961;265:410–4.
- Nakamura T, Nakamura S, Tazoura T, Abe S, Aikawa T, Tokira K. Measurement of blood flow through porto-pulmonary anastomosis in portal hypertension. *J Lab Clin Med* 1965;65: 114–21.
- Ruff F, Hughes JMB, Stanley N, Mc Carthy D, Geen R, Aronoff A, et al. Regional lung function in patients with hepatic cirrhosis. *J Clin Invest* 1971;50:2403–13.
- Daoud FS, Reeves JT, Schaefer JW. Failure of hypoxic pulmonary vasoconstriction in patients with liver cirrhosis. *J Clin Invest* 1972;51:1076–80.
- Rodriguez-Roisin R, Roca J, Agusti AGN, Mastai R, Wagner PD, Bosch J. Gas exchange and pulmonary vascular reactivity in patients with liver cirrhosis. *Am Rev Respir Dis* 1987;135: 1085–92.
- Mélot C, Naeije R, Dechamps P, Hallemans R, Lejeune P. Pulmonary and extrapulmonary contributors to hypoxemia in liver cirrhosis. *Am Rev Respir Dis* 1989;139:632–40.
- Kennedy TC, Knudson RJ. Exercise-aggravated hypoxemia and orthodeoxia in cirrhosis. *Chest* 1977;72:305–9.
- Edell ES, Cortese DA, Krowka MJ, Rehder K. Severe hypoxemia and liver disease. *Am Rev Respir Dis* 1989;142:1631–5.
- Castaing Y, Manier G. Hemodynamic disturbances and VA/Q matching in hypoxemic cirrhotic patients. *Chest* 1989;96:1064–9.
- Fluckiger M. Vorkommen von trommelschlägelförmigen Fingerendphalangen ohne chronische Veränderungen an der Lungen oder am Herzen. *Wien Med Wschr* 1884;34:1457.
- Rydell R, Hoffbaner FW. Multiple arterio-venous fistulas in juvenile cirrhosis. *Am J Med* 1956;21:450–60.
- Hansoti RC, Shah NJ. Cirrhosis of liver simulating congenital cyanotic heart disease. *Circulation* 1966;33:71–7.

- 35 Berthelot P, Walker JG, Sherlock S, Reid L. Arterial changes in the lungs in cirrhosis of the liver – lung spider naevi. *N Engl J Med* 1966;274:291–8.
- 36 Karlish AJ, Marshall R, Reid L, Sherlock S. Cyanosis with hepatic cirrhosis. A case with multiple arterio-venous shunting. *Thorax* 1967;22:555–61.
- 37 Stanley NN, Woodgate DJ. Mottled chest radiograph and gas transfer defect in chronic liver disease. *Thorax* 1972;27:315–22.
- 38 Robin ED, Laman D, Horn BR, Theodore J. Platypnea related to orthodeoxia caused by true vascular shunts. *N Engl J Med* 1976;294:941–3.
- 39 Davis HH, Schwarz DJ, Lefrak SS, Susman N, Schainker BA. Alveolar capillary oxygen disequilibrium in hepatic cirrhosis. *Chest* 1978;73:507–11.
- 40 Krowka MJ, Cortese DA. Hepatopulmonary syndrome. Current concepts in diagnosis and therapeutic considerations. *Chest* 1994;105:1528–37.
- 41 Lange PA, Stoller JK. The hepatopulmonary syndrome. *Ann Intern Med* 1995;122:521–9.
- 42 Rodriguez-Roisin R, Agusti A, Roca J. The hepatopulmonary syndrome: new names, old complexities. *Thorax* 1992;47:897–902.
- 43 Herve P, Lebrec D, Brenot F, Simonneau G, Humbert M, Sitbon O, et al. Pulmonary vascular disorders in portal hypertension. *Eur Respir J* 1998;11:1153–66.
- 44 Thorens JB, Junod AF. Hypoxaemia and liver cirrhosis: a new argument in favour of a “diffusion-perfusion defect”. *Eur Respir J* 1992;5:754–6.
- 45 Schenk P, Fuhrman V, Madl C, Funk G, Lehr S, Kandel O, et al. Hepatopulmonary syndrome: prevalence and predictive value of various cut offs for arterial oxygenation and their clinical consequences. *Gut* 2002;51:853–9.
- 46 Martinez GP, Barbera JA, Visa J, Rimola A, Pare JC, Roca J, et al. Hepatopulmonary syndrome in candidates for liver transplantation. *J Hepatol* 2001;34:651–7.
- 47 Krowka MJ, Tajik JA, Dickson RE, Wiesner RH, Cortese DA. Intrapulmonary vascular dilatations in liver transplant candidates. Screening by two-dimensional contrast-enhanced echocardiography. *Chest* 1990;97:1165–70.
- 48 Chang SW, Ohara N. Pulmonary circulatory dysfunction in rats with biliary cirrhosis: an animal model of the hepatopulmonary syndrome. *Am Rev Respir Dis* 1992;145:796–805.
- 49 Nunes H, Lebrec D, Mazmanian M, Capron F, Heller J, Tazi KA, et al. Role of nitric oxide in hepatopulmonary syndrome in cirrhotic rats. *Am J Respir Crit Care Med* 2001;164:879–85.
- 50 Rolla G, Brussino L, Colagrande P, Dutto L, Polizzi S, Scapaticci E, et al. Exhaled nitric oxide and oxygenation abnormalities in hepatic cirrhosis. *Hepatology* 1997;26:842–7.
- 51 Srivastava D, Preminger T, Lock JE, Mandell V, Keane JF, Mayer JE Jr, et al. Hepatic venous blood and the development of pulmonary arterio-venous malformations in congenital heart disease. *Circulation* 1995;92:1217–22.
- 52 Shah MJ, Rychick J, Fogel MA, Murphy JD, Jacobs ML. Pulmonary arterio-venous malformations after superior cavopulmonary connection: resolution after inclusion of hepatic veins in the pulmonary circulation. *Ann Thorac Surg* 1997;63:960–3.
- 53 Mantz FA, Craige E. Portal axis thrombosis with spontaneous porto-caval shunt and resultant cor pulmonale. *Arch Pathol* 1951;52:91–7.
- 54 Rubin LJ. Primary pulmonary hypertension. *N Engl J Med* 1997;33:111–7.
- 55 Fishman AP. Clinical classification of pulmonary hypertension. *Clin Chest Med* 2001;22:385–91.
- 56 Naeije R. Pulmonary circulation. In: *Respiratory Medicine*. Third edition. Edited by CJ Gibson, DM Geddes, U Costabel, PJ Sterk, B Corris. Saunders, London, 2003, vol I, chap 2.6, pp 147–157.
- 57 Krowka MJ. Hepatopulmonary syndromes. *Gut* 2000;46:1–4.
- 58 Kuo PC, Johnson LB, Plotkin JS, Howell CD, Bartlett ST, Rubin LJ. Continuous intravenous infusion of epoprostenol for the treatment of portopulmonary hypertension. *Transplantation* 1997;63:604–6.
- 59 Krowka MJ, Plevak DJ, Findlay JY, Rosen CB, Wiesner RH, Krom RA. Pulmonary hemodynamics and perioperative cardiopulmonary-related mortality in patients with portopulmonary hypertension undergoing liver transplantation. *Liver Transpl* 2000;6:443–50.

The many reasons why you should choose SMW to publish your research

What Swiss Medical Weekly has to offer:

- SMW's impact factor has been steadily rising, to the current 1.537
- Open access to the publication via the Internet, therefore wide audience and impact
- Rapid listing in Medline
- LinkOut-button from PubMed with link to the full text website <http://www.smw.ch> (direct link from each SMW record in PubMed)
- No-nonsense submission – you submit a single copy of your manuscript by e-mail attachment
- Peer review based on a broad spectrum of international academic referees
- Assistance of our professional statistician for every article with statistical analyses
- Fast peer review, by e-mail exchange with the referees
- Prompt decisions based on weekly conferences of the Editorial Board
- Prompt notification on the status of your manuscript by e-mail
- Professional English copy editing
- No page charges and attractive colour offprints at no extra cost

Editorial Board

Prof. Jean-Michel Dayer, Geneva
 Prof. Peter Gehr, Berne
 Prof. André P. Perruchoud, Basel
 Prof. Andreas Schaffner, Zurich
 (Editor in chief)
 Prof. Werner Straub, Berne
 Prof. Ludwig von Segesser, Lausanne

International Advisory Committee

Prof. K. E. Juhani Airaksinen, Turku, Finland
 Prof. Anthony Bayes de Luna, Barcelona, Spain
 Prof. Hubert E. Blum, Freiburg, Germany
 Prof. Walter E. Haefeli, Heidelberg, Germany
 Prof. Nino Kuenzli, Los Angeles, USA
 Prof. René Lutter, Amsterdam,
 The Netherlands
 Prof. Claude Martin, Marseille, France
 Prof. Josef Patsch, Innsbruck, Austria
 Prof. Luigi Tavazzi, Pavia, Italy

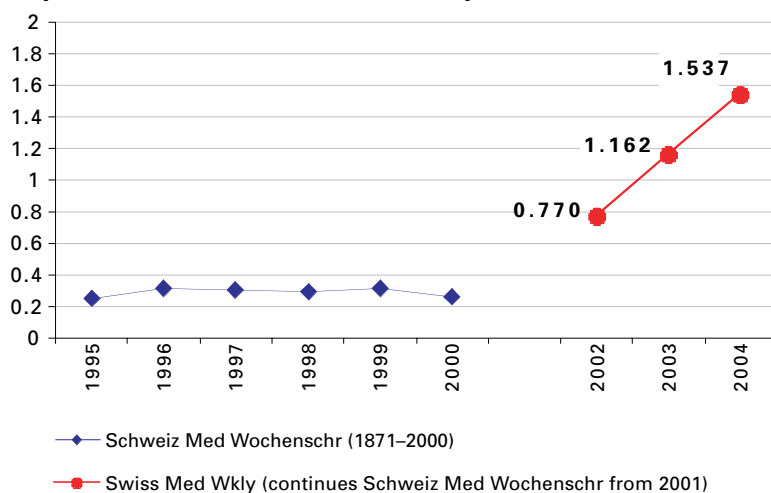
We evaluate manuscripts of broad clinical interest from all specialities, including experimental medicine and clinical investigation.

We look forward to receiving your paper!

Guidelines for authors:

http://www.smw.ch/set_authors.html

Impact factor Swiss Medical Weekly



All manuscripts should be sent in electronic form, to:

EMH Swiss Medical Publishers Ltd.
 SMW Editorial Secretariat
 Farnsburgerstrasse 8
 CH-4132 Muttenz

Manuscripts: submission@smw.ch
 Letters to the editor: letters@smw.ch
 Editorial Board: red@smw.ch
 Internet: <http://www.smw.ch>