

The endothelium and genetics in pulmonary arterial hypertension

Laurent P. Nicod

Clinic and Polyclinic of Pneumology, University Hospital, Berne, Switzerland

Summary

There have been tremendous progresses in research and improvement in therapeutic options for pulmonary arterial hypertension (PAH) and other types of pulmonary hypertension (PH) over the last 15 years.

PAH and other PH have been shown to present similar histopathologic changes and therefore, do not indicate lung biopsies for a specific diagnosis. This may be due to shared physiopathologic mechanisms, involving initially endothelial alterations, leading to three main changes: vasoconstrictive phenomena, growth factor releases, leading to small vessel remodelling and to thrombotic phenomena.

Genetic polymorphisms have been discovered in two genes of the transforming growth factor family (the bone morphogenetic protein receptor II and the activin receptor-like kinase) and one in the serotonin transporter gene. The genetic findings are not yet applicable for genetic counselling, but the physiopathologic discoveries have allowed major therapeutic progresses.

Key words: pulmonary arterial hypertension; transforming growth factors; BMP receptor; activin receptor-like kinase-1; serotonin transporter gene

Introduction

The occurrence of pulmonary hypertension with right ventricular hypertrophy and “pulmonary arterial sclerosis” in the absence of any causal lesions was originally described in 1891 by Romberg [1]. This isolated or “primary” pulmonary vascular disease was later haemodynamically characterised by using right heart catheterism, where pulmonary pressure and pulmonary resistance were measured and shown to be partially reversible with pharmacological agents [2, 3]. Soon afterwards, the histopathologic picture of the disease was described as a combination of medial hypertrophy, intimal proliferation and adventitial changes, in situ microthrombosis, fibrinoid necrosis and plexiform lesions [4], very similar to pulmonary vascular changes in hypertension, secondary to congenital heart diseases [5].

It has lately been found that a series of conditions, such as the intake of appetite-suppressants, connective tissue disease, human immunodeficiency virus (HIV) and liver cirrhosis, in addition to already known chronic left to right cardiac

shunting, were all leading to pulmonary arterial hypertension (PAH) and named as such in 1998, during a World Health Organisation sponsored expert consensus conference in Evian. PAH is since then an entity, including idiopathic PAH (IPAH) and familial PAH (FPAH) (representing 5% of PAH), and PAH occurring in association with a series of conditions, as mentioned above [6]. In the new Venice classification of 2003 [6], pulmonary capillary haemangiomatosis and pulmonary vein occlusive disease were also added to the PAH classification (table 1).

Lately, the pathobiology of PAH has been much better understood. It has been realised, that the process of vascular remodelling involves all the compartments of the pulmonary arterial walls [7]. In addition to the vasoconstriction, primarily related to endothelial dysfunction, a series of events, such as intimal fibrosis, medial hypertrophy, adventitial proliferation, in situ thrombosis, fibrinoid necrosis and plexiform lesions have to be mentioned.

Table 1
Clinical classification
of pulmonary hyper-
tension.

1. Pulmonary arterial hypertension (PAH)	1.1. idiopathic (IPAH)	
	1.2. familial (FPAH)	
	1.3. associated with (APAH)	1.3.1. connective tissue disease 1.3.2. congenital systemic to pulmonary shunts 1.3.3. portal hypertension 1.3.4. HIV infection 1.3.5. drugs and toxins 1.3.6. others (thyroid disorders, glycogen storage disease, Gaucher's disease, hereditary haemorrhagic telangiectasia, haemoglobinopathies, myeloproliferative disorders, splenectomy)
	1.4. associated with significant venous or capillary involvement	1.4.1. pulmonary vein occlusive disease (PVOD) 1.4.2. pulmonary capillary haemangiomatosis (PCH)
	1.5. Persistent pulmonary hypertension of the newborn (PPHN)	
2. Pulmonary hypertension associated with left heart diseases		
3. Pulmonary hypertension associated with lung respiratory diseases and / or hypoxia		
4. Pulmonary hypertension due to chronic thrombotic and / or embolic diseases		
5. Miscellaneous: sarcoidosis, histiocytosis, lymphangiomatosis, compression of pulmonary vessels		

Definition of pulmonary arterial hypertension

PAH is defined as a mean pulmonary arterial pressure, higher than 25 mm Hg at rest and 30 mm Hg during exercise, together with a resting left arterial pressure (often measured as occluded arterial pressure or “wedge” pressure) lower than 15 mm Hg. To fulfil the definition, the pulmonary vascular resistance should be higher than three wood units or $240 \text{ dyn.s.cm}^{-5}$. Reliable pulmonary vascular pressure and flow measurement are needed to allow the extrapolation of resistances and a right heart catheterisation is required.

As shown in table 1, the diagnosis of PAH requires the exclusion of conditions associated with

pulmonary hypertension due to chronic increase of pulmonary venous pressure, abnormal respiratory mechanisms and lung parenchymal diseases, leading to hypoxia or thromboembolic diseases [6].

It is important to know that the current definition of PAH is essentially clinical, with no or minimal reliance on pathological examination, as lung biopsies have been abandoned because of an insufficient benefit / risk ratio and the lack of specific findings in the various types of PAH, encountered even in those associated with other diseases.

Histopathological abnormalities in PAH

Lesions in small pulmonary arteries and arterioles are the characteristic features of PAH. Changes in the large pulmonary arteries are secondary to pulmonary hypertension and include dilatation, medial hypertrophy and arteriosclerotic plaques. There, the changes in the heart are related to the ventricular response to the increasing pulmonary hypertension, with increase in right ventricular mass and later dilatation.

Alterations of normally non-muscular pulmonary arteries

Pulmonary hypertensive remodelling leads to the appearance of a layer of smooth muscles in small peripheral, normally non-muscular pulmonary arteries within the respiratory acinus. In precapillary vessels, intermediary cells inside the internal elastic laminae proliferate and differentiate into smooth muscle cells [8].

Muscularisation of muscular pulmonary arteries

In the more proximal muscular arteries, proliferation and hypertrophy of medial smooth muscles occur, leading to a fixed reduction in the vessel lumen. New elastic laminae are deposited, and increased type I collagen deposition stiffens the vessel wall [9]. In addition to the changes in the media, there is proliferation of fibroblasts in the adventitial layer along with collagen deposition.


Endothelial damage / activation, leading to increased permeability to seric factors, is thought to be a key mechanism, leading to excess vascular muscularisation in the proximal pulmonary arteries.

Neointima formation

The available evidence suggests that proliferating cells, arising in the media and adventitia of

Figure 1

Small lung vessel changes seen in most types of pulmonary hypertension. The hypertrophy of the media and the neointima are shown, as well as the plexiform lesions, which consist of small neovessels, arising from the arteries.



impaired arteries, migrate to the sub-endothelial space. This leads to the formation of a layer of cells and extra-cellular matrix between the endothelium and the internal elastic lamina, termed as neointima [10]. This phenomenon is the hall mark of PAH.

Whether endothelial or smooth muscle cells based lesions have a similar impact on the course of PH, is unclear. However, these lesions may arise from similar progenitors, because endothelial cells can transdifferentiate into smooth muscle cells, when stimulated with platelet derived growth factor or transforming growth factor [11].

Formation of plexiform lesions

PAH leads to the disorganised proliferation of endothelial cells, leading to formation of the so called plexiform lesions. These new disorganised vessels are detected in 80% of PAH cases and in severe PAH associated to other diseases. They are typically recognised to arise from arteries of 200–400 μm diameter. The cells, comprising these lesions, are endothelial channels, supported by stroma containing matrix proteins and myofibroblasts, expressing α -smooth muscle acting ([11] figure 1).

The endothelium in the PAH

The endothelium provides an anti-thrombotic, semi-permeable barrier between the vascular lumen and the extra-vascular fluid compartments and exerts profound effects on vascular tone, growth and differentiation.

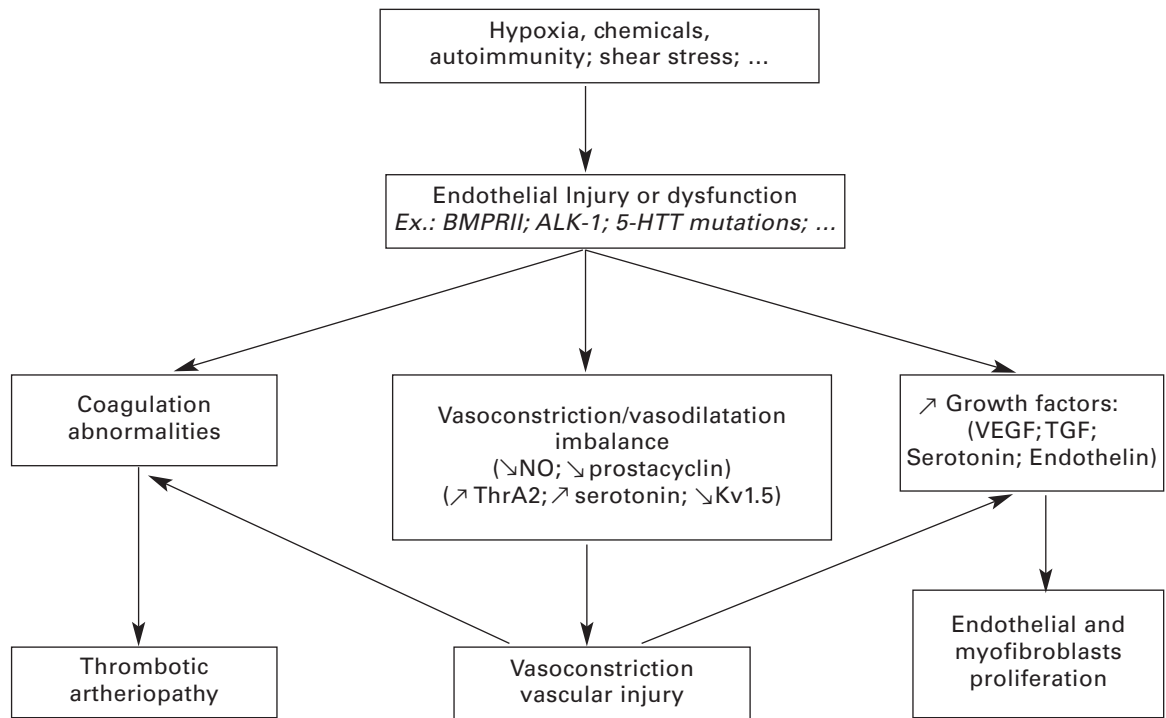
In PAH, the initiating injury of the endothelium may be hypoxia, increased flow (shear stress), inflammation of the response to drugs (eg dexfenfluramine) or toxins (eg adult erated rape seed oil), in the context of genetic susceptibility. These various injuries may be epigenetic factors, which have an influence on cell growth, differentiation and normal homeostatic functions of the endothelium, by altering endothelial permeability, production of growth factors and coagulation factors (figure 2).

Shear stress represents a good example of these types of injuries. It is caused by increases in blood flow and notably observed in the presence of left to right shunts (eg congenital heart diseases). Shear stress induces transduction signals in the endothelium, which produce vasoactive mediators (eg endothelin-1 (ET-1), angiotensin II, thromboxane, nitric oxides, prostacyclin, growth factors (eg platelet-derived growth factors

(PDGF) and transforming growth factor- β (TGF- β)), to maintain vascular homeostasis by reducing or increasing the vessel diameter. Transduction signals occur probably, when cytoskeletal components are tethered at the cell membrane [12]. Protein kinases are activated at these sides, which phosphorylate and activate downstream signals. Several observations suggest that immune reactions play a role in the perpetration, if not in the initiation of PAH [13]. Indeed, pulmonary arterial hypertension occurs in association with inflammatory states, such as connective tissue disease and HIV infection. Areas of focal necrosis with inflammatory reactions have long been described in inflammatory vessel walls of patients with PAH. Plexiform lesions and small arterioles are infiltrated by numerous T lymphocytes and macrophages [14]. Besides, increased circulating levels of interleukin-1 and interleukin-6, which promote thrombosis, are potent mitogens. Recent studies point out an increased level of soluble CD40 ligand and macrophage chemotactant protein (MCP-1), to be a pathway to promote a chemokine mediated inflammatory reaction in pulmonary arteriole walls [15].

Figure 2

Physiopathology, leading to pulmonary arterial hypertension with the three major changes: vasoconstriction, vascular remodelling and thrombotic phenomena.



One of the major functions of the pulmonary endothelium is to filter small thrombi from the systemic vein continuously filtered by the lungs, where they undergo fibrinolysis and where the endothelium prevents the formation of thrombus. In situ thrombosis in small pulmonary arteries is a feature of patients with idiopathic pulmonary hypertension [16]. In addition, anti-coagulation therapy with warfarin improves the survival of these patients. Recent studies have shown that there are marked elevations of circulating plasminogen activator inhibitor and von Willebrand factor in severe idiopathic pulmonary hypertension, as well as reduced soluble thrombomodulin, reflecting impaired local fibrinolysis [17].

Increase of the pulmonary vascular reactivity in early PAH has been related to endothelial dysfunction. Pulmonary vascular tone is modulated

by balanced actions of endothelium derived vasodilators, mainly prostacyclin, nitric oxide (NO), as well as vasoconstrictions, mainly thromboxane A₂ and ET-1 [18]. Patients with PAH were shown to have an increased 24 hour urinary excretion of thromboxane B₂, the stable metabolite of thromboxane A₂, as well as a decreased 24 hour urinary excretion of 6 keto-PGF₁α, the stable metabolite of prostacyclin [19]. It is thought that in PAH, in response to either hypoxia, shear stress or other injuries, occurring on a precipitating genetic background, the endothelial cells produce more vasoconstricting proliferative factors (ET-I, angiotensin II, thromboxane A₂) and less vasodilating, anti-proliferative mediators (NO, PGI₂), which may lead to vasoconstriction with progressive remodelling.

Genetic determinants of PAH

As discussed, many factors act in concert to lead to pulmonary vascular remodelling. Recent advances in our understanding of the pathogenesis of primary pulmonary hypertension have demonstrated that alteration in certain key pathways may play a central role in initiating disease or causing disease progression.

TGF-β / bone morphogenetic proteins

During recent years, discoveries in the genetics of IPAH have drawn the attention to bone morphogenetic proteins (BMPs). A gene for familial idiopathic PAH has been mapped to chromosome 2q31-32, the site of mutations in the

genes encoding the BMP receptor II (BMPRII) [20]. Mutations of BMPRII are found in about two thirds of patients with familial PAH and in 20% of patients with sporadic IPAH. However, the likelihood that carriers of BMPRII mutations develop clinical averted PAH is not higher than 10–20% [21].

Bone morphogenetic proteins are members of the TGF-β superfamily, which includes TGF-β 1–3 and activins. Bone morphogenetic proteins are multifunctional proteins, regulating cell growth, differentiation and apoptosis. In humans a variety of cell types, including pulmonary artery smooth muscle cells and endothelial cells, synthesise and

secrete BMPs [22]. BMP receptor type 1 and type 2, which are expressed on the cell surface, as both, homomeric and heteromeric complexes, play an important role in the regulation of proliferation, differentiation and apoptosis. Binding of BMP ligand (eg BMP2 and -7) to either of the receptors involves hetero-oligomerisation of BMPR-I and BMPR-II, which in turn phosphorelates and activates Smads, which subsequently form dimeric complexes and translocate in the nucleus. In cooperation with co-factors, the Smad complex represses the expression of several anti-apoptotic genes, including Bcl-2. Alternative pathways that involve MAP kinase, including p38 MAPK and JNK kinase, are now recognised. The recent studies have not only implicated Smad signalling, but also unopposed MAPK function in association with BMPR-II mutations. The resulting imbalance may lead to proliferative and antiapoptotic effects, promoting PAH [23].

The expression of BMPR-II has been reported to be decreased in IPAH, especially if BMPR-II mutations are identified, but also in ventricular septal defect associated PAH [24].

Variable *in vitro* effects of BMPs might be explained by the *in vitro* effects of angiotensin-1. Angiotensin-1 is strongly upregulated with pulmonary vascular resistance in various forms of severe pulmonary hypertension. Angiotensin-1 impairs BMPR-II signalling and shuts off BMPR-IA [25]. It is partially reverted to normal with preventive therapies, aimed at the restoration of a normal endothelium equilibrium, such as phosphodiesterase-5 inhibition by sildenafil [26] or dual ET-I receptor blockade by bosentan [27], suggesting an interaction between endothelial function and angiotensin-1 / BMPR signalling.

Activin receptor-like kinase

Hereditary haemorrhagic telangiectasis (HHT) is an autosomal dominant inherited disease, characterised by mucocutaneous telangiectasis, causing recurrent epistaxis and gastro-intestinal blood loss, as well as multiorgan arteriovenous malformations. Another heterogeneous defect in a

member of the TGF- β receptor complex family, the activin receptor-like kinase 1 (ALK-1), is now implicated in HHT. Some of the members of these families, having the ALK-1 gene defect, will develop HHT together with PAH or PAH alone [28]. ALK-1 is the second gene involved in defects leading to PAH. These genetic defects would lead to similar alterations in activation of the Smads, like those described previously with BMPR-II.

Serotonin transporter gene polymorphism

Several observations indicate a third genetic polymorphism with a possible role of serotonin in the pathogenesis of PAH. In clinical pulmonary hypertension, platelet and plasma 5-hydroxytryptamine (5-HT, serotonin) levels are increased. Serotonergic appetite-suppressants, mainly fenfluramines, have been associated with an increased risk of developing PAH [29]. It is well established that serotonin acts at membrane receptors and this essentially results in vasoconstriction. Serotonin interacts with a specific transporter to enter pulmonary vascular smooth muscle cells and this results in their proliferation. The serotonin transporter is over-expressed in pulmonary arteries and platelets from PAH patients [30]. There is some evidence, that serotonin transporter gene polymorphism is a determinant of severity of pulmonary hypertension [31]. The cascade of transcription signals is here also known and involves several kinases, as well as diacylglycerol [32].

The author thanks Rahel Holderegger for her secretarial expertise; Dr. J.C. Pache from the University of Geneva, Department of Pathology, for the kind gift of the anatomopathological picture.

Correspondence:

Professor Laurent P. Nicod
Clinic and Polyclinic of Pneumology
University Hospital
CH-3010 Berne
E-Mail: laurent.nicod@insel.ch

References

- Romberg E. Über Sklerose der Lungenarterie. *Deutsch Archiv Klin Med.* 1891;48:197-206.
- Dresdale DT, Schultz M, Michtom RJ. Primary pulmonary hypertension. I. Clinical and hemodynamic study. *Am J Med.* 1951;11(6):686-705.
- Wood P. Pulmonary hypertension with special reference to the vasoconstrictive factor. *Br Heart J.* 1958;21:557-70.
- Wagenvoort CA, Wagenvoort N. Primary pulmonary hypertension: a pathological study of the lung vessels in 156 clinically diagnosed cases. *Circulation.* 1970;42:1163-84.
- Heath D, Edwards JE. The pathology of pulmonary vascular disease: a description of six grades of structural changes in the pulmonary arteries, with special reference to the congenital cardiac septal defects. *Circulation.* 1958;18:533-47.
- Simonneau G, Galie N, Rubin LJ, Langleben D, Seeger W, Domenighetti G, et al. Clinical classification of pulmonary hypertension. *J Am Coll Cardiol.* 2004;43(12 Suppl S):5S-12S.
- Farber HW, Loscalzo J. Pulmonary arterial hypertension. *N Engl J Med.* 2004;351(16):1655-65.
- Meyrick B, Reid L. The effect of continued hypoxia on rat pulmonary arterial circulation. An ultrastructural study. *Lab Invest.* 1978;38(2):188-200.
- Meyrick B, Reid L. Hypoxia-induced structural changes in the media and adventitia of the rat hilar pulmonary artery and their regression. *Am J Pathol.* 1980;100(1):151-78.
- Yi ES, Kim H, Ahn H, Strother J, Morris T, Masliah E, et al. Distribution of obstructive intimal lesions and their cellular phenotypes in chronic pulmonary hypertension. A morphometric and immunohistochemical study. *Am J Respir Crit Care Med.* 2000;162(4 Pt 1):1577-86.
- Yamashita J, Itoh H, Hirashima M, Ogawa M, Nishikawa S, Yurugi T, et al. Flk1-positive cells derived from embryonic stem cells serve as vascular progenitors. *Nature.* 2000;408(6808):92-6.

- 12 Fisher AB, Chien S, Barakat AI, Nerem RM. Endothelial cellular response to altered shear stress. *Am J Physiol Lung Cell Mol Physiol*. 2001;281(3):L529–33.
- 13 Dorfmueller P, Perros F, Balabanian K, Humbert M. Inflammation in pulmonary arterial hypertension. *Eur Respir J*. 2003;22(2):358–63.
- 14 Tudor RM, Groves B, Badesch DB, Voelkel NF. Exuberant endothelial cell growth and elements of inflammation are present in plexiform lesions of pulmonary hypertension. *Am J Pathol*. 1994;144(2):275–85.
- 15 Damas J K, Otterdal K, Yndestad A, Aass H, Solum NO, Froland SS, et al. Soluble CD40 ligand in pulmonary arterial hypertension: possible pathogenic role of the interaction between platelets and endothelial cells. *Circulation*. 2004;110(8):999–1005.
- 16 Hassell KL. Altered hemostasis in pulmonary hypertension. *Blood Coagul Fibrinolysis*. 1998;9(2):107–17.
- 17 Welsh CH, Hassell KL, Badesch DB, Kressin DC, Marlar RA. Coagulation and fibrinolytic profiles in patients with severe pulmonary hypertension. *Chest*. 1996;110(3):710–7.
- 18 Budhiraja R, Tudor RM, Hassoun PM. Endothelial dysfunction in pulmonary hypertension. *Circulation*. 2004;109(2):159–65.
- 19 Christman BW, McPherson CD, Newman JH, King GA, Bernard GR, Groves BM, et al. An imbalance between the excretion of thromboxane and prostacyclin metabolites in pulmonary hypertension. *N Engl J Med*. 1992;327(2):70–5.
- 20 Lane KB, Machado RD, Pauculo MW, Thomson JR, Phillips JA 3rd, Loyd JE, et al. Heterozygous germline mutations in BMPR2, encoding a TGF-beta receptor, cause familial primary pulmonary hypertension. The International PPH Consortium. *Nat Genet*. 2000;26(1):81–4.
- 21 Newman JH, Wheeler L, Lane KB, Loyd E, Gaddipati R, Phillips JA, 3rd, et al. Mutation in the gene for bone morphogenetic protein receptor II as a cause of primary pulmonary hypertension in a large kindred. *N Engl J Med*. 2001;345(5):319–24.
- 22 Nohe A, Hassel S, Ehrlich M, Neubauer F, Sebald W, Henis YL, et al. The mode of bone morphogenetic protein (BMP) receptor oligomerization determines different BMP-2 signaling pathways. *J Biol Chem*. 2002;277(7):5330–8.
- 23 Yang X, Long L, Southwood M, Rudarakanchana N, Upton PD, Jefferey TK, et al. Dysfunctional Smad signalling contributes to abnormal smooth muscle cell proliferation in familial pulmonary arterial hypertension. *Circ Res*. 2005;96(10):1053–63.
- 24 Atkinson C, Stewart S, Upton PD, Machado R, Thomson JR, Trembath RC, et al. Primary pulmonary hypertension is associated with reduced pulmonary vascular expression of type II bone morphogenetic protein receptor. *Circulation*. 2002;105(14):1672–8.
- 25 Du L, Sullivan CC, Chu D, Cho AJ, Kido M, Wolf PL, et al. Signaling molecules in nonfamilial pulmonary hypertension. *N Engl J Med*. 2003;348(6):500–9.
- 26 Rondelet B, Kerbaul F, van Beneden R, Motte S, Fesler P, Hubloue I, et al. Signaling molecules in overcirculation-induced pulmonary hypertension in piglets: effects of sildenafil therapy. *Circulation*. 2004;110(15):2220–5.
- 27 Rondelet B, Kerbaul F, Motte S, van Beneden R, Rimmelink M, Brimiouille S, et al. Bosentan for the prevention of overcirculation-induced experimental pulmonary arterial hypertension. *Circulation*. 2003;107(9):1329–35.
- 28 Trembath RC, Thomson JR, Machado RD, Morgan NV, Atkinson C, Winship I, et al. Clinical and molecular genetic features of pulmonary hypertension in patients with hereditary hemorrhagic telangiectasia. *N Engl J Med*. 2001;345(5):325–34.
- 29 Abenhaim L, Moride Y, Brenot F, Rich S, Benichou J, Kurz X, et al. Appetite-suppressant drugs and the risk of primary pulmonary hypertension. International Primary Pulmonary Hypertension Study Group. *N Engl J Med*. 1996;335(9):609–16.
- 30 Marcos E, Fadel E, Sanchez O, Humbert M, Darteville P, Simonneau G, et al. Serotonin-induced smooth muscle hyperplasia in various forms of human pulmonary hypertension. *Circ Res*. 2004;94(9):1263–70.
- 31 Eddahibi S, Morrell N, d'Ortho MP, Naeije R, Adnot S. Pathobiology of pulmonary arterial hypertension. *Eur Respir J*. 2002;20(6):1559–72.
- 32 Mandegar M, Fung YC, Huang W, Remillard CV, Rubin LJ, Yuan JX. Cellular and molecular mechanisms of pulmonary vascular remodeling: role in the development of pulmonary hypertension. *Microvasc Res*. 2004;68(2):75–103.