

Clinical experiences with bisphosphonate-induced osteonecrosis of the jaws

A new entity for clinicians

C. Dannemann, K. W. Grätz, R. Zwahlen

Department of Cranio-Maxillofacial Surgery, University Hospital of Zurich, Switzerland

Summary

Question: Bisphosphonates are frequently used drugs in the adjuvant therapy of bone metastases and tumour-induced hypercalcaemia, but also for osteoporosis or Paget's disease. Several publications within the last three years considered osteonecrosis of the jaws to be connected with bisphosphonate therapy. Until today possible treatment strategies contain antibiotics, hyperbaric therapy and operative treatment. The tendency of healing however seems to be extremely poor. All clinicians should be aware of this new kind of side effect of bisphosphonate therapy.

Methods: 14 patients with this new kind of osteonecrosis were admitted to the department of Cranio-Maxillofacial Surgery of the University Hospital of Zurich. 8 men and 6 women all received bisphosphonates for cancer therapy. A complete analysis of patients' data was performed.

Results: Of 14 patients in 7 the underlying dis-

ease was multiple myeloma. In one patient it was prostate cancer and in all female patients it was breast cancer. All of them had prior dental treatment and showed inflammatory signs and bacterial colonisation with localisation in the upper or lower jaw or in both.

Conclusion: The infectious part of the bisphosphonate-induced osteonecrosis (ONJ) is considered to be more important than thought before. We presume that antimicrobial treatment is of utmost importance in the treatment of this kind of osteonecrosis. Patients with current or previous bisphosphonate therapy should be treated multidisciplinary to assure ideal prevention and treatment.

Key words: bisphosphonate; osteonecrosis of the jaws (ONJ); supportive cancer treatment prevention; multidisciplinary treatment

Introduction

In 2003 R. Marx presented 36 cases with a new kind of extremely therapy resistant osteonecrosis of the jaws. Because the only thing in common was bisphosphonate therapy, Marx concluded an association between this medication and the occurrence of osteonecrosis. [1] Until today many other authors have presented their series, as shown in table 1.

In April 2005 the "issue" osteonecrosis has been admitted to the general information of the worldwide most frequently intravenously administered bisphosphonates zoledronic acid (Zometa[®], Novartis Pharma GmbH, Basel) [2] and pamidronate (Aredia[®], Novartis Pharma GmbH, Basel) [3].

Bisphosphonates are a group of drugs, which have been discovered in the late 60s for treatment of diseases with undesirably high bone resorption rates, such as Paget's disease, tumour-induced

hypercalcaemia and treatment of bone metastases, for example in multiple myeloma, breast cancer or prostate cancer. In the last several years oral bisphosphonate preparations like alendronate (Fosamax[®]) have been frequently used for the treatment of osteoporosis.

Bisphosphonates bind to calcium ions in zones of high bone resorption, being integrated into the bone for up to 10 years. Partially they are internalised by pinocytosis or phagocytosis in cells like osteoclasts, osteoclast-precursors, but also in cells like macrophages, osteoblasts and chondroblasts. Once internalised they affect a multitude of biochemical processes resulting in a loss of osteoclasts' ability to resorb bone or even their apoptosis [4–7]. In addition antiangiogenic effects and direct interaction with tumour cells have been described [8] (figure 1).

As analogues of pyrophosphate, in which the

oxygen atom is substituted by a carbon group, they are highly resistant to enzymatic hydrolysis of the human body. Property variations can be achieved

by substituting side chains. The two structural main groups consist of amino-group containing and non-containing bisphosphonates. Amino-group containing bisphosphonates are up to 100–20 000 fold more potent than non-amino-containing bisphosphonates. Until now osteonecrosis of the jaws has only been described during treatment with amino-group-containing bisphosphonates.

As mentioned above, bisphosphonate therapy can be performed orally or intravenously, whereas the standard of care for treatment of tumour-induced hypercalcaemia and bone metastases is an intravenous administration of pamidronate or zoledronic acid. The therapeutic scheme for treatment of osteoporosis is an oral administration of alendronate.

A few cases of osteonecrosis of the jaws have yet been described after long term oral administration of alendronate (Fosamax®) due to osteoporosis, however, most cases occurred during intravenous therapy (table 2) [9].

Different factors characterise this special kind of osteonecrosis. All authors excluded the possibility that the lesion occurred as a bone metastasis [10]. Intraoperatively the lesion presented solid, without the typical appearance of chronic osteomyelitis including bony sequestration. In contrast to radioosteonecrosis there was no preference for the mandible. It appeared in both the mandible and the maxilla. Up to now there is a general consent that the occurrence of this osteonecrosis is correlated with a previous dental treatment. The lesions seemed to be extremely resistant to any kind of surgical and conservative treatment and patients sometimes suffered from strong pain or from hypaesthesia of the alveolar or infraorbital nerve (figure 2).

Table 1

Overview of presented cases with osteonecrosis of the jaw.

Author	year	number of cases
Wang [20]	2003	3
Marx [1]	2003	36
Schwarz [21]	2004	15
Ruggiero [9]	2004	63
Lugassy [22]	2004	3
Hoefert, Eufinger [23]	2005	7
Melo [24]	2005	1
Bagan [10]	2005	10
Schirmer [25]	2005	6
Migliorati [15]	2005	17

Figure 1

Chemical structure of bisphosphonates.

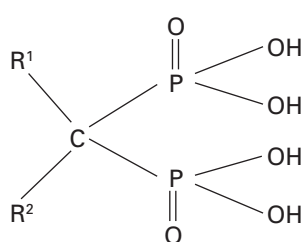


Figure 2

Bisphosphonate associated osteonecrosis of the jaw after inserting a new prosthesis.

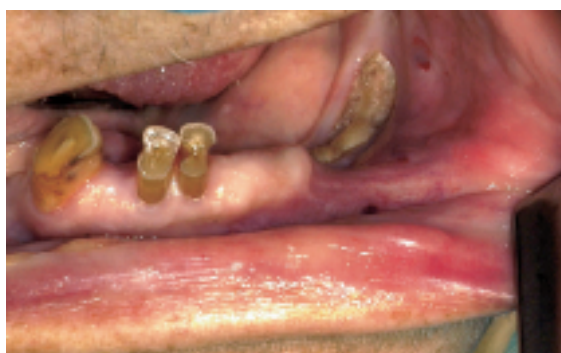

Table 2

Overview of frequently used Amino-bisphosphonates and application.

Agent	trade name	Indication	application
pamidronate	Aredia®	malign bone resorption	90 mg in an hour monthly (iv)
zoledronic acid	Zometa®	malign bone resorption	4 mg in 15 minutes monthly (iv)
Alendronat	Fosamax®	Osteoporosis	70 mg weekly (10 mg daily) orally

Patients and methods

In the department of Cranio-Maxillofacial Surgery of the University Hospital of Zurich 14 patients with bisphosphonate-induced osteonecrosis of the bone were treated within the last two years. 5 patients were referred by dentists, 4 patients by oral or maxillofacial surgeons, 3 patients by oncologists, 1 patient by a radiooncologist and 1 patient came autonomously. An analysis of data of 14 patients (8 male and 6 female patients) was performed. All of them

suffered from bone metastases and hypercalcaemia, for which they had been treated with an intravenous administration of bisphosphonate. Seven males suffered from multiple myeloma, one from prostate cancer and all females from breast cancer.

The following figure shows kind and distribution of primary disease (figure 3).

Figure 3

Distribution of primary disease of patients.



Results

The average age of the patients at the time of diagnosis of osteonecrosis was 65 years with a range from 37 years to 79 years. All patients received different chemotherapeutic agents and corticosteroids in their medical course. In 4 patients with multiple myeloma autologous stem cell transplantation was performed.

Table 3 shows a survey of disease, risk factors and the type of bisphosphonate therapy. The average duration of bisphosphonate therapy until occurrence of osteonecrosis was 38.7 months with a range from 12 to 71 months. In 5 patients bisphosphonate medication was stopped after occurrence

of lesions, whereas in 9 patients treatment was continued.

History of lesions: In all patients the osteonecrosis presented at the identical site where previously dental treatment was performed. In 10 patients dental extractions were performed, 3 patients received a new prosthesis and one patient underwent endodontic treatment. The average time of occurrence after dental treatment was 6.6 months (range 1 week to 36 months).

Clinical presentation: The most common finding was uncovered, necrotic bone presenting in thirteen patients. Eleven patients suffered from acute, strong pain or discomfort. Six patients presented hypaesthesia of the inferior alveolar nerve. Three patients had acute soft tissue abscesses at confinement whereas one more patient developed an abscess during osteonecrosis. Inflammatory signs could be found in all (figure 5).

Localisation of lesions: In nine patients the lesions occurred in the mandible, in two the lesions occurred in the maxilla, whereas in three patients they occurred both in the mandible and in the maxilla (figure 6).

Histopathological findings: The presence of bone

Figure 4

Previous dental treatment (n = 14 patients).

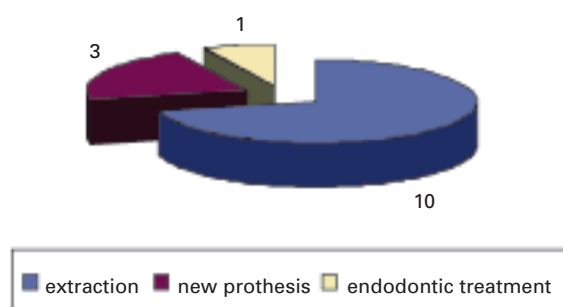


Figure 5

71-year-old patient presenting with acute soft tissue abscess as clinical presentation of bisphosphonate-induced osteonecrosis of the jaws.

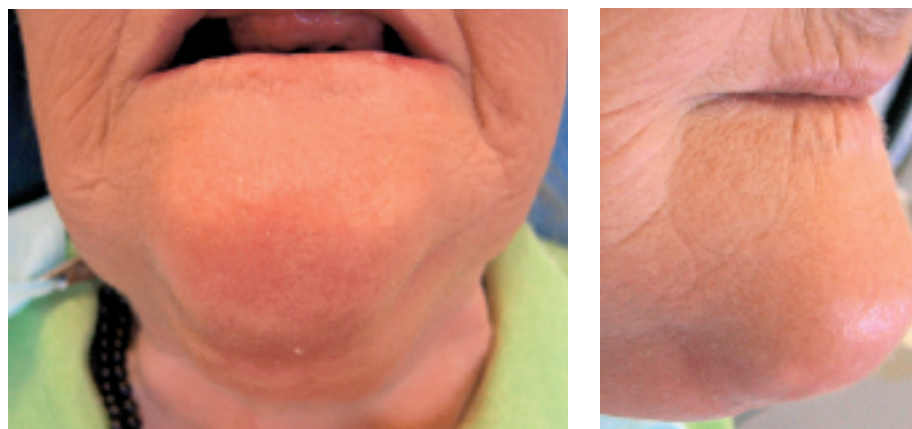

Table 3

Overview of underlying disease, risk factors and bisphosphonate therapy.

patient	underlying disease	nicotine	AST*	corticosteroids	bisphosphonate
H.W.	multiple myeloma	yes	yes	yes	A**/Z***
A.P.	multiple myeloma	n.s.	no	yes	A/Z
O.T.	multiple myeloma	n.s.	yes	yes	A/Z
W.K.	multiple myeloma	no	no	yes	Z
Z.A.	multiple myeloma	n.s.	no	yes	Z
V.K.	multiple myeloma	yes	yes	yes	A/Z
B.H.	prostate cancer	yes	no	yes	Z
M.E.	multiple myeloma	yes	yes	yes	Z/A
S.O.	breast cancer	no	no	no	Z
D.M.	breast cancer	no	no	no	A/Z
H.K.	breast cancer	no	no	yes	Z
M.T.	breast cancer	yes	no	n.s.	Z
A.V.	breast cancer	no	no	yes	Z
F.M.	breast cancer	yes	no	n.s.	Z

* AST = autologous stem cell transplantation ** A = Aredia® *** Z = Zometa®

Figure 6

Site of osteonecrotic lesion in our 14 patients.

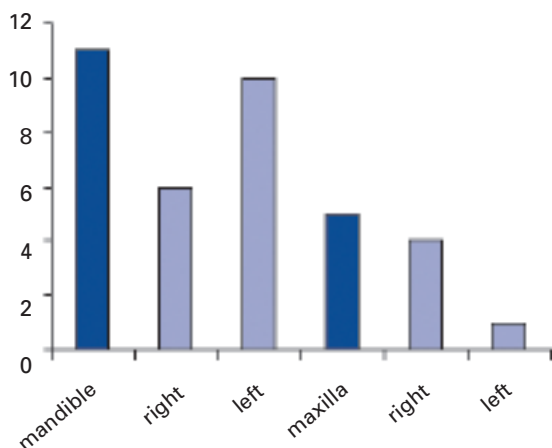


Table 4

Performed therapy and further course.

patient	therapy	medication	course
H.W.	decortication	antibiotics	partial resection mandible
A.P.	conservative	antibiotics	steady
O.T.	conservative	antibiotics	improvement
W.K.	decortication	antibiotics	steady
Z.A.	smooth bone	antibiotics	fistula
V.K.	smooth bone	antibiotics	steady
B.H.	smooth bone	antibiotics	complete remission
M.E.	incision, drainage	antibiotics	improvement
S.O.	conservative	antibiotics	steady
D.M.	decortication	antibiotics	steady
H.K.	decortication	antibiotics	improvement
M.T.	decortication	antibiotics	progressive
A.V.	incision, drainage	antibiotics	steady
F.M.	incision, drainage	antibiotics	partial resection mandible

metastases of the jaw has not been identified for any of our 14 patients. In necrotic bone fragments acute and chronic inflammatory changes with medullary fibrosis, plasma cell infiltration and colonisation with pathogens could be diagnosed histopathologically.

Microbiological findings: In six patients a complete microbiological examination was performed and fungus and bacterial colonisation with actinomyces, enterococcus, candida albicans, haemophilus influenza, α -haemolytic streptococci, lactobacillus, enterobacter and klebsiella pneumoniae was investigated.

Therapy strategy: Table 4 shows a survey of the administered surgical and conservative treatments.

Discussion

About 2 million people worldwide are treated with bisphosphonates as part of cancer therapy. Another huge number of patients is treated with bisphosphonates in oral application for osteoporosis. Exact data of osteonecrosis' occurrence as adverse event is still missing. In May 2005 Novartis reported in an official declaration 475 cases of bisphosphonate-induced osteonecrosis of the jaws worldwide including 14 cases in Switzerland [11]. This number, however, does not reflect reality, as since May 2005 14 patients have already been admitted to the Department of Cranio-Maxillofacial Surgery of the University of Zurich. In 2003 Tarasoff et al. reported that osteonecrosis of the jaws was approximately 4 times higher in a cancer population of whom many received bisphosphonate therapy. Whereas this finding does not indicate any obvious relationship between these two issues, all of our patients suffered from cancer [12]. But due to the fact that osteonecrosis of the jaw (ONJ) only occurs in the presence of osteoporosis therapy and not in its absence, ONJ has been finally accepted as adverse event of bisphosphonate ther-

apy [9, 11]. Another striking interesting factor was described by Hellenstein et al. who introduced the term "phossy jaw of the 21st century" [13]. They found parallels to the ONJ of match factory workers in the 19th century.

Until today it remains unclear whether osteonecrosis or infection of bisphosphonate-treated bone occurs first. Most authors described a bisphosphonate-induced necrotic bone with superinfection [1, 10, 14]. They discussed avascular necrosis of the bone and focused on antiangiogenic effects of bisphosphonates as causing agents [9, 15, 16].

Inflammatory signs and direct pathways for pathogens from the oral cavity into the bone could be found in all our patients by tooth extraction, new prosthesis or endodontic treatment. Sometimes a long time passed between dental treatment and appearance of necrotic bone, but the location was identical in all patients (figure 7).

The microbial investigation revealed pathogens of the physiological flora of the oral cavity as actinomyces, lactobacillus, candida glabrata and others causing aggressive infection in the bone and

surrounding soft tissue. These findings suggest that not bisphosphonates alone cause ONJ. With other synergistic factors such as microbial oral flora, they play a key-role in the pathogenesis of this new type ONJ in those delicate patients (figure 8).

Due to previous chemotherapy patients were immunocompromised, therefore more susceptible to infections. Bisphosphonate therapy induced loss of bone resorption and caused antiangiogenetic effects. Additionally an antiinflammatory effect of bisphosphonates has been described. They were shown to inhibit cytokine production and affect the monocyte-macrophage system [4, 7]. Loss of forearm bone density was reported after intravenous pamidronate therapy [17].

In his explanations of the bis-phossey jaw, Hel-lenstein mentioned a bacterial based component of the disease process of osteonecrosis among match factory workers in the 19th century [13]. He emphasised this factor as one of the big differences with osteoradionecrosis of the jaws [13, 18].

Treatment of the resulting necrotic bone

remains difficult. Marx considered palliation and osteomyelitis control to be of utmost importance in treating those lesions [1]. Ruggiero et al. reported that in surgical therapy of patients with widely exposed bone it was difficult to find surgical margins with vital, visibly bleeding bone. Therefore they recommended surgery only in symptomatic patients, whereas asymptomatic patients with limited areas of uncovered bone should be treated conservatively with irrigations and antibiotic therapy [9]. This is a treatment strategy confirmed by others as well.

There is a general agreement that prevention of osteonecrosis seems to be most auspicious. Prevention measures are:

- no invasive dental treatment during bisphosphonate therapy
- a screening examination and dental rehabilitation before starting the treatment with bisphosphonates, thereby preventing invasive dental treatment during the period of bisphosphonate therapy [12, 14, 19]

Figure 7
Clinical appearance of osteonecrosis dependent on prior dental treatment.

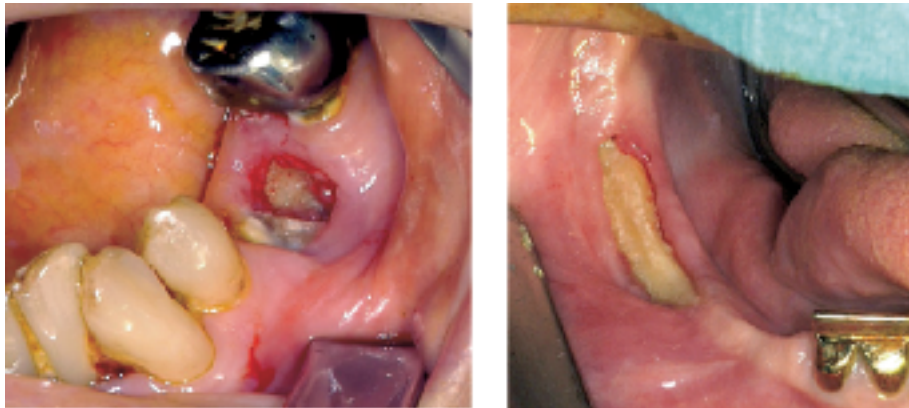


Figure 8
Schematic demonstration of accumulating factors for development of osteonecrosis.

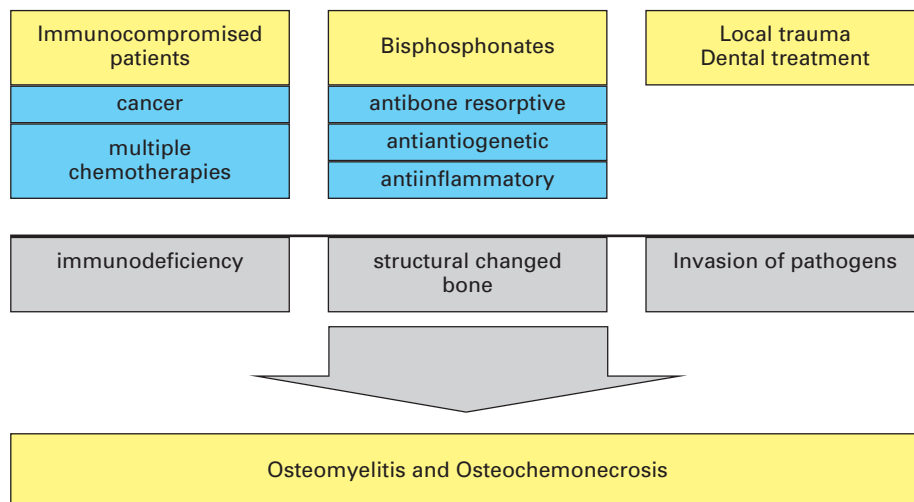
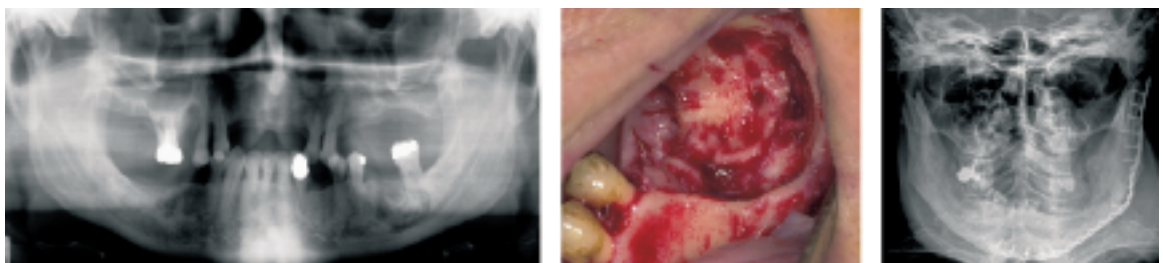


Figure 9
53-year-old patient with bisphosphonate-induced osteonecrosis after extraction 36 months prior to assignment.



Our findings confirm the prevention measures and treatment strategy mentioned above.

The 53-year-old patient with multiple myeloma was referred by his dentist 36 months after a dental extraction prior his first appointment. Acute osteomyelitis was diagnosed. Our treatment included several interventions such as sequestrectomy and decortication. As there was no improvement a partial resection of the mandible with visibly bleeding resection margins was performed (figure 9).

After resection the patient showed another infectious exacerbation of the soft tissue and still newly exposed necrotic bone. Actinomyces as causing pathogen was diagnosed. The patient was then treated with penicillin for 6 months and local antiinfectious compounds. The situation improved massively with intact oral mucosa and completely decreased symptoms.

In our opinion, as mentioned above, the infectious part of the affection could play a more serious role as supposed until now. We noticed that even after successful surgery in some patients, dehiscence of the bone occurred later on. However, after undergoing anti-bacterial therapy, including antibiotics and anti-bacterial rinsing, the patients became asymptomatic. Other patients were treated exclusively in a conservative manner, ie with antiinfectious measures, resulting in increasing lesions and no symptoms.

Antiinfectious treatment therefore seems to be

of utmost importance in patients suffering from ONJ. Antibiotic regimen should be performed according to the resistance in the antibiogram.

Additionally anti-bacterial rinsing is recommended as local treatment. If invasive dental treatment is necessary during bisphosphonate therapy, antiinfectious isolation and possibly antibiotic prophylaxis are recommended.

Osteonecrosis of the jaws during bisphosphonate therapy is an important, new complication of supportive cancer therapy or even therapy of osteoporosis. Clinicians, general practitioners, dentists, oral and maxillofacial surgeons, oncologists, rheumatologists and gynaecologists should be aware of this problem. Only a close teamwork among the disciplines can guarantee optimal prevention and therapy for the patients prior or during intravenous bisphosphonate therapy. We propose an interdisciplinary approach to obtain further information about pathogenesis and effective treatment strategies, thereby optimising the understanding of this new ONJ.

Correspondence:

Christine Dannemann

Department of Cranio-Maxillofacial Surgery

University Hospital Zurich

Rämistrasse 100

CH-8126 Zürich

E-Mail: christine.dannemann@usz.ch

References

- Marx R. Pamidronate (Aredia) and Zoledronate (Zometa) induced avascular necrosis of the jaws: a growing epidemic. *J Oral Maxillofac Surg* 2003;61:1115-8.
- Pharma N. Zometa - Fachinformation des Arzneimittelkompendium Schweiz In: Pharma N, ed. *Arzneimittelkompendium Schweiz*. Basel: Documed AG, 2005.
- Pharma N. Aredia - Fachinformation des Arzneimittelkompendium Schweiz In: Ag D, ed. *Arzneimittel Kompendium*. Basel: Documed AG, 2005.
- Rogers MJ WD, Russel RGG. Overview of bisphosphonates. *Cancer* 1997;80:1652-60.
- Hughes DE WK, Uy HL, Sasaki A, Yoneda T, Roodman GD. Bisphosphonates promote apoptosis in murine osteoclasts in vitro and vivo. *J Bone Miner Res* 1995;10.
- Carano A TS, Konsek JD, Schlesinger PH, Blair HC. Bisphosphonates directly inhibit the bone resorption activity of isolated avian osteoclasts in vitro. *J Clin Invest* 1990;85:456-61.
- Bartl R. Bisphosphonate. *Manual Supportive Massnahmen und symptomorientierte Therapie*. München, 2001;184-90.
- Van der Pluijm G VH, van Beek E, et al. Bisphosphonates inhibit the adhesion of breast cancer cells to bone matrices in vitro. *J Clin Invest* 1996;98:698-705.
- Ruggiero SL, Mehrotra B, Rosenberg TJ, Engroff SL. Osteonecrosis of the jaws associated with the use of bisphosphonates: a review of 63 cases. *J Oral Maxillofac Surg* 2004;62:527-34.
- Bagan JV, Murillo J, Jimenez Y, Poveda R, Milian MA, Sanchis JM, et al. Avascular jaw osteonecrosis in association with cancer chemotherapy: series of 10 cases. [Review] [17 refs]. *J Oral Pathol Med* 2005;34:120-3.
- Novartis Pharma S. Bisphosphonate und Osteonekrosen des Kiefers. 2005.
- Tarassof P CK, Novartis Pharma. Avascular necrosis of the jaws: risk factors in metastatic cancer patients. *J Oral Maxillofac Surg* 2003;61:1238-9.
- Hellstein JW, Marek CL. Bisphosphonate osteonecrosis (bis-phossy jaw): is this phossy jaw of the 21st century? [Review] [59 refs]. *J Oral Maxillofac Surg* 2005;63:682-9.
- Migliorati C. Bisphosphonates and oral cavity avascular bone necrosis. *J Clin Oncol* 2003;21:4253-4.
- Migliorati C SM, Douglas E, Seneda L. Bisphosphonate-associated osteonecrosis of mandibular and maxillary bone. An emerging oral complication of supportive cancer therapy. *Am Cancer Soc* 2005;104:83-93.
- Assael LA. New foundations in understanding osteonecrosis of the jaws. *J Oral Maxillofac Surg* 2004;62:125.
- Gutteridge DH RR, Ward LC, et al. Bone density changes in Paget's disease 2 years after i.v. pamidronate sustained increases in pagetic bone with severity-related loss in forearm nonpagetic cortical bone. *Bone* 2003;32:50.
- Thoma KH. *Oral Pathology*. 4th ed. St Louis, 1954.
- Greenberg M. Intravenous bisphosphonates and osteonecrosis [see comment]. *Oral Surg Oral Med Oral Pathol Oral Radiol Endodontics* 2004;98:259-60.
- Wang J GN, Pogrel MA. Osteonecrosis of the jaws associated with cancer chemotherapy. *J Oral Maxillofac Surg* 2003;61:1104-7.
- Schwartz HC. Osteonecrosis and bisphosphonates: correlation versus causation (comment). *J Oral Maxillofac Surg* 2004;62:763-4.
- Lugassey G, S Rea. Severe osteomyelitis of the jaw in long term survivors of multiple myeloma: a new clinical entity. *Am J Med* 2004;117:440-1.
- Hoefert S EH. Kieferknochennekrosen als mögliche unerwünschte Wirkung von Bisphosphonaten. *Mund Kiefer Gesichtschirurgie* 2005;9:233-8.
- Melo M OG. Osteonecrosis of the Maxilla in a patient with a history of bisphosphonate therapy. *J Canadian Dental Association* 2005;71:111-3a.
- Schirmer I PH, Reichart PA, Dürkop H. Bisphosphonate und Osteonekrosen im Kieferbereich. *Mund Kiefer Gesichtschirurgie* 2005;9:239-45.

The many reasons why you should choose SMW to publish your research

What Swiss Medical Weekly has to offer:

- SMW's impact factor has been steadily rising, to the current 1.537
- Open access to the publication via the Internet, therefore wide audience and impact
- Rapid listing in Medline
- LinkOut-button from PubMed with link to the full text website <http://www.smw.ch> (direct link from each SMW record in PubMed)
- No-nonsense submission – you submit a single copy of your manuscript by e-mail attachment
- Peer review based on a broad spectrum of international academic referees
- Assistance of our professional statistician for every article with statistical analyses
- Fast peer review, by e-mail exchange with the referees
- Prompt decisions based on weekly conferences of the Editorial Board
- Prompt notification on the status of your manuscript by e-mail
- Professional English copy editing
- No page charges and attractive colour offprints at no extra cost

Editorial Board

Prof. Jean-Michel Dayer, Geneva
 Prof. Peter Gehr, Berne
 Prof. André P. Perruchoud, Basel
 Prof. Andreas Schaffner, Zurich
 (Editor in chief)
 Prof. Werner Straub, Berne
 Prof. Ludwig von Segesser, Lausanne

International Advisory Committee

Prof. K. E. Juhani Airaksinen, Turku, Finland
 Prof. Anthony Bayes de Luna, Barcelona, Spain
 Prof. Hubert E. Blum, Freiburg, Germany
 Prof. Walter E. Haefeli, Heidelberg, Germany
 Prof. Nino Kuenzli, Los Angeles, USA
 Prof. René Lutter, Amsterdam,
 The Netherlands
 Prof. Claude Martin, Marseille, France
 Prof. Josef Patsch, Innsbruck, Austria
 Prof. Luigi Tavazzi, Pavia, Italy

We evaluate manuscripts of broad clinical interest from all specialities, including experimental medicine and clinical investigation.

We look forward to receiving your paper!

Guidelines for authors:

http://www.smw.ch/set_authors.html

Impact factor Swiss Medical Weekly



All manuscripts should be sent in electronic form, to:

EMH Swiss Medical Publishers Ltd.
 SMW Editorial Secretariat
 Farnsburgerstrasse 8
 CH-4132 Muttenz

Manuscripts: submission@smw.ch
 Letters to the editor: letters@smw.ch
 Editorial Board: red@smw.ch
 Internet: <http://www.smw.ch>