

Peer reviewed article

Aseptic meningitis, venous sinus thrombosis, intracranial hypertension and callosal involvement contemporaneously in a young patient with Behçet's disease

Levent Sinan Bir^a, Nuran Sabir^b,
Ahmet Kılınçer^a, Arif Çeliker^a,
Berna Şanlı Erdoğan^c

^a Pamukkale University Medical Faculty,
Departments of Neurology,

^b Radiology,

^c Dermatology, Denizli, Turkey

Behçet's disease is a multisystemic inflammatory disorder [1]. Parenchymal (65–81%) and vascular (19–27.5%) forms were defined for neurological involvement [1, 2]. Sinus thrombosis and intracranial hypertension are the most common examples of the vascular form [1]. It is very uncommon that these two forms of the disease occur in the same individual [1]. In this report we present a case with neuro-Behçet's disease (n-BD) that had signs of both clinical forms contemporaneously including aseptic meningitis,

venous sinus thrombosis, intracranial hypertension and a callosal lesion.

A 27-year-old male patient presented with headache, papilloedema and neck stiffness. In cranial MRI, superior sagittal sinus thrombosis, prominent meningeal contrast enhancement (figure 1) and a lesion of 1 cm in diameter located in the splenium of the corpus callosum enhancing with gadolinium on T1W and hyperintense on T2W (figure 2a) were seen. CSF pressure was measured as 600 cmH₂O; a high lymphocyte count and an increased level of protein were detected. A ten year history of recurrent oral aphthous, genital ulcerations and positive pathergy test directed to Behçet's disease. Methylprednisolone, azathioprine, acetazolamide were used. Symptoms and signs resolved completely in one year. Follow up MRI revealed complete recanalisation of the thrombosis and disappearance of the callosal lesion (figure 2b).

This case shows that major clinical forms can be seen in the same patient synchronically in n-BD. Isolated hyperintense white matter lesion located in the splenium of the corpus callosum is another interesting point of the case. In the literature only one n-BD case with similar callosal involvement was found [3]. We saw reversible callosal lesions in multiple sclerosis and its variants and but in this patient a detailed history and CSF immunological analysis were not consistent with neither of them.

Correspondence:

Dr. Levent Sinan Bir
Pamukkale Üniversitesi Tıp Fakültesi
Hastanesi
Nöroloji Anabilim Dalı Kat 1
B105Kımkılı
20070 Denizli Turkey
E-Mail: sbir@pamukkale.edu.tr

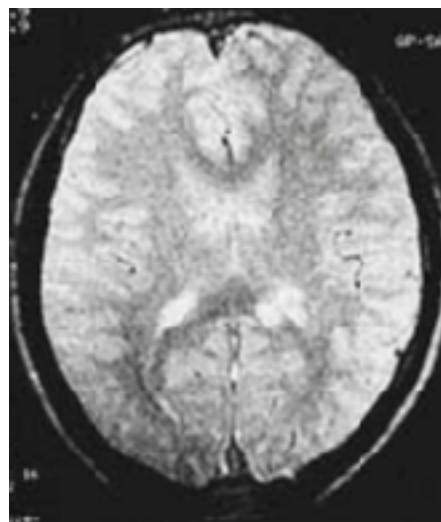
References

- 1 Akman-Demir G, Serdaroglu P, Tasçi B and the Neurobehçet Study Group. Clinical patterns of neurological involvement in Behçet's disease: evaluation of 200 patients. *Brain* 1999;122:2171–81.
- 2 Al-Fahad SA, Al-Araji AH. Neuro-Behçet's disease in Iraq: a study of 40 patients. *J Neurol Sci* 1999; 170:105–11.
- 3 Lackmann GM, Lyding S, Scherer A, Niehues T. Acute Disseminated Encephalomyelitis and Mucocutaneous Ulcerations. *Neuropediatrics* 2004; 35:253–4.

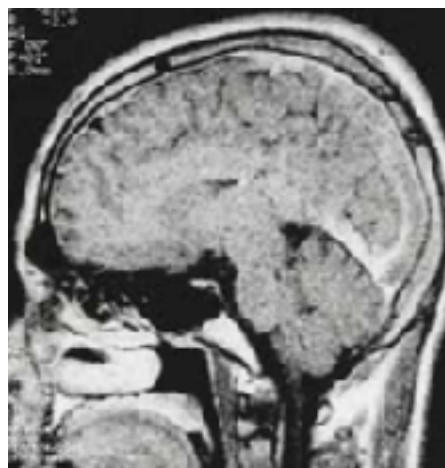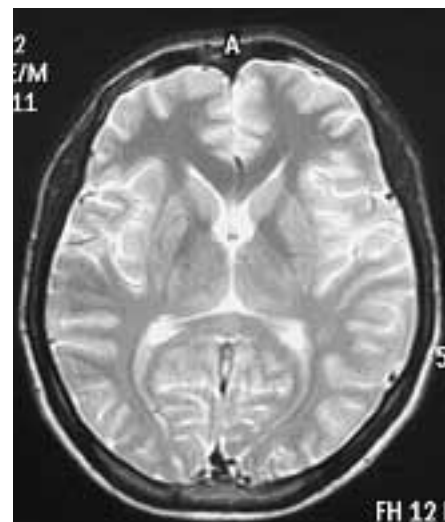


Figure 1

T1 SE post-contrast image shows the contrast enhancement of meninges and sagittal sinus thrombosis.



a



b

Figure 2

a. Callosal lesion in T2 SE axial image.
b. Follow-up MRI shows disappearance of the lesion.

The many reasons why you should choose SMW to publish your research

What Swiss Medical Weekly has to offer:

- SMW's impact factor has been steadily rising, to the current 1.537
- Open access to the publication via the Internet, therefore wide audience and impact
- Rapid listing in Medline
- LinkOut-button from PubMed with link to the full text website <http://www.smw.ch> (direct link from each SMW record in PubMed)
- No-nonsense submission – you submit a single copy of your manuscript by e-mail attachment
- Peer review based on a broad spectrum of international academic referees
- Assistance of our professional statistician for every article with statistical analyses
- Fast peer review, by e-mail exchange with the referees
- Prompt decisions based on weekly conferences of the Editorial Board
- Prompt notification on the status of your manuscript by e-mail
- Professional English copy editing
- No page charges and attractive colour offprints at no extra cost

Editorial Board

Prof. Jean-Michel Dayer, Geneva
 Prof. Peter Gehr, Berne
 Prof. André P. Perruchoud, Basel
 Prof. Andreas Schaffner, Zurich
 (Editor in chief)
 Prof. Werner Straub, Berne
 Prof. Ludwig von Segesser, Lausanne

International Advisory Committee

Prof. K. E. Juhani Airaksinen, Turku, Finland
 Prof. Anthony Bayes de Luna, Barcelona, Spain
 Prof. Hubert E. Blum, Freiburg, Germany
 Prof. Walter E. Haefeli, Heidelberg, Germany
 Prof. Nino Kuenzli, Los Angeles, USA
 Prof. René Lutter, Amsterdam, The Netherlands
 Prof. Claude Martin, Marseille, France
 Prof. Josef Patsch, Innsbruck, Austria
 Prof. Luigi Tavazzi, Pavia, Italy

We evaluate manuscripts of broad clinical interest from all specialities, including experimental medicine and clinical investigation.

We look forward to receiving your paper!

Guidelines for authors:

http://www.smw.ch/set_authors.html

Impact factor Swiss Medical Weekly



All manuscripts should be sent in electronic form, to:

EMH Swiss Medical Publishers Ltd.
 SMW Editorial Secretariat
 Farnsburgerstrasse 8
 CH-4132 Muttenz

Manuscripts: submission@smw.ch
 Letters to the editor: letters@smw.ch
 Editorial Board: red@smw.ch
 Internet: <http://www.smw.ch>