

Ebstein's anomaly – review of a multifaceted congenital cardiac condition

C. H. Attenhofer Jost^a, H. M. Connolly, W. D. Edwards^b, D. Hayes, Carole A. Warnes, G. K. Danielson^c

^a From the Cardio Vascular Center Zurich, Zurich, Switzerland

^b Cardiovascular Division, Division of Anatomical Pathology, the Mayo Clinic, Rochester MN, USA

^c Division of Cardiovascular Surgery, the Mayo Clinic, Rochester MN, USA

Summary

Ebstein's anomaly (EA) is a rare but fascinating congenital heart disorder accounting for <1% of all congenital heart defects. Since its description in 1866, dramatic advances in diagnosis and therapy have been made. In this review, we describe current diagnostic criteria and classification, natural history, clinical features, and prognosis, typical echocardiographic features and pathologic findings, and the spectrum of associated cardiac malformations including left heart anomalies associated with EA. Differences between Ebstein-like changes associated with congenitally corrected transposition and EA are described. The spectrum of typical ECG and conduction system changes, arrhythmias including accessory pathways and ectopic atrial tachycardias related to EA are also reviewed. Differential diagnosis of EA is discussed including tricuspid valve dysplasia and prolapse as

well as arrhythmogenic right ventricular cardiomyopathy. The review describes management options in EA including catheter interventions, indication for operation and surgical options including tricuspid valve repair and replacement.

Overall, EA is a complex congenital anomaly with a broad pathologic-anatomical and clinical spectrum and no two patients are alike. Therefore, precise knowledge of the different anatomic and hemodynamic variables, associated malformations and management options are essential. Management of EA patients is complex. Thus it is important that these patients are regularly seen by a cardiologist with expertise in congenital heart disease.

Key words: Ebstein's anomaly; tricuspid valve repair; diagnosis; echocardiography; arrhythmias; surgery

Introduction

Ebstein's anomaly (EA) is a rare but fascinating congenital heart disorder which occurs in about 1–5 per 200,000 live births, accounting for <1% of all congenital heart disease [1–3]. This anomaly is currently most easily diagnosed by echocardiography. In the past, diagnosis was estab-

lished most commonly at autopsy. By 1950 only three cases of EA had been published in the first volume of *Circulation* [4]. Since then EA has been increasingly recognised but its ideal management still poses problems for attending cardiologists. In this review we summarise the current data on EA.

Historical background

Wilhelm Ebstein (see figure 1) was born in Prussia in 1836 and graduated with a medical degree from Berlin in 1859 [5, 6]. He published on obesity, metabolic disease and the gastrointestinal system, but his fame stems from an article on congenital heart disease. In 1866 Ebstein described the first case of a malformation of the tricuspid valve, entitled "Concerning a very rare case of insufficiency of the tricuspid valve caused by a congenital malformation". The patient was a 19-year-old man with a long history of dyspnoea and pal-

pitations [5, 6]. Prior to his death he was extremely cyanotic, with marked jugular venous pulsations synchronous with the heart beat, cardiomegaly and a systolic murmur extending into diastole. At autopsy Ebstein described an enlarged and fenestrated anterior tricuspid leaflet; the posterior and septal leaflets were hypoplastic, thickened and adherent to the right ventricle, there was a thinned and dilated atrialised portion of the right ventricle, an enlarged right atrium and a patent foramen ovale [7]. A figure from the original article is shown



Figure 1

A pencil sketch of Wilhelm Ebstein published in the *Festschrift* celebrating Ebstein's 70th birthday. Published by permission of the Mayo Clinic Proceedings, where it was published by Mann RJ, Lie JT. The life story of Wilhelm Ebstein (1836–1912) and his almost overlooked description of a congenital heart disease. *Mayo Clin Proc* 1979;54:197–204.

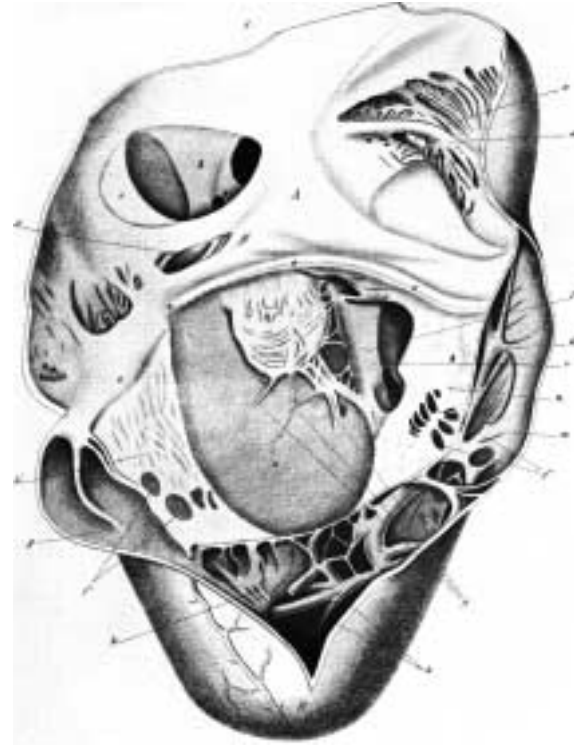


Figure 2

First figure of Ebstein's original case report. This figure shows right atrium and right ventricle opened along right border beginning at the superior vena cava. A = right atrium; B = right ventricle; b = valve not quite closing the foramen ovale, i = rudimentary septal leaflet of tricuspid valve with its chordae tendineae inserting on endocardium of ventricular septum; r = opening giving access to right conus arteriosus and, in the opposite direction, to the sac formed by membrane h, h' and posterior part of endocardium of ventricular septum o. For complete figure legend see original article.

Published by permission of the Mayo Clinic Proceedings, where it was published by Mann RJ, Lie JT. The life story of Wilhelm Ebstein (1836–1912) and his almost overlooked description of a congenital heart disease. *Mayo Clin Proc* 1979;54:197–204.

as figure 2. This report was almost overlooked and not quoted in the English language literature until 1900 [6]. Ebstein's original paper was translated into English in 1968 [8]. EA was first diagnosed in a patient during life around 1950 [9].

Embryology and genetics

The embryonic events leading to EA are not clearly defined. The leaflets of the tricuspid valve develop equally from the endocardial cushion tissues and the myocardium [10]. Some of the spectrum of EA is reminiscent of the developing tricuspid valve during week 8 of development. The leaflets and tensile apparatus of the atrioventricular valves seem to be formed by a process of delamination of the inner layers of the inlet zone of the ventricles. In EA, delamination of these leaflets may have failed to occur due to an incompletely understood mechanism [11].

There are heterogeneous genetic factors in EA. Most cases are sporadic; familial EA is rare. Sometimes EA has been observed in familial clus-

tering of congenital heart disease. In Labrador retriever kindreds a tricuspid valve malformation resembling EA has been mapped to chromosome 9 [12]. A genetic study of 26 families with EA has been performed [13] in which 93 of 120 first degree relatives were investigated. No case of EA was found, but 2 first degree relatives had ventricular septal defects and another, who died at 7 months, was said to have congenital heart disease. In distant relatives there were 2 with ventricular septal defects and 2 with Fallot's tetralogy.

Maternal lithium therapy may in rare cases lead to Ebstein's anomaly of the offspring [14]. Other environmental factors such as viral infections are in rare cases a cause of Ebstein's anomaly.

Pathological features

EA occurs in about 2.5% of autopsy series in patients with congenital heart disease, males and females being affected equally [15, 16].

EA is a malformation of the tricuspid valve and right ventricle marked by a spectrum of several features which include: 1) adherence of the tricuspid valve leaflets to the underlying myocardium (failure of delamination); 2) downward (apical) displacement of the functional annulus (septal>posterior>anterior); 3) dilation of the “atrialised” portion of the right ventricle with variable degrees of hypertrophy and thinning of the wall; 4) redundancy, fenestrations, and tethering of the anterior leaflet; and 5) dilation of the right atrioventricular junction (true tricuspid annulus) [16–18]. In the normal heart there are three tricuspid valve leaflets which are called “anterior, posterior and septal” or “anterosuperior, inferior and medial (septal)” [3, 10]. Typical of EA is apical displacement of the hinge point of the valve from the atrioventricular ring (septal>posterior>anterior leaflet, see figure 3) [3, 11, 19, 20]. In the echocardiographic image this distance is measured from the point of insertion of the anterior mitral valve leaflet to the point of insertion of the septal tricuspid valve leaflet. The anterior leaflet is not usually displaced. The point of maximum displacement is the commissure between the posterior and septal leaflets [11]. Even in normal human hearts there is some downward displacement of the septal and posterior tricuspid leaflets relative to the anterior mitral leaflet but always < 0.8 cm/m² body surface area [16]. In EA the spectrum of the malformation may range from only minimal displacement of the septal and posterior leaflets up to an imperforate membrane or muscular shelf between the inlet and trabecular zones of the right ventricle. The anterior tricuspid leaflet is the most likely to have some degree of delamination; it may be severely deformed, so that the only mobile leaflet tissue is displaced into the right ventricular outflow tract or, in less severe cases, it forms a large sail-like intracavitary curtain. The anterior leaflet may contain not only a true orifice but also several accessory orifices [16]. The chordae tendineae to the anterior leaflet are generally short and poorly formed (see figure 4).

In EA, the right ventricle is divided into 2 parts: the inlet portion is functionally integrated with the right atrium (atrialised right ventricle), and the other, trabecular and outlet portions, constitute the functional right ventricle.

This anomaly results in variable but often marked dilatation of the true tricuspid annulus and the presence of a large chamber separating the true tricuspid annulus from the functional right ventricle (atrialised portion of the right ventricle) as shown in figure 4 [3]. The true anatomical tricuspid annulus is not displaced; however, it is less well defined than in a normal heart [16]. Other features include tricuspid valve dysplasia with adherence

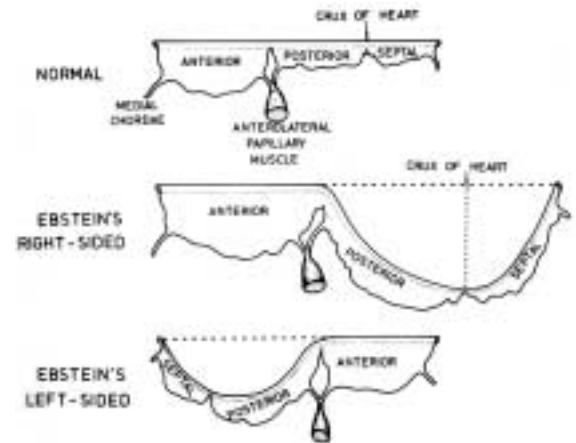


Figure 3

Diagram of the tricuspid valve in a normal person, in right-sided Ebstein's and left-sided Ebstein's. The top diagram shows the normal tricuspid valve with the anterior, posterior and septal leaflet in one plane. Right-sided Ebstein's is then shown with displacement of the posterior and septal leaflet, the maximum displacement being at the crux of the posterior and septal leaflet. In left-sided Ebstein's (bottom) the displacement is similar, as shown below. Figure reproduced by permission of the Mayo Clinic Proceedings (Anderson KR, Zuberbuhler JR, Anderson RH, Becker AE, Lie JT. Morphologic spectrum of Ebstein's anomaly of the heart. *Mayo Clin Proc* 1979;54:174–280.)

of the tricuspid leaflets to the underlying myocardium (failure of delamination), redundancy, fenestrations (accessory orifices), tethering of the anterior leaflet, right ventricular dysplasia and abnormalities of the distal attachments of the tricuspid valve [4]. The dysplastic tricuspid valve may be incompetent and/or stenotic.

Two thirds of hearts with EA exhibit dilated right ventricles. Dilatation often involves not only the atrialised right ventricle but also the functional right ventricle and infundibulum. In some cases, right ventricular dilatation is so marked that the ventricular septum bulges leftward, compressing the left ventricular chamber [16]. In severe cases the inferior wall of the right ventricle may consist solely of thin fibrous tissue resembling a post-infarction aneurysm [16]. A study by Celermajer [21] comparing the hearts of six neonates with severe EA showed that there was significant thinning of the right ventricular free wall distal to the tricuspid valve.

A study by Zuberbuhler et al. analysed 14 EA hearts at autopsy [20]. There was wide variability in the communication between inlet and trabecular portions of the right ventricle, which could be between the papillary muscles, through a pinhole or foramen. In two cases the anterior tricuspid valve leaflet was imperforate, with no communication [20]. The septal tricuspid valve leaflet may be slightly dysplastic, rudimentary, or have the appearance of cauliflower excrescences. The anterior leaflet may be normally formed or display a sail-like structure with variable adhesions.

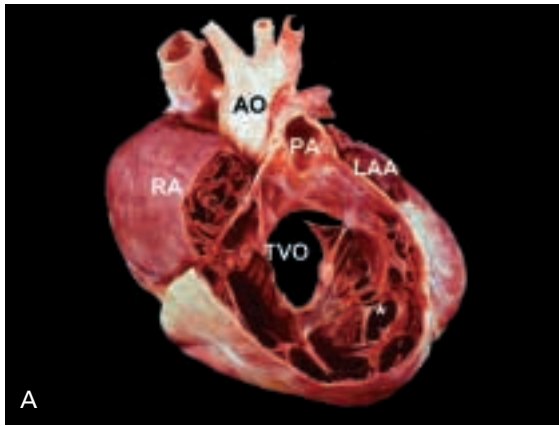
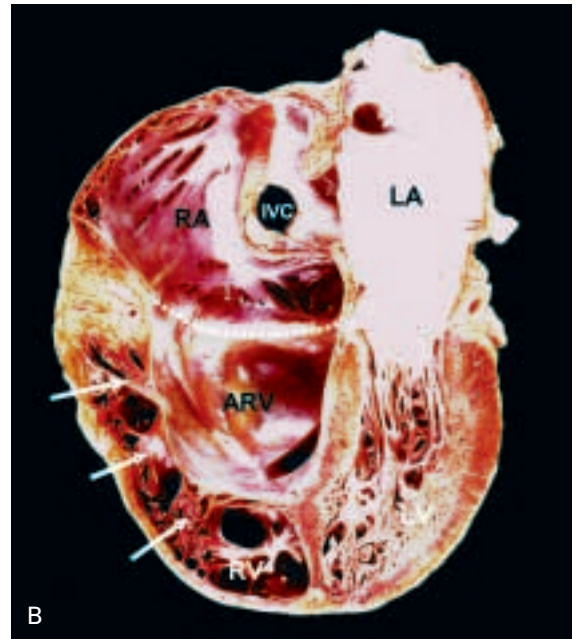


Figure 4

Ebstein's anomaly as seen at autopsy.

A: Example of the tricuspid valve anatomy in Ebstein's anomaly as seen at autopsy. In this example the superior aspect of the right ventricular outflow tract has been removed. The anterior leaflet is redundant and tethered to the right ventricle by numerous abnormal attachments. The tricuspid valve orifice (TVO) is directed superiorly and a fenestration (asterisk) provides an additional cause for tricuspid regurgitation. The right atrium (RA) is dilated. AO = aorta, PA = pulmonary artery; LAA = left atrial appendage.

B: Ebstein's anomaly with severe tricuspid regurgitation. Inferior half of a specimen with severe EA dissected in four-chamber format. The posterior leaflet forms an intra-ventricular muscular shelf arrowhead that delineates the atrialised portion of the right ventricle (ARV) and is attached to the free wall by numerous large muscular stumps (white arrows). The shape of the ventricular septum (VS) is distorted by displaced septal leaflet. Marked dilatation involves the right atrium (RA), right ventricle (RV) and true tricuspid annulus (dashed line). LA = left atrium; IVC = inferior vena cava; ARV = atrialised right ventricle; LV = left ventricle.



Classification of Ebstein's anomaly

In 1988, Carpentier proposed the following classification for EA [22]: type A: the volume of the true right ventricle is adequate; type B, there is a large atrialised component of the right ventricle but the anterior leaflet moves freely; type C, the anterior leaflet is severely restricted in its movement and may cause significant obstruction of the right ventricular outflow tract; and type D, almost complete atrialisation of the ventricle with the exception of a small infundibular component. This classification is not currently used at our institution, because in actual cases there may be little correlation between the degrees of severity of the various components of the anomaly listed in this classification (degree of leaflet tethering, degree of apical displacement, degree of dilatation of the atrialised right ventricle etc) [3].

Later, Celermajer et al. described an echocardiographic grading score for neonates with EA, GOSE (= Glasgow Outcome Score Extended) Score Grade 1–4 [23]. For this score the ratio of the combined area of the right atrium and atrialised right ventricle to that of the functional right

ventricle and left heart in a four-chamber view at end-diastole was calculated (ratio <0.5, grade 1; ratio 0.5–0.99, grade 2; ratio 1.0–1.49, grade 3; and if ratio ≥ 1.5 , grade 4).

We have employed two approaches in describing the severity of the anatomical deformity of hearts with EA. The first is based on the echocardiographic image, in which the pathology is described as anatomically mild, moderate, or severe, as derived from an impression formed by summation of the amount of displacement of the leaflets, the degree of tethering of the anterior leaflet, and the degree of right ventricular dilatation. This classification, which resembles others, is imprecise and subjective but has the advantage of simplicity. Our second approach is to describe the exact anatomy of each of the Ebstein heart structures involved, as visualised at operation and recorded in the operative note. A detailed nomenclature is then employed which emphasises the features that surgeons have found to be important when considering valve repair versus valve replacement [3].

Associated cardiac malformations

In addition to right-sided abnormalities of the heart, abnormalities of left ventricular function and morphology as well as other left heart lesions have been documented, as shown in table 1 [17–19, 24–27].

Angiographic analysis of the left ventricle in 26 patients with EA showed that in 12 of them left ventricular end-diastolic volume was increased $>80 \text{ ml/m}^2$ body surface area, while the left ventricular ejection fraction was decreased in 8 but

Table 1

Summary of associated heart lesions in Ebstein's anomaly.

	reported abnormality	prevalence
Aortic valve	bicuspid	occasional
	atresia	rare
Aorta	coarctation	rare
	hypoplasia	extremely rare
	subaortic stenosis	rare
Mitral valve	prolapse	frequent
	cleft	extremely rare
	parachute	extremely rare
	additional chordae	occasional
	accessory tissue	occasional
	double orifice mitral valve	extremely rare
	dysplasia	rare
	supravalvular ring	extremely rare
Pulmonary veins	stenosis of individual veins	extremely rare
	cor triatriatum	extremely rare
	partial or total anomalous pulmonary venous connection	extremely rare
Left ventricular myocardium	noncompaction	frequent
	endomyocardial fibroelastosis	rare
	hypertrophic cardiomyopathy	rare
	abnormal papillary muscle	rare
	abnormal muscle bands	occasional
Ventricular septal defect	muscular	occasional
	perimembranous	occasional
Pulmonary valve/artery	hypoplastic pulmonary artery	occasionally
	pulmonary atresia	extremely rare
	pulmonary stenosis	occasional
Atrioventricular septal defect	complete, partial	extremely rare

never in patients with reduced left ventricular cavities [24]. Sixteen patients had an abnormal pattern of left ventricular contraction.

We recently reported on 3 patients with EA who had left ventricular echocardiographic features resembling noncompaction [28]. We subsequently analysed 106 consecutive patients with EA and found left heart abnormalities including abnormal valves, myocardial dysplasia, or a ventricular septal defect in 39%. 18% of the patients had left ventricular dysplasia resembling noncompaction. Left ventricular systolic dysfunction occurred in 7 patients [29].

Overall, an interatrial communication is present in 80–94% of patients with EA [2, 30]. In an autopsy study of 15 EA cases, 5 had a perimembranous or muscular VSD, 13 had an atrial septal de-

fect, 2 had a patent ductus arteriosus, and one case each had pulmonary atresia, patent foramen, coarctation or persistent left superior vena cava [20].

Complex EA includes patients with pulmonary stenosis or pulmonary atresia, ventricular septal defect, mitral stenosis and in rare cases tetralogy of Fallot [27].

Bilateral Ebstein's has been described [31, 32]. In one patient with bilateral EA, the mural leaflet of the mitral valve was diffusely adherent to the left ventricular wall, with the anterior mitral leaflet plastered against the septal wall, producing an atrialised area and restricting the subaortic outflow tract. Hypoplasia of the ascending aorta was also present [32].

Ebstein's anomaly in congenitally corrected transposition of the great arteries

Corrected transposition of the great arteries is rare, occurring in 0.6–1.4% of patients with congenital heart disease. Most patients with congenitally corrected transposition of the great arteries have an abnormal systemic tricuspid valve, thus

fulfilling the EA criteria in 15–50% of patients [11, 33–35]. It is unclear whether the fundamental nature of EA is identical in concordant and discordant atrioventricular connections [36, 37]. Pathoanatomically, left-sided EA differs from

right-sided EA in the following criteria: the atrioventricular sulcus circumference is not increased; the anterior leaflet of the valve is anatomically different and smaller, with a cleft in 30% of cases; and the anterior leaflet may interfere with the ventricular outflow and the ventricular cavity [37]. In addition, the morphologically right ventricle is rarely

dilated in young patients [17, 18]. In an autopsy study of 14 patients with corrected transposition of the great arteries, the atrialised portion of the morphologically right ventricle was, contrary to hearts with EA and concordant atrioventricular connections, thinned and dilated in only 1 case [36].

Echocardiographic features of Ebstein's anomaly

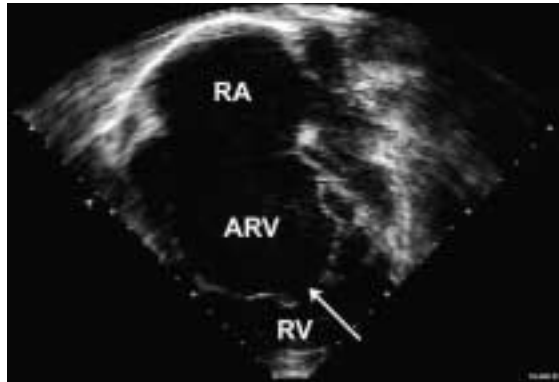


Figure 5

Echocardiographic example in a patient with severe Ebstein's anomaly with apical displacement of the dysplastic tricuspid valve's functional orifice. RV = right ventricle; ARV = atrialised right ventricle; RA = right atrium. This is the apical four chamber view (apex down) in a patient with severe Ebstein's anomaly (displacement index 22 mm/m² body surface area). The arrow points to the functional orifice of the dysplastic tricuspid valve with the grossly displaced septal leaflet. The anterior leaflet is severely tethered and nearly immobile.

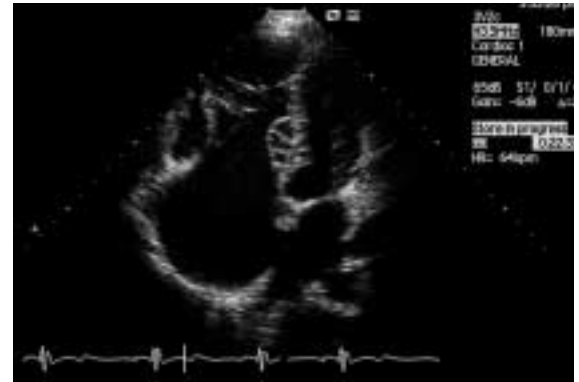

Figure 7

Example of moderately severe Ebstein's anomaly with tethering of the anterior leaflet. RA = right atrium; LA = left atrium; LV = left ventricle; ARV = atrialised right ventricle. This is the apical 4chamber view (apex up) of a patient with moderately severe Ebstein's anomaly. The displacement index is 13 mm/m² body surface area. It well shows incomplete delamination of the septal leaflet (long arrow) and moderate tethering of the anterior leaflet (small arrow).

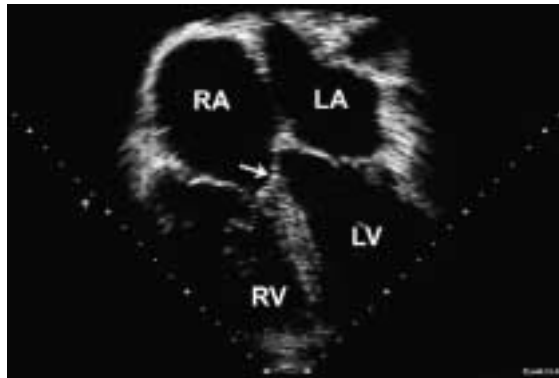


Figure 6

Echocardiographic example of mild Ebstein's anomaly. RV = right ventricle; RA = right atrium; LA = left atrium; LV = left ventricle. This is the apical 4-chamber view (apex down) of a patient with mild Ebstein's anomaly. There is only mild displacement of the septal leaflet (arrow) by 11 mm/m² body surface area. The anterior leaflet is mobile, the right ventricle only mildly enlarged.

Echocardiography is currently the diagnostic test of choice for EA and has largely obviated the need for cardiac catheterisation as a diagnostic tool in EA [38]. Echocardiographic examples of severe and mild EA are shown in figures 5–7.

Echocardiography allows accurate evaluation of the tricuspid valve leaflets, the size of the right atrium and size and function of both ventricles. The principal feature of EA is apical displacement

of the septal tricuspid valve leaflet from the insertion of the anterior leaflet of the mitral valve by at least 8 mm/m² body surface area [16]. Tethering of the tricuspid valve is present if there are at least 3 accessory attachments of the leaflet to the ventricular wall, causing restriction of valve leaflet motion [39]. Valvular dysplasia may also occur in EA and is defined as the presence of valvular thickening, nodularity and irregularity. Right ventricular dysplasia is defined as decreased wall thickness <2 standard deviations (SD), dilatation (chamber dimensions >2 SD) and dyskinesia (paradoxical septal motion, paradoxical systolic expansion of the atrialised right ventricle or markedly decreased wall motion) of the atrialised or functional right ventricle or both. Marked enlargement of the right atrium and atrialised right ventricle is considered to be present if the combined area of the right atrium and atrialised right ventricle is larger than the combined area of the functional right ventricle, left atrium and left ventricle measured in the apical four chamber view at end-diastole [23].

The site and degree of tricuspid valve regurgitation and the feasibility of valve repair are also assessed by echocardiography [17, 18].

Cine MRI may also be helpful in providing a better assessment of both right and left ventricular size and function when echocardiographic images are limited [40, 41].

Clinical features

Presentation

The cardinal symptoms in EA are cyanosis, right-sided heart failure and arrhythmias. The clinical presentation is dependent on age at presentation and the degree of haemodynamic disturbance, which in turn is dependent on the extent of displacement of the tricuspid valve leaflets, the size and function of the right ventricle, right atrial pressure and degree of right-to-left interatrial shunting [38].

On examination, the jugular venous pulse rarely shows a large v-wave despite the presence of severe tricuspid valve regurgitation, since the large right atrium engulfs the increased volume. A multiplicity of sounds and murmurs from the right heart with a widely and persistently split second heart sound are typical [38]. Digital clubbing depends on the degree of cyanosis [38].

In utero, severe EA may lead to cardiomegaly, hydrops and tachyarrhythmias. EA is a common lesion referred for foetal echocardiography by the obstetrician [39]. The intrauterine mortality rate is high in the severe forms of EA [42].

Neonates with EA may present with congestive heart failure due to tricuspid valve regurgitation, cyanosis, and marked cardiomegaly caused by right heart dilation [39]. 20–40% of all neonates diagnosed with EA will not survive 1 month, and

fewer than 50% will survive to 5 years of age. If neonates are symptomatic their prognosis is almost always very poor [21, 43, 44]. In subjects <2 years old at presentation, a haemodynamic problem is more common than in older patients (72% versus 29%, $p < 0.01$). In subjects >10 years old at presentation, an electrophysiological problem is more common than in younger patients (43% versus 10%, $p < 0.01$); these data are shown in table 2 [23].

Symptomatic children with EA may have progressive right heart failure, but most will reach adolescence and adulthood. In adulthood, patients usually present with arrhythmias, progressive cyanosis, decreasing exercise tolerance or right heart failure. In the presence of an interatrial communication, the risk of paradoxical embolisation, brain abscess and sudden death is increased [23]. Exercise tolerance is dependent on heart size (by echocardiography or chest radiograph) reflecting right ventricular dilatation and oxygen saturation at rest [45]. In patients with EA undergoing surgical repair, exercise tolerance is significantly greater postoperatively [46]. Surgery brings about an especial improvement in exercise intolerance in patients with an atrial septal defect, although tricuspid valve repair or replacement favourably affects cardiac output response to exercise [46].

Table 2

Presenting features in the different age groups.

	foetus 21 pt	neonates 88 pt	children 73 pt	adolescent 15 pt	adult 23 pt	total % 220 pt
Cyanosis	0	65	15	2	1	83 (38%)
Heart failure	0	9	14	2	6	31 (14%)
Incidental murmur	0	8	36	5	3	52 (24%)
Arrhythmia	1	5	7	6	10	29 (13%)
Abnormal foetal scan	18	0	0	0	0	18 (8%)
Other	2	1	1	0	3	7 (3%)

Adapted from Celermajer et al. *J Am Coll Cardiol* 1993;23:170–176.

Neonates = 0–1 month; children = 10 years; adolescent = 18 years; adult >18 years at time of presentation.

ECG changes, conduction system, arrhythmias and pacing

In most patients with EA the ECG is abnormal. An example is shown in figure 8. The ECG may show tall and broad P waves due to right atrial enlargement, as well as complete or incomplete right bundle branch block [38]. The R waves in leads V1 and V2 are small. First degree atrioventricular block occurs in 42% of EA patients, partly due to right atrial enlargement and partly due to structural abnormalities of the atrioventricular conduction system [38, 47]. The conduction system is situated normally [19, 48], but the A-V node may be compressed with abnormal formation of the central fibrous body and the right bundle branch may be abnormal and/or show marked fibrosis [11]. Complete heart block is rare in EA. Bizarre mor-

phologies of the terminal QRS pattern result from infra-Hissian conduction disturbance and abnormal activation of the atrialised right ventricle [49]. Patients with EA have a high potential for developing tachyarrhythmias which are a common cause of morbidity and death.

The downward displacement of the septal tricuspid valve leaflet is associated with discontinuity of the central fibrous body and septal atrioventricular ring with direct muscular connections, thus creating a potential substrate for accessory atrioventricular connections and ventricular preexcitation [15, 16].

In 6–30% of patients with EA such connections are multiple and there are one or more accessory path-

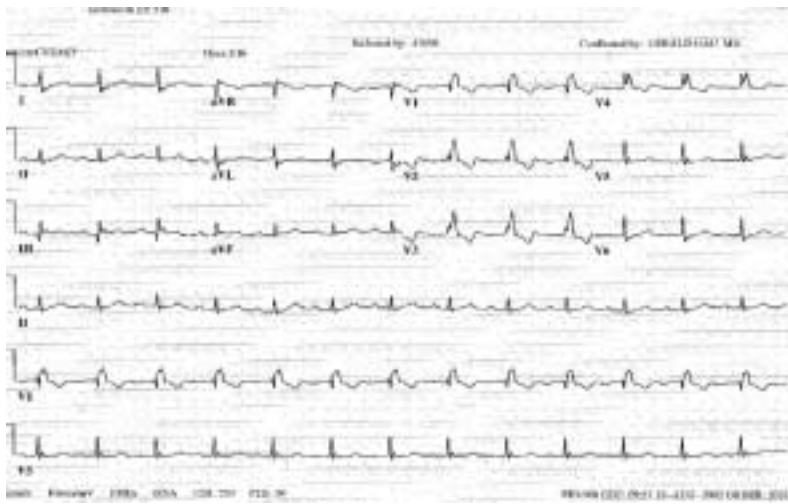


Figure 8

Example of a typical ECG in an Ebstein patient. This ECG of a 44-year-old male with EA shows normal sinus rhythm with 1st degree AV block (PR interval 256 msec) and right bundle branch block (QRS duration 152 msec), QRS axis 57°. There are no signs of preexcitation.

ways [2, 38, 49, 50]. Most of the accessory pathways are located around the orifice of the malformed tricuspid valve [47]. It is almost always Wolff-Parkinson-White pattern type B. Overall, approximately 14–20% of EA patients will have one or more accessory conduction pathways with Wolff-Parkinson-White syndrome [30]. Daliento found Wolff-Parkinson-White syndrome in 4 of 26 patients [24]. The occasional occurrence of sudden cardiac death in patients with EA is believed to be due to atrial fibrillation in the presence of Wolff-Parkinson-White syndrome [49].

In addition to the tachycardias from accessory pathways, ectopic atrial tachycardia, atrial flutter, atrial reentry tachycardia, atrial fibrillation, and ventricular tachyarrhythmias may also occur [49]. Acquired incisional atrial tachycardia is also common in EA.

An early study of 52 patients undergoing surgical repair of EA at the Mayo Clinic at a mean age of 18 years showed that preoperatively 65% had arrhythmias including paroxysmal supraventricular tachycardias (35%), paroxysmal atrial fibrillation or flutter (19%), ventricular arrhythmias

(15%) or high degree atrioventricular block (6%) [51]. There were 5 perioperative deaths; 4 occurred in patients with perioperative ventricular tachycardia or ventricular fibrillation. During a 31-month follow-up, patients who did not have preoperative arrhythmias did not develop new arrhythmias postoperatively.

Overall, supraventricular arrhythmias occur in 10–20% of older patients with EA and in 5–10% of neonates. Atrioventricular nodal reentry tachycardia is found in 1–2% of EA patients.

Permanent pacing is required in 3.7% of patients with EA. Problems of permanent pacing in EA were reviewed in 15 patients, 11 of whom needed pacing for A-V block and 4 needed pacing for sinus node dysfunction [52]. All eight patients with a VVI pacemaker were paced epicardially; 2 patients with DDD pacemakers had transvenous atrial and ventricular leads, 4 DDD patients had transvenous atrial leads and epicardial ventricular leads, and 1 patient had both epicardial and transvenous systems. Complications requiring surgical intervention occurred in four patients (lead displacement, lead failure, a lead causing tricuspid regurgitation, and exit block with secondary diaphragmatic stimulation) [52]. In the presence of tricuspid valve prosthesis, the ventricular lead for permanent DDD-pacing is most commonly achieved by an epicardial approach or an approach through the coronary sinus or a cardiac vein. Alternatively, for preoperative bradyarrhythmias, a previously-placed transvenous ventricular lead may be located outside the prosthesis sewing ring at the time of implantation of the prosthesis. Placement of a transvenous ventricular lead through a bioprosthesis is effective but less desirable because of the possibility of propping one of the valve cusps open, thus creating tricuspid regurgitation; this complication can be prevented by transoesophageal echocardiographic monitoring to insure the lead lies safely in a commissure between the cusps.

Differential diagnosis

Cardiac disorders causing tricuspid valve regurgitation and primary right-sided heart chamber enlargement may be misdiagnosed as EA. The analysis of 22 patients misdiagnosed as EA prior to referral to the Mayo Clinic showed that EA could be ruled out by the absence of apical displacement of the septal tricuspid leaflet of ≥ 8 mm/m² and lack

of a redundant, elongated anterior tricuspid leaflet [53]. The most common diagnosis was tricuspid valve dysplasia, while other diagnoses included tricuspid valve prolapse, traumatic changes of the tricuspid valve, arrhythmogenic right ventricular cardiomyopathy, and tricuspid valve endocarditis.

Natural history and prognosis

The largest study reporting the natural history of 505 patients with EA was published 30 years ago [50]. This study consisted primarily of patients aged 1–25 years, 67 patients were >25 years and

only 35 were <1 year old. Of the infants below 1 year old, 72% were in heart failure, but in 81% of the others growth and development during infancy were average or good. 71% of children and

adolescents and 60% of adults had little or no disability and were classified as NYHA I or II [50]. After initially high mortality from congestive heart failure during the first few months of life, mortality settled at an average of 12.4% spread uniformly throughout childhood and adolescence. 13.3% died of natural causes and 31 of the 57 patients (54%) who underwent surgical treatment did not survive the operation. This study was published prior to the echocardiographic era and thus does not reflect the EA population we currently encounter.

Echocardiographic features correlating with early death at 3 months of age were tethered distal attachments of the anterosuperior tricuspid leaflet, severity of right ventricular dysplasia, left ventricular compression by right heart dilatation and area of the combined right atrium and atrialised right ventricle larger than the combined area of the functional right ventricle, left atrium and left ventricle measured in the 4-chamber view [39]. The degree of apical displacement of the septal leaflet does not seem to be a prognostic feature [39]. Shiina et al. reported that absence of the septal leaflet predicted poor functional capacity [54].

Obstruction of pulmonary blood flow is another cardiovascular lesion associated with early mortality in EA [39]. Another study found that any associated cardiovascular anomalies were associated with increased mortality [55].

Celermajer et al. reviewed 220 cases with 1–34 years' follow-up. Actuarial survival for all live-born patients was 67% at 1 year and 59% at 10 years [23]. Predictors of death were echocardiographic

grade of severity at presentation (relative risk increased by 2.7 for each increase in grade, CI 1.6–4.6), foetal presentation (6.9, CI 1.6–16.5), and right ventricular outflow tract obstruction (2.1, CI 1.1–4.4).

Bialostozky et al. analysed the data of 65 patients (all <48 years), 20 patients were >20 years old at last follow-up and only 5 were >30 years [56]. In this rather young population asymptomatic or mildly symptomatic acyanotic patients without arrhythmias had a good prognosis; the only death (sudden cardiac death) occurred in a 30-year-old asymptomatic male with a history of paroxysmal ventricular tachycardia. Some moderately or severely symptomatic patients died suddenly, in a number of cases due to ventricular arrhythmias or surgical therapy. The only survivor of the severely symptomatic group (age 46) had had heart failure for at least 10 years.

In rare cases patients with EA live to over 70 years of age, and one reported patient died at the age of 85 [38].

In an early study of 67 EA patients with a mean follow-up of 12 years, 39% of patients remained in functional class I or II and 61% progressed into class III or IV. Death occurred in 14 (21%) patients and this was predicted by the following factors: functional class III or IV, moderate to severe cardiomegaly with a cardiothoracic ratio of >0.65, cyanosis or O₂ saturation of <90%, or being infants at the time of diagnosis [38]. In the 31 patients undergoing surgery modified tricuspid annuloplasty seemed to be the procedure of choice; 12 of 16 patients so treated improved [38].

Management

Medical

Patients with mild forms of EA may be followed medically for many years. Regular evaluation by a cardiologist with expertise in congenital heart disease is recommended.

Endocarditis prophylaxis is recommended in EA, though the risk of endocarditis is low.

Physical activity recommendations are summarized in Task Force 1 on Congenital Heart Disease (26th Bethesda Conference: Recommendations for Determining Eligibility for Competition in Patients with Cardiovascular Abnormalities) [57]. Athletes with mild EA, nearly normal heart size and no arrhythmias can participate in all sports. Athletes with severe EA are precluded from sports unless the patient has been optimally repaired, has a nearly normal heart size and there is no history of arrhythmias.

In patients with EA and cardiac failure who are not candidates for surgery, we recommend standard heart failure treatment including diuretics and digoxin; the efficacy of ACE inhibitors in right heart failure in this situation is unproven. Heart transplantation is an alternative treatment option

in select patients who are not candidates for standard surgical treatment.

Catheter interventions

At present most patients with symptomatic WPW syndrome, with or without EA, should undergo electrophysiological evaluation and probably radiofrequency ablation of the accessory pathway(s). Catheter ablation has a lower success rate in EA than in cases with structurally normal hearts, and the risk of recurrence is higher [58, 59]. In one study, 26 of 30 patients underwent successful radiofrequency ablation of the arrhythmogenic substrate [49]. All types of supraventricular tachyarrhythmia associated with EA should also be successfully ablated at the time of repair of EA after electrophysiological identification for best late results [60, 61]. This can be accomplished without an increase in operative mortality [60].

Surgical options

In an early report published in 1959, two patients who had undergone tricuspid valve repair died [62]. Successful surgery for tricuspid regurgi-

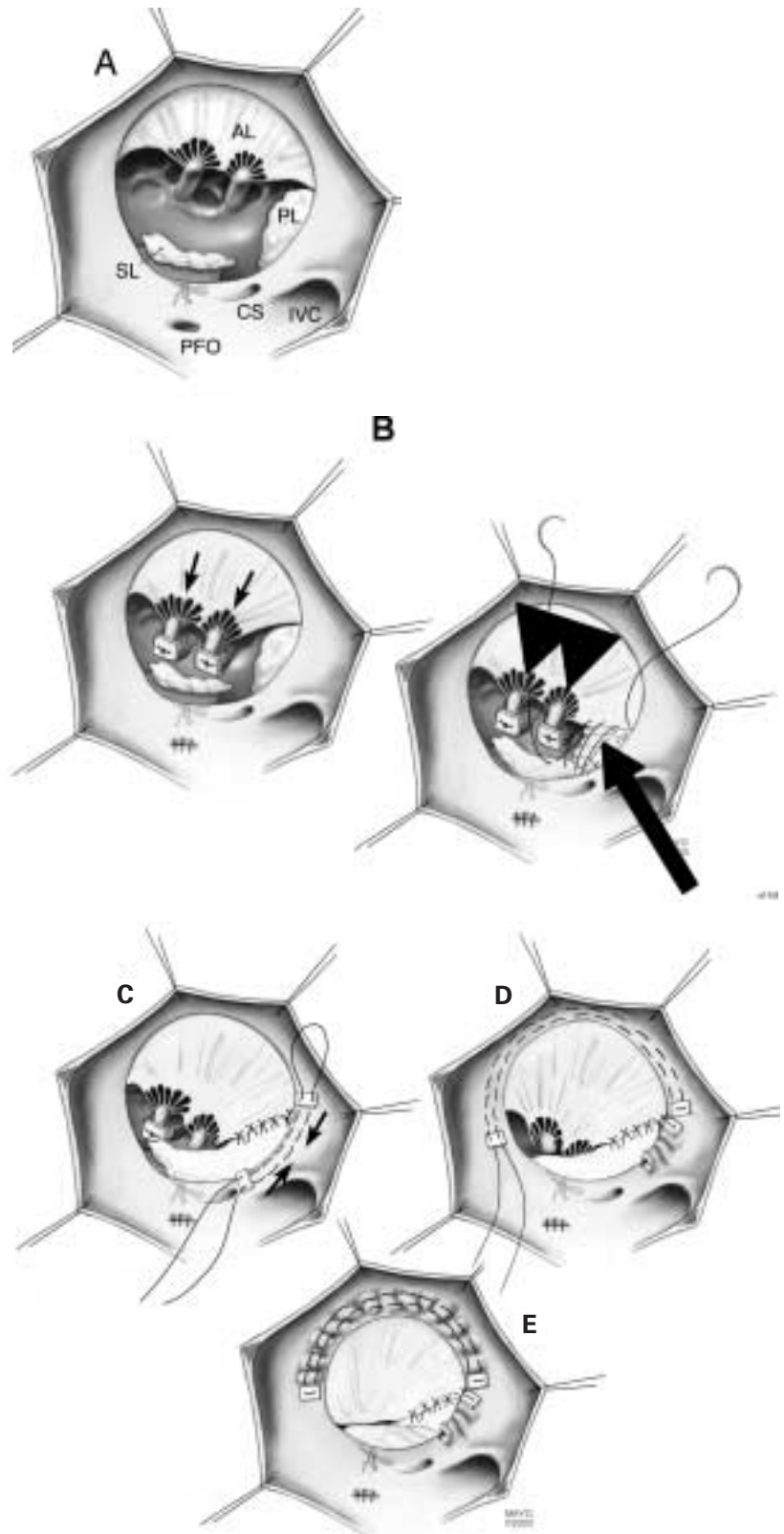
Figure 9

Illustrations of surgical technique in tricuspid valve repair for Ebstein's anomaly.

A: The surgeon's viewpoint through an oblique right atriotomy. In this example two papillary muscles arise from the free wall of the right ventricle with short chordal attachments to the leading edge of the anterior leaflet (AL). The septal leaflet (SL) is diminutive and only a ridge of tissue. The posterior leaflet (PL) is not well formed and adherent to the underlying endocardium. CS: coronary sinus. PFO: patent foramen. IVC: inferior vena cava.

Reproduced by permission of the journal *Operative Techniques in Thorac and CV Surg* where it was published: Dearani JA, Danielson GK. Tricuspid valve repair for Ebstein's anomaly. *Operative Techniques in Thorac and CV Surgery* 2003; 8:188–192. B: Typical example of the surgical approach (continued). First the base of each papillary muscle is moved towards the ventricular septum at the appropriate level with horizontal mattress sutures backed with felt pledgets (small arrows), then the mattress sutures are tied securely (small arrows). The posterior angle of the tricuspid orifice is then closed by bringing the right side of the anterior leaflet down to the septum and plicating the non-functional posterior leaflet in the process (large arrow).

C–E: Further description of typical surgical steps: C: Posterior annuloplasty (arrows) is then performed to narrow the diameter of the tricuspid annulus. The coronary sinus marks the posterior and leftward extent of the annuloplasty. D: Anterior annuloplasty is then performed to narrow the tricuspid annulus further. This annuloplasty is tied down over a 25 mm valve sizer in an adult to prevent tricuspid stenosis. E: The completed repair allows the anterior leaflet to function as a monocuspid valve. Redundant right atrium is excised prior to closing the atriotomy.



tation in EA was first described in 1962, the tricuspid valve being replaced by a prosthesis [63]. The initial review of EA patients undergoing tricuspid valve replacement found surgical mortality of 54% [50]. Disappointing results at that time were also similar high early mortality and unsatisfactory late results for tricuspid valve repair by the methods available at that time [62, 64].

In 1972 we introduced a modified annuloplasty and repair and reported the results in 16 patients [65]. The mortality was lower (13% early,

13% late) than previously reported, but higher than currently obtained. Subsequently, 25 years' experience with 314 patients was reviewed in 1997; overall early mortality was 6.4% and late mortality 7.3% [66]. Since the initial report we have also used other modifications of valve repair and replacement, depending on the anatomy encountered [18, 67]. One technique for tricuspid valve repair is shown in figure 9. This allows the anterior tricuspid leaflet to function as a monocuspid valve. Valve repairs are feasible if the anterior

leaflet is mobile and not too deficient (at least 50% of normal size). Most fenestrations can be repaired. The main prerequisite for successful repair is a free leading edge of the anterior leaflet. Repairs may be done with or without internal plication of the atrialised right ventricle.

In 1988 Carpentier proposed his repair involving mobilisation of the anterior tricuspid leaflet [22]. For his types B and C, temporary detachment of the anterior leaflet and adjacent part of the posterior leaflet was followed by longitudinal plication of the atrialised ventricle and adjacent right atrium, repositioning of the anterior and posterior leaflets to cover the orifice area at normal level, and remodelling and reinforcement of the tricuspid annulus with a prosthetic ring. His group described their experience with this repair in 191 patients with a mean age of 24 ± 15 years [68]. They reported that conservative surgery was possible in 98% of patients selected with the intention of performing reconstructive surgery. Early mortality was 9% and late survival $82 \pm 5\%$ at 20 years. The most common causes of death were right heart failure and arrhythmias.

As noted previously, 20–40% of severely symptomatic neonates with EA will not survive the first month. In the neonate, a cardiothoracic ratio greater than 0.85, GOSE echocardiographic severity score grade 4 or grade 3 associated with cyanosis, and severe tricuspid regurgitation all predict neonatal death without surgery [23, 69]. Historically, operative mortality in neonates with EA has been prohibitive, but recent improvements in neonatal management and surgery have yielded encouraging results [69]. Biventricular repair combined with correction of all associated cardiac defects is feasible, and the medium-term results are good [69].

There is controversy as to the merit of usually or routinely adding a bidirectional cavopulmonary shunt after tricuspid valve repair or replacement to reduce right ventricular volume load. The disadvantages include a longer operating time, loss of catheter access to the right heart from the upper extremities for procedures such as rhythm assessment and ablation or placement of transvenous pacemaker leads, and late sequelae in some patients troubled by pulsations in the neck veins. We occasionally use a bidirectional cavopulmonary shunt when the right ventricle is functioning poorly and it is difficult to wean the patient from cardiopulmonary bypass. Because concomitant left ventricular dysfunction may be present when the right ventricle fails, direct pressure measurements are important to document that left atrial and pulmonary artery pressures are low, otherwise the shunt will not be feasible. With regard to the use of the univentricular approach instead of a biventricular approach we have performed a modified Fontan procedure in only 2 patients in our overall series of over 500 operations for EA.

It has not yet been shown whether tricuspid valve repair or replacement has the better long-

term outcome; neither is it known whether bioprostheses are preferable to mechanical prostheses for tricuspid valve replacement. One study suggests that valve repair is less durable in adults than in children [70]. It is known that tricuspid bioprostheses in EA have greater durability than in other cardiac positions, especially in paediatric patients; freedom from bioprosthesis replacement was $80.6 \pm 7.6\%$ in one study with up to 17.8 years' follow-up (mean: 4.5 years) [71]. In one series of 294 EA patients there was no statistically significant difference between valve repair and valve replacement with regard to freedom from reoperation at 12 years [71]. Similarly, there was no difference between bioprosthetic and mechanical valve prostheses with regard to freedom from reoperation [71]. However, we currently prefer valve repair, when feasible, over valve replacement because repair has the potential to be more durable over a lifetime. Some of our early patients are doing well and free of reoperation more than 20 years after valve repair. We prefer bioprostheses over mechanical prostheses, and reserve the latter for selected adults who are already taking coumadin for another indication [18]. Bioprostheses are preferred, especially in paediatric patients, because they avoid the expense, inconvenience, and risks of long-term coumadin anticoagulation and because there is no evidence at present that mechanical valves have greater freedom from reoperation than have bioprostheses in the tricuspid position in EA patients.

Although we and others [72] have noted a reduction in atrial tachyarrhythmias after standard EA repair, which includes right atrial reduction, we currently prefer to combine repair with directed anti-arrhythmia procedures [18, 60, 61]. This can be done without increasing operative mortality and yields much improved late results [60].

Indications for operation

Observation alone is advised for asymptomatic patients and symptomatic patients with no right-to-left shunting and only mild cardiomegaly. Children who have survived infancy generally do well for a number of years; surgery can be postponed until symptoms appear or progress, cyanosis becomes evident or paradoxical emboli occur. Surgery should be considered if there is objective evidence of deterioration such as progressive increase in heart size on chest radiography, progressive right ventricular dilatation or reduction of systolic function in echocardiography, or appearance of premature ventricular contractions or atrial tachyarrhythmias. The appearance of premature ventricular contractions is considered to reflect stress on the myopathic right ventricle and to signal that correction of tricuspid regurgitation should be considered, since surgical mortality has been much greater in patients who exhibited frequent premature contractions or more serious ventricular tachyarrhythmias prior to operation. Once symptoms progress to NYHA class III or IV, medical management has little to offer, surgical

risks increase sharply and surgery is clearly indicated. Biventricular reconstruction is usually possible, but if advanced cardiomyopathic changes have occurred, especially involving the left ventricle, cardiac transplantation is the only option.

In rare cases patients with cyanosis on exercise who have an atrial septal defect or patent foramen ovale but only mild or moderate tricuspid regurgi-

tation may benefit from device closure to alleviate cyanosis and prevent paradoxical emboli. The degree of tricuspid regurgitation must be carefully assessed, however, since with low velocity flow on echocardiography it is often underestimated, and closure of an atrial septal defect alone may worsen right ventricular dysfunction.

Follow-up care

EA is a complex congenital anomaly with a broad pathologico-anatomical and clinical spectrum. Management is complex. It is therefore important that these patients are regularly seen by a cardiologist with expertise in congenital heart dis-

ease. These patients must be followed at a tertiary care centre or at least in collaboration with a congenital heart disease cardiologist in a tertiary care centre. This recommendations follows previous published recommendations [73–75].

Conclusions

EA is a complex form of congenital heart disease. No two hearts with EA are the same. Precise knowledge of the different anatomical and haemodynamic variables, associated malformations and management options, is essential. With alternative management strategies it is hoped that survival in EA patients of all ages will continue to improve.

Correspondence:

C. H. Attenhofer Jost, MD
Cardiovascular Center Zurich
Klinik Im Park
Seestrasse 200
CH-8027 Zurich, Switzerland

References

- Perloff JK. The clinical recognition of congenital heart disease. 2003;Saunders W B CO:194–215.
- Brickner ME, Hillis LD, Lange RA. Congenital heart disease in adults. Second of two parts. *N Engl J Med* 2000;342:334–42.
- Dearani JA, Danielson GK. Congenital Heart Surgery Nomenclature and Database Project: Ebstein's anomaly and tricuspid valve disease. *Ann Thorac Surg* 2000;69(4 Suppl):S106–17.
- Engle M, Payne T, Bruins C, Taussig H. Ebstein's anomaly of the tricuspid valve: report of three cases and analysis of a clinical syndrome. *Circulation* 1950;1:1246–60.
- Mann RJ, Lie JT. The life story of Wilhelm Ebstein (1836–1912) and his almost overlooked description of a congenital heart disease. *Mayo Clin Proc* 1979;54:197–204.
- van Son JA, Konstantinov IE, Zimmermann V. Wilhelm Ebstein and Ebstein's malformation. *Eur J Cardiothorac Surg* 2001;20:1082–5.
- Ebstein W. Über einen sehr seltenen Fall von Insufficienz der Valvula tricuspidalis, bedingt durch eine angeborene hochgradige Missbildung derselben. *Arch Anat Physiol* 1866:238–54.
- Schiebler GL, Gravenstein JS, Van Mierop LH. Ebstein's anomaly of the tricuspid valve. Translation of original description with comments. *Am J Cardiol* 1968;22:867–73.
- Soloff LA, Stauffer HM, Zatuchni J. Ebstein's disease: report of the first case diagnosed during life. *Am J Med Sci* 1951;222:554–61.
- Lamers WH, Viragh S, Wessels A, Moorman AF, Anderson RH. Formation of the tricuspid valve in the human heart. *Circulation* 1995;91:111–21.
- Anderson KR, Zuberbuhler JR, Anderson RH, Becker AE, Lie JT. Morphologic spectrum of Ebstein's anomaly of the heart: a review. *Mayo Clin Proc* 1979;54:174–80.
- Andelfinger G, Wright KN, Lee HS, Siemens LM, Benson DW. Canine tricuspid valve malformation, a model of human Ebstein anomaly, maps to dog chromosome 9. *J Med Genet* 2003;40:320–4.
- Emanuel R, O'Brien K, Ng R. Ebstein's anomaly. Genetic study of 26 families. *Br Heart J* 1976;38:5–7.
- Cohen LS, Friedman JM, Jefferson JW, Johnson EM, Weiner ML. A reevaluation of risk of in utero exposure to lithium. *JAMA* 1994;271:146–50.
- Frescura C, Angelini A, Daliento L, Thiene G. Morphological aspects of Ebstein's anomaly in adults. *Thorac Cardiovasc Surg* 2000;48:203–8.
- Edwards WD. Embryology and Pathologic Features of Ebstein's Anomaly. *Progr Pediatr Cardiol* 1993;2:5–15.
- Dearani JA, Danielson GK. Ebstein's Anomaly of the Tricuspid Valve. *Pediatric Cardiac Surgery* 2003(Third Edition):524–36.
- Dearani JA, Danielson GK. Ebstein's Anomaly of the Tricuspid Valve. *Pediatric Cardiac Surgery* 2003;3rd Edition, Chapter 28(Mavroudis C, Backer CL (eds). Mosby, Inc., Philadelphia, PA):524–36.
- Lev M, Liberthson RR, Joseph RH, et al. The pathologic anatomy of Ebstein's disease. *Arch Pathol* 1970;90:334–43.
- Zuberbuhler JR, Allwork SP, Anderson RH. The spectrum of Ebstein's anomaly of the tricuspid valve. *J Thorac Cardiovasc Surg* 1979;77:202–11.
- Celermajer DS, Dodd SM, Greenwald SE, Wyse RK, Deanfield JE. Morbid anatomy in neonates with Ebstein's anomaly of the tricuspid valve: pathophysiologic and clinical implications. *J Am Coll Cardiol* 1992;19:1049–53.
- Carpentier A, Chauvaud S, Macé L, et al. A new reconstructive operation for Ebstein's anomaly of the tricuspid valve. *J Thorac Cardiovasc Surg* 1988;96:92–101.
- Celermajer DS, Bull C, Till JA, et al. Ebstein's anomaly: presentation and outcome from fetus to adult. *J Am Coll Cardiol* 1994;23:170–6.
- Daliento L, Angelini A, Ho SY, et al. Angiographic and morphologic features of the left ventricle in Ebstein's malformation. *Am J Cardiol* 1997;80:1051–9.
- Benson LN, Child JS, Schwaiger M, Perloff JK, Schelbert HR. Left ventricular geometry and function in adults with Ebstein's anomaly of the tricuspid valve. *Circulation* 1987;75:353–9.
- Saxena A, Fong LV, Tristram M, Ackery DM, Keeton BR. Late noninvasive evaluation of cardiac performance in mildly symp-

- omatic older patients with Ebstein's anomaly of tricuspid valve: role of radionuclide imaging. *J Am Coll Cardiol* 1991;17:182-6.
- 27 Castaneda-Zuniga W, Nath HP, Moller JH, Edwards JE. Left-sided anomalies in Ebstein's malformation of the tricuspid valve. *Pediatr Cardiol* 1982;3:181-5.
 - 28 Attenhofer Jost CH, Connolly HM, O'Leary PW, et al. Non-compacted Myocardium in Ebstein's Anomaly: Initial Description in Three Patients. *J Am Soc Echocardiogr* 2004;17:677-80.
 - 29 Attenhofer Jost CH, Connolly HM, O'Leary PW, Warnes CA, Tajik AJ, Seward JB. Left Heart Lesions in Patients With Ebstein's Anomaly. *Mayo Clin Proc* 2005; in press.
 - 30 Danielson GK, Driscoll DJ, Mair DD, Warnes CA, Oliver WC Jr. Operative treatment of Ebstein's anomaly. *J Thorac Cardiovasc Surg* 1992;104:1195-202.
 - 31 Gerlis LM, Ho SY, Anderson RH. Bilateral Ebstein's Malformation Associated with Multiple Orifices in the Atrioventricular Valves. *Cardiovasc Pathol* 1998;7:87-95.
 - 32 Ferreira S, Ebaid M, Aiello VD. Ebstein's malformation of the tricuspid and mitral valves associated with hypoplasia of the ascending aorta. *Int J Cardiol* 1991;33:170-217.
 - 33 van Son JA, Danielson GK, Huhta JC, et al. Late results of systemic atrioventricular valve replacement in corrected transposition. *J Thorac Cardiovasc Surg* 1995;109:642-52; discussion 52-3.
 - 34 Celermajer DS, Cullen S, Deanfield JE, Sullivan ID. Congenitally corrected transposition and Ebstein's Anomaly of the systemic atrioventricular valve: Association with aortic arch obstruction. *J Am Coll Cardiol* 1991;18:1056-8.
 - 35 Dekker A, Mehrizi A, Vengsarkar AS. Corrected transposition of the great vessels with Ebstein malformation of the left atrioventricular valve. *Circulation* 1965;31:119-26.
 - 36 Silverman NH, Gerlis LM, Horowitz ES, Ho SY, Neches WH, Anderson RH. Pathologic elucidation of the echocardiographic features of Ebstein's malformation of the morphologically tricuspid valve in discordant atrioventricular connections. *Am J Cardiol* 1995;76:1277-83.
 - 37 Anderson KR, Danielson GK, McGoan DC, Lie JT. Ebstein's anomaly of the left-sided tricuspid valve: pathological anatomy of the valvular malformation. *Circulation* 1978;58:187-91.
 - 38 Giuliani ER, Fuster V, Brandenburg RO, Mair DD. Ebstein's anomaly: the clinical features and natural history of Ebstein's anomaly of the tricuspid valve. *Mayo Clin Proc* 1979;54:163-73.
 - 39 Roberson DA, Silverman NH. Ebstein's anomaly: echocardiographic and clinical features in the fetus and neonate. *J Am Coll Cardiol* 1989;14:1300-7.
 - 40 Eustace S, Kruskal JB, Hartnell GG. Ebstein's anomaly presenting in adulthood: the role of cine magnetic resonance imaging in diagnosis. *Clin Radiol* 1994;49:690-2.
 - 41 Fisher MR, Lipton MJ, Higgins CB. Magnetic resonance imaging and computed tomography in congenital heart disease. *Semin Roentgenology* 1985;20:272-82.
 - 42 Oberhoffer R, Cook AC, Lang D, et al. Correlation between echocardiographic and morphological investigations of lesions of the tricuspid valve diagnosed during fetal life. *Br Heart J* 1992;68:580-5.
 - 43 Yetman AT, Freedom RM, McCrindle BW. Outcome in cyanotic neonates with Ebstein's anomaly. *Am J Cardiol* 1998;81:749-54.
 - 44 Celermajer DS, Cullen S, Sullivan ID, Spiegelhalter DJ, Wyse RK, Deanfield JE. Outcome in neonates with Ebstein's anomaly. *J Am Coll Cardiol* 1992;19:1041-6.
 - 45 MacLellan-Tobert SG, Driscoll DJ, Mottram CD, Mahoney DW, Wollan PC, Danielson GK. Exercise tolerance in patients with Ebstein's anomaly. *J Am Coll Cardiol* 1997;29:1615-22.
 - 46 Driscoll DJ, Mottram CD, Danielson GK. Spectrum of exercise intolerance in 45 patients with Ebstein's anomaly and observations on exercise tolerance in 11 patients after surgical repair. *J Am Coll Cardiol* 1988;11:831-6.
 - 47 Ho SY, Goltz D, McCarthy K, et al. The atrioventricular junctions in Ebstein malformation. *Heart* 2000;83:444-9.
 - 48 Anderson KR, Lie JT. The right ventricular myocardium in Ebstein's anomaly: a morphometric histopathologic study. *Mayo Clin Proc* 1979;54:181-4.
 - 49 Hebe J. Ebstein's anomaly in adults. Arrhythmias: diagnosis and therapeutic approach. *Thorac Cardiovasc Surg* 2000;48:214-9.
 - 50 Watson H. Natural history of Ebstein's anomaly of tricuspid valve in childhood and adolescence. An international co-operative study of 505 cases. *Br Heart J* 1974;36:417-27.
 - 51 Oh JK, Holmes DR Jr, Hayes DL, Porter CB, Danielson GK. Cardiac arrhythmias in patients with surgical repair of Ebstein's anomaly. *J Am Coll Cardiol* 1985;6:1351-7.
 - 52 Allen MR, Hayes DL, Warnes CA, Danielson GK. Permanent pacing in Ebstein's anomaly. *Pacing Clin Electrophysiol* 1997;20:1243-6.
 - 53 Ammass NM, Warnes CA, Connolly HM, Danielson GK, Seward JB. Mimics of Ebstein's anomaly. *Am Heart J* 1997;134:508-13.
 - 54 Shiina A, Seward JB, Edwards WD, Hagler DJ, Tajik AJ. Two-dimensional echocardiographic spectrum of Ebstein's anomaly: detailed anatomic assessment. *J Am Coll Cardiol* 1984;3:356-70.
 - 55 Kumar AE, Fyler DC, Miettinen OS, Nadas AS. Ebstein's anomaly. Clinical profile and natural history. *Am J Cardiol* 1971;28:84-95.
 - 56 Bialostozky D, Horwitz S, Espino-Vela J. Ebstein's malformation of the tricuspid valve. A review of 65 cases. *Am J Cardiol* 1972;29:826-36.
 - 57 Graham TP Jr, Bricker JT, James FW, Strong WB. 26th Bethesda conference: recommendations for determining eligibility for competition in athletes with cardiovascular abnormalities. Task Force 1: congenital heart disease. *Med Sci Sports Exerc* 1994;26(10 Suppl):S246-53.
 - 58 Reich JD, Auld D, Hulse E, Sullivan K, Campbell R. The Pediatric Radiofrequency Ablation Registry's experience with Ebstein's anomaly. *Pediatric Electrophysiology Society. J Cardiovasc Electrophysiol* 1998;9:1370-7.
 - 59 Cappato R, Schluter M, Weiss C, et al. Radiofrequency current catheter ablation of accessory atrioventricular pathways in Ebstein's anomaly. *Circulation* 1996;94:376-83.
 - 60 Khositseth A, Danielson GK, Dearani JA, Munger TM, Porter CJ. Supraventricular tachyarrhythmias in Ebstein anomaly: management and outcome. *J Thorac Cardiovasc Surg* 2004;128:826-33.
 - 61 Greason KL, Dearani JA, Theodoro DA, Porter CB, Warnes CA, Danielson GK. Surgical management of atrial tachyarrhythmias associated with congenital cardiac anomalies: Mayo Clinic experience. *Semin Thorac Cardiovasc Surg Pediatr Card Surg Annu* 2003;6:59-71.
 - 62 Schiebler GL, Adams PJ, Anderson RC, Amplatz K, Lester RG. Clinical study of twenty-three cases of Ebstein's anomaly of the tricuspid valve. *Circulation* 1959;19:165-87.
 - 63 Barnard CN, Schrire V. Surgical Correction of Ebstein's Malformation With Prosthetic Tricuspid Valve. *Surgery* 1963;54:302-8.
 - 64 Hardy KL, May IA, Webster CA, Kimball KG. Ebstein's anomaly: a functional concept and successful definitive repair. *J Thorac Cardiovasc Surg* 1964;48:927-40.
 - 65 Danielson GK, Maloney JD, Devloo RA. Surgical repair of Ebstein's anomaly. *Mayo Clin Proc* 1979;54:185-92.
 - 66 Theodoro DA, Danielson GK, Kiziltan HT, et al. Surgical Management of Ebstein's Anomaly: A 25-year experience. *Circulation* 1997;96 (Suppl 1):I-507.
 - 67 Dearani JA, Danielson GK. Tricuspid valve repair for Ebstein's anomaly. *Operative Techniques in Thorac and CV Surg* 2003;8:188-92.
 - 68 Chauvaud S, Berrebi A, d'Attellis N, Mousseaux E, Hernigou A, Carpentier A. Ebstein's anomaly: repair based on functional analysis. *Eur J Cardiothorac Surg* 2003;23:525-31.
 - 69 Knott-Craig CJ, Overholt ED, Ward KE, Ringewald JM, Baker SS, Razook JD. Repair of Ebstein's anomaly in the symptomatic neonate: an evolution of technique with 7-year follow-up. *Ann Thorac Surg* 2002;73:1786-92; discussion 92-3.
 - 70 Chen JM, Mosca RS, Altmann K, et al. Early and medium-term results for repair of Ebstein anomaly. *J Thorac Cardiovasc Surg* 2004;127:990-8; discussion 8-9.
 - 71 Kiziltan HT, Theodoro DA, Warnes CA, O'Leary PW, Anderson BJ, Danielson GK. Late results of bioprosthetic tricuspid valve replacement in Ebstein's anomaly. *Ann Thorac Surg* 1998;66:1539-45.
 - 72 Ahel V, Kilvain S, Rozmanic V, Taylor JF, Vukas D. Right atrial reduction for tachyarrhythmias in Ebstein's anomaly in infancy. *Tex Heart Inst J* 2001;28:297-300.
 - 73 Deanfield J, Thaulow E, Warnes C, et al. Management of grown up congenital heart disease. *Eur Heart J* 2003;24:1035-84.
 - 74 Therrien J, Dore A, Gersony W, et al. CCS Consensus Conference 2001 update: recommendations for the management of adults with congenital heart disease. Part I. *Can J Cardiol* 2001;17:940-59.
 - 75 Landzberg MJ, Murphy DJ Jr, Davidson WR Jr, et al. Task force 4: organization of delivery systems for adults with congenital heart disease. *J Am Coll Cardiol* 2001;37:1187-93.

The many reasons why you should choose SMW to publish your research

What Swiss Medical Weekly has to offer:

- SMW's impact factor has been steadily rising, to the current 1.537
- Open access to the publication via the Internet, therefore wide audience and impact
- Rapid listing in Medline
- LinkOut-button from PubMed with link to the full text website <http://www.smw.ch> (direct link from each SMW record in PubMed)
- No-nonsense submission – you submit a single copy of your manuscript by e-mail attachment
- Peer review based on a broad spectrum of international academic referees
- Assistance of our professional statistician for every article with statistical analyses
- Fast peer review, by e-mail exchange with the referees
- Prompt decisions based on weekly conferences of the Editorial Board
- Prompt notification on the status of your manuscript by e-mail
- Professional English copy editing
- No page charges and attractive colour offprints at no extra cost

Editorial Board

Prof. Jean-Michel Dayer, Geneva
 Prof. Peter Gehr, Berne
 Prof. André P. Perruchoud, Basel
 Prof. Andreas Schaffner, Zurich
 (Editor in chief)
 Prof. Werner Straub, Berne
 Prof. Ludwig von Segesser, Lausanne

International Advisory Committee

Prof. K. E. Juhani Airaksinen, Turku, Finland
 Prof. Anthony Bayes de Luna, Barcelona, Spain
 Prof. Hubert E. Blum, Freiburg, Germany
 Prof. Walter E. Haefeli, Heidelberg, Germany
 Prof. Nino Kuenzli, Los Angeles, USA
 Prof. René Lutter, Amsterdam, The Netherlands
 Prof. Claude Martin, Marseille, France
 Prof. Josef Patsch, Innsbruck, Austria
 Prof. Luigi Tavazzi, Pavia, Italy

We evaluate manuscripts of broad clinical interest from all specialities, including experimental medicine and clinical investigation.

We look forward to receiving your paper!

Guidelines for authors:

http://www.smw.ch/set_authors.html

Impact factor Swiss Medical Weekly



All manuscripts should be sent in electronic form, to:

EMH Swiss Medical Publishers Ltd.
 SMW Editorial Secretariat
 Farnsburgerstrasse 8
 CH-4132 Muttenz

Manuscripts: submission@smw.ch
 Letters to the editor: letters@smw.ch
 Editorial Board: red@smw.ch
 Internet: <http://www.smw.ch>