

# Prosthetic joint infections: update in diagnosis and treatment

Andrej Trampuz<sup>a</sup>, Werner Zimmerli<sup>b</sup>

<sup>a</sup> Division of Infectious Diseases and Hospital Epidemiology, University Hospital, Basel, Switzerland

<sup>b</sup> Basel University Medical Clinic, Kantonsspital, Liestal, Switzerland

## Summary

The pathogenesis of prosthetic joint infection is related to microorganisms growing in biofilms, rendering these infections difficult to diagnose and to eradicate. Low-grade infections in particular are difficult to distinguish from aseptic failure, often presenting only with early loosening and persisting pain, or no clinical signs of infection at all. A combination of preoperative and intraoperative tests is usually needed for an accurate diagnosis of infection of prosthetic joint infections. Successful

treatment requires adequate surgical procedure combined with long-term antimicrobial therapy, ideally with an agent acting on adhering stationary-phase microorganisms. In this article, epidemiology, pathogenesis, diagnosis and treatment of prosthetic joint infections are reviewed.

*Key words: prosthetic joint infection; biofilm; diagnosis; treatment*

## Introduction

Joint replacement surgery is the major procedure to alleviate pain and to improve mobility in people with damaged joints. Less than 10% of prosthesis recipients develop implant-associated complications during their lifetime, predominantly as aseptic failure [1]. Infections associated with prosthetic joints occur less frequently than aseptic failures, but represent the most devastating complication with high morbidity and substantial cost. In addition to protracted hospitalisation, patients risk complications associated with additional surgery and antimicrobial treatment, as well the possibility of renewed disability [2]. Treatment of an infected prosthetic joint usually exceeds the conservative estimate of \$ 50 000 per episode [3, 4].

Due to the absence of well-designed prospective, randomised, controlled studies with a sufficient follow-up period, diagnosis and treatment of prosthetic joint infections is mainly based on tradition, personal experience and liability aspects, and therefore differs substantially between institutions and countries. In addition, different specialists involved in the management of this complication, such as orthopaedic surgeons, infectious disease physicians, and microbiologists, have different approaches. In this review, we discuss the epidemiology, pathogenesis, classification, risk factors, diagnosis and treatment of prosthetic joint infections.

## Epidemiology

The use of perioperative antimicrobial prophylaxis and laminar airflow operating rooms has substantially decreased the frequency of implant-associated infections. In patients with primary joint replacement, the infection rate in the first two years is usually <1% in hip and shoulder prostheses, <2% in knee prostheses, and <9% in elbow prostheses [5]. The reported infection rates are probably underestimated, since many cases of presumed aseptic failure may be due to unrecognised

infection. In addition, infection rates after surgical revision are usually considerably higher (up to 40%) than after primary replacement.

Importantly, prosthetic joints remain susceptible to haematogenous seeding during their entire lifetime and some perioperative infections may have a latency period longer than two years. Therefore, for accurate comparisons the frequency of infection should be reported as incidence rate (per prosthesis-years) rather than as risk

**Table 1**  
Commonly identified microorganisms causing prosthetic joint infection.

Microorganism	frequency (%)
Coagulase-negative staphylococci	30–43
<i>Staphylococcus aureus</i>	12–23
Streptococci	9–10
Enterococci	3–7
Gram-negative bacilli	3–6
Anaerobes	2–4
Polymicrobial	10–12
Unknown	10–11

(without specified denominator). In a study involving hip and knee prostheses, the incidence of infection was 5.9 per 1000 prosthesis-years during the first 2 years after implantation and 2.3 per 1000 prosthesis-years during the following 8 years [1]. In the future, it is expected that the incidence of prosthetic joint infections will further increase due to (i) better detection methods for microbial biofilms involved in prosthetic joint infections, (ii) the growing number of implanted prostheses in the ageing population and (iii) the increasing residency time of prostheses, which are at continuous risk for infection during their implanted lifetime. The most commonly identified microorganisms causing prosthetic joint infection are shown in table 1 [1, 6–8].

## Pathogenesis

### Role of microbial biofilms

Implant-associated infections are typically caused by microorganisms growing in structures known as biofilms (figure 1) [9]. These microorganisms live clustered together in a highly hydrated extracellular matrix (“slime”) attached to a surface. Depletion of metabolic substances or waste product accumulation in biofilms causes microbes to enter a slow- or non-growing (stationary) state. Therefore, biofilm microorganisms are up to 1,000 times more resistant to growth-dependent antimicrobial agents than their planktonic (free-living) counterparts [10, 11]. Biofilms contain interstitial voids (water channels) in which nutrients can circulate between microbial cells. Within biofilms, bacterial cells develop into organised and complex communities with structural and functional heterogeneity resembling multicellular organisms in which water channels serve as a rudimentary circulatory system [12]. Release of cell-to-cell signalling molecules (quorum sensing) induces bacteria in a population to respond in

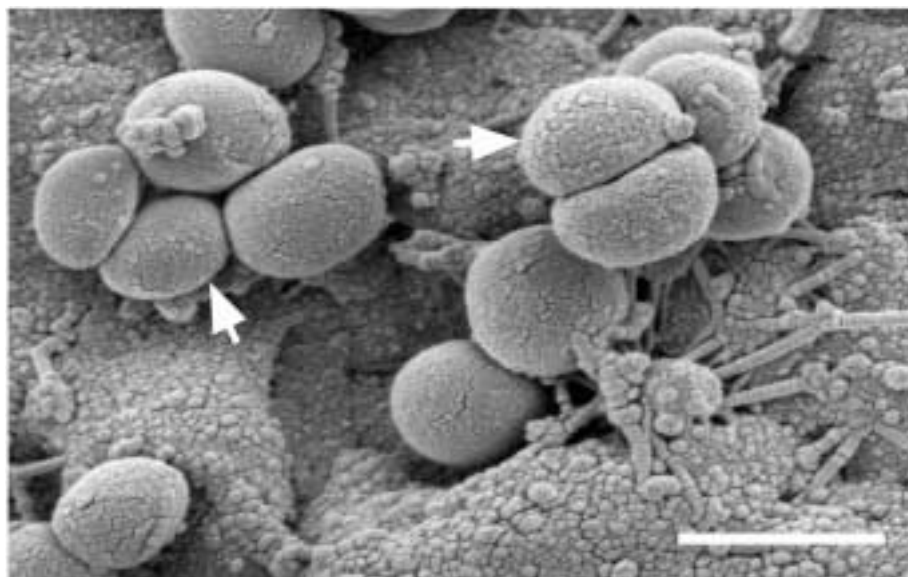
concert by changing patterns of gene expression involved in biofilm differentiation [13]. Programmed cell death of damaged cells may play an important role in bacterial biofilms, similar to multicellular organisms [14]. Furthermore, proximity of cells within the microcolony provides an ideal environment for exchange of genes located on extrachromosomal DNA (plasmids). In summary, existence within a biofilm represents a basic survival mechanism by which microbes resist against external and internal environmental factors, such as antimicrobial agents and the host immune system [15].

### Role of foreign body

The pathogenesis of implant-associated infection involves interaction between the microorganisms, the implant and the host [16]. Adherence of *Staphylococcus epidermidis* to the surface of the device involves rapid attachment to the surface of the implant mediated by nonspecific factors (such as surface tension, hydrophobia, and electrostatic

**Figure 1**

*Staphylococcus aureus* biofilm causing prosthetic joint infection. Arrows indicate bacterial cells attached to metal surface, arranged in complex three-dimensional structures. The extracellular matrix was distorted by dehydration procedure during specimen preparation for scanning electron microscopy (magnification, 25,000 $\times$ ; scale bar, 1  $\mu$ m).



forces), or by specific adhesions. This initial phase of adherence is followed by an accumulative phase during which *S. epidermidis* bacterial cells adhere to each other and form a biofilm, a process that is mediated by the polysaccharide intercellular adhesin (PIA) encoded by the *ica* operon [17]. Adherence of *S. aureus* is more dependent on the pres-

ence of host-tissue ligands, such as fibronectin, fibrinogen, and collagen. The presence of a foreign body decreases the minimal infecting dose of *S. aureus* >100,000-fold [18]. The increased susceptibility is at least partially due to a locally acquired granulocyte defect induced by frustrated phagocytosis [18, 19].

## Classification

### Prosthetic joint infection

Table 2 summarises the classification of prosthetic joint infection according to the route of infection and the time of symptom onset after implantation. In two recent studies in patients with prosthetic hip and knee associated infection, 29–45% had an early, 23–41% had a delayed, and 30–33% had a late infection [20, 21]. Leading clinical signs of early infections are persisting local pain, erythema, oedema, wound healing disturbance, large haematoma and fever. Persisting or increasing joint pain and early loosening are the hallmarks of a delayed infection, but clinical signs of infection may be absent. Therefore, such infections are often difficult to distinguish from aseptic failure. Late infections present either with a sudden onset of systemic symptoms (in about 30%) or as a subacute infection following unrecognised bacteraemia (in about 70%). The most frequent primary (distant) foci of implant-associated infec-

tions are skin, respiratory, dental and urinary tract infections [22, 23].

### Aseptic prosthetic failure

Particulate wear debris from implant materials causing osteolysis is recognised as the major cause of aseptic loosening [24]. Wear particles become deposited in the space between the implant and bone (or cement, if present), and are phagocytosed by macrophages, resulting in formation of a granulomatous tissue layer and release of inflammatory mediators, stimulating osteoclastic bone absorption (the “arthroplasty effect”). Migration of macrophages into lymphatic and blood vessels ultimately may result in distant dissemination of orthopaedic wear debris. Other aseptic mechanisms of implant failure include inappropriate mechanical load, fatigue failure at bone-implant interfaces, implant micromotion, and synovial fluid hydrodynamic pressure [25].

**Table 2**

Classification of prosthetic joint infections.

Classification	characteristic
According to the route of infection	
Perioperative	inoculation of microorganisms into the surgical wound during surgery or immediately thereafter
Haematogenous	through blood or lymph spread from a distant focus of infection
Contiguous	contiguous spread from an adjacent focus of infection (eg, penetrating trauma, preexisting osteomyelitis, skin and soft tissue lesions)
According to the onset of symptoms after implantation	
Early infection (<3 months)	predominantly acquired during implant surgery or the following 2 to 4 days and caused by highly virulent organisms (eg, <i>Staphylococcus aureus</i> or gram-negative bacilli)
Delayed or low-grade infection (3–24 months)	predominantly acquired during implant surgery and caused by less virulent organisms (eg, coagulase-negative staphylococci or <i>Propionibacterium acnes</i> )
Late infection (>24 months)	predominantly caused by haematogenous seeding from remote infections

## Risk factors

Many risk factors for prosthetic joint infection, such as rheumatoid arthritis, psoriasis, immunosuppression, steroid therapy, poor nutritional status, obesity, diabetes mellitus and extremely advanced age have been reported in case series [26–28]. In a matched case-control study with hip or knee prosthetic joint infection and their matched controls, a superficial surgical site infection, a surgical patient index score of 1 or 2, the presence of a malignancy, and a history of prior joint arthroplasty were identified as independent risk factors [29].

Bacteraemia is a risk factor for haematogenous prosthetic joint infection. The overall risk for prosthetic joint infection after bacteraemia due to all pathogens was only 0.3% in one study [30]. However, the risk of a prosthesis becoming infected after bacteraemia with *S. aureus* was considerably higher: 34% (15 of 44 cases) for prosthetic joints and 7% (1 of 15 cases) for nonarticular orthopaedic devices [31]. The risk for haematogenous infection seems to be higher in knee prostheses than in hip prostheses.

## Diagnosis

No single routinely used clinical or laboratory test has been shown to achieve ideal sensitivity, specificity, and accuracy for the diagnosis of prosthetic joint infection. Therefore a combination of laboratory, histopathology, microbiology and imaging studies is usually required [32]. Ideally, the infection is diagnosed (or excluded) before surgery, which enables starting antimicrobial treatment preoperatively and allows planning of the most appropriate surgical management. Therefore, preoperative joint aspiration with cell and microbiological examination of the synovial fluid is a valuable diagnostic tool for differentiating a septic from an aseptic process.

### Laboratory studies

*Blood leukocyte count and differential* are not sufficiently discriminative to predict the presence or absence of infection [1]. After surgery, C-reactive protein (CRP) is elevated and returns to normal within weeks. Therefore, repetitive measurements are more informative than a single value in the postoperative period. The role of procalcitonin in patients with prosthetic joint infection has not yet been defined.

*Synovial fluid leukocyte count and differential* represents a simple, rapid and accurate test for differentiating prosthetic joint-associated infection from aseptic failure. The cut-off values for diagnosing prosthetic joint infection are considerably lower than the one for septic arthritis in native joints (table 3) [33]. A synovial fluid leukocyte count of  $>1.7 \times 10^9/l$  and differential of  $>65\%$  neutrophils had a sensitivity for diagnosing prosthetic joint infection of 94% and 97%, and specificity of 88% and 98%, respectively [34].

### Histopathological studies

Histopathological examination of the peri-prosthetic tissue demonstrates generally a sensitivity  $>80\%$  and a specificity  $>90\%$  [32]. However, the degree of infiltration with inflammatory cells may vary considerably between specimens from the same patient, even within individual tissue sections. Therefore, areas with the most florid inflammatory changes should be assessed and at least ten high-power fields should be examined to obtain an average count [35]. Acute inflammation has been variably defined as from  $\geq 1$  to  $\geq 10$  neutrophils per high-power field. A major limitation of histopathological examination is that it does not identify the causative organism, an essential element in selection of appropriate antimicrobial therapy. In addition, interpretation of tissue

histopathology from patients with underlying inflammatory joint disorders may be difficult.

### Microbiological studies

#### *Preoperative specimens*

Culture of a superficial wound or sinus tract often represents microbial colonisation from the surrounding skin and can therefore be misleading. In a study of chronic osteomyelitis, cultures obtained from sinus tracts detected the infecting pathogen only in 44% of cases, as compared to cultures of intraoperative tissue specimens. Only isolation of *S. aureus* from sinus tracts is predictive of the causative pathogen [36]. Culture of aspirated synovial fluid detects the infecting microorganism in 45–100% [32] and may be further improved by inoculation into a paediatric blood culture bottle [37].

#### *Intraoperative specimens*

Periprosthetic tissue cultures provide the most accurate specimens for detecting the infecting microorganism(s), ranging from 65–94% [6, 38, 39]. At least 3 intraoperative tissue specimens should be sampled for culture [38]. Swabs have a low sensitivity and should be avoided. It is important to discontinue any antimicrobial therapy at least 2 weeks prior tissue sampling for culture [39]. Perioperative prophylaxis at revision surgery should not be started until after tissue specimens have been collected for culture [2].

#### *Removed implant or fragments*

If the implanted material is removed, it can be cultured in enrichment broth media. The advantage of this approach is to sample the site of infection directly. However, the risk of contamination during processing is high. The use of sonication to dislodge microorganisms from the surface of explanted devices may increase the sensitivity of the culture [40].

### Imaging studies

*Plain radiographs.* Examination of serial radiographs after implantation are helpful, but are neither sensitive nor specific to diagnose infection [41]. A rapid development of a continuous radiolucent line of greater than 2 mm or severe focal osteolysis within the first year is often associated with infection.

*Contrast arthrography* improves accuracy of assessing implant stability. Synovial outpouchings and abscesses are typical signs of infection [22]. The resolution may be improved by digital subtraction technique.

**Table 3**  
Characteristics of synovial fluid in patients with native and prosthetic joints

	native joints		prosthetic joints
	normal	septic arthritis	prosthetic joint infection
Leukocytes, $\times 10^9/l$	$<0.2$	$>50$	$>1.7$
Neutrophils, %	$<25$	$>90$	$>65$

*Ultrasonography* may detect fluid effusions around the prosthesis and can be used to guide joint aspiration and drainage procedures. It is especially helpful in prosthetic hip infection.

**Nuclear medicine.** Bone scintigraphy with  $^{99m}\text{Tc}$  has an excellent sensitivity, but a low specificity for diagnosing prosthetic joint infection [42, 43]. In addition, increased bone remodelling around the prosthesis is normally present during the first post-operative year and aseptic loosening cannot be differentiated from infection. Scintigraphy with  $^{99m}\text{Tc}$ -labelled monoclonal antibodies demonstrates an accuracy to detect prosthetic joint infection of 81%. Overall, all nuclear medicine imaging techniques are sensitive, but their specificity in

the evaluation of arthroplasty-associated infection is still controversial.

**Computed tomography (CT) and magnetic resonance imaging (MRI).** CT is more sensitive than plain radiography in the imaging of joint space. In addition, it may assist in guiding joint aspiration and selecting the surgical approach. MRI displays greater resolution for soft tissue abnormalities than CT or radiography and greater anatomical detail than radionuclide scans. The main disadvantages of CT and MRI are imaging interferences in the vicinity of metal implants. Positron emission tomography (PET) needs further evaluation for implant imaging.

## Treatment

### General aspects

The traditional procedure is a two-stage exchange with meticulous removal of all foreign material (implant and bone cement) combined with a finite course of antimicrobial treatment [8]. This approach is fastidious, time-consuming, and the functional result may be suboptimal due to delayed reimplantation of the prosthesis (typically after  $\geq 6$  weeks). Alternatively, a lifelong suppressive oral antimicrobial treatment (without surgical intervention) was suggested, but this approach usually controls only clinical symptoms and does not eradicate the infection. Since the ultimate goal of a successful therapy is a long-term pain-free functional joint, which can be accomplished by eradication of infection, a combination of both, an appropriate surgical procedure and an antimicrobial treatment acting on adherent bacteria is needed [44–46]. Based on *in vitro* experiments and animal models, we have developed an algorithm for the treatment of prosthetic joint infections [20, 22]. This algo-

rithm has been validated in two recent cohort studies of total hip and knee prosthetic infections with an overall success rate of 83–88% for the first treatment attempt [20, 21].

### Surgical therapy

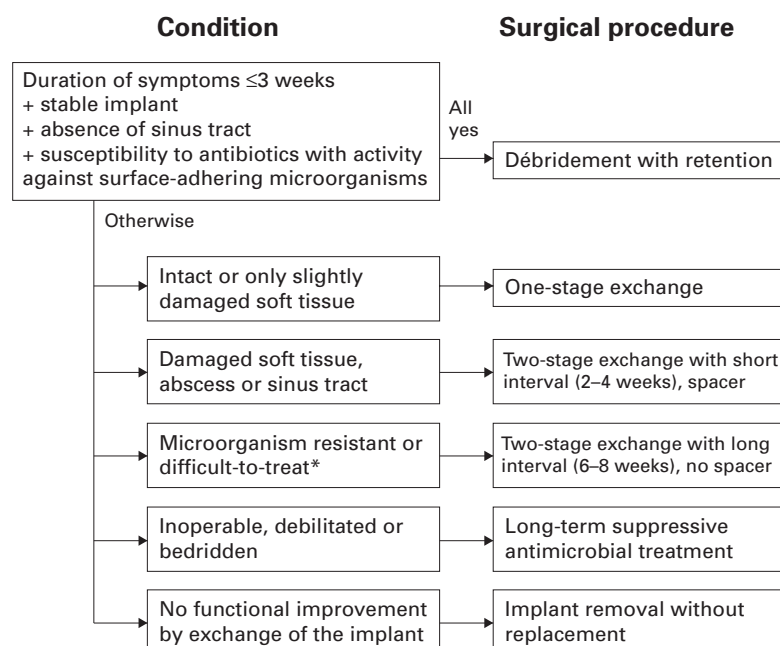
Figure 2 shows the four surgical options according to different criteria [5, 22]. *Débridement with retention* of the prosthesis has a success rate  $>70\%$  if the following conditions are fulfilled: stable implant, pathogen susceptible to antimicrobial agents active against surface-adhering microorganisms, absence of a sinus tract, and duration of symptoms of infection less than 3 weeks [5, 47]. Especially patients with early or late acute-onset haematogenous infection qualify for this procedure. There is only one randomised placebo-controlled study for the treatment of patients with orthopaedic device-related infection [47]. The patients were treated with débridement without removal combined either with ciprofloxacin plus placebo or plus rifampicin. The cure rate of staphylococcal orthopaedic implant-related infections was 100% in those patients who tolerated long-term therapy with ciprofloxacin plus rifampicin [47]. These results have been confirmed in a recent prospective observational study showing a probability of survival without treatment failure of 86% at 3 years [48].

*One-stage (direct) exchange* includes the removal and implantation of a new prosthesis during the same surgical procedure. This approach is suitable for patients with intact or only slightly compromised soft tissues and has a success rate of 86% to 100% in appropriately selected patients [49–51]. If resistant or difficult-to-treat microorganisms are causing the infection, such as methicillin-resistant *S. aureus* (MRSA), small-colony variants of staphylococci, enterococci, quinolone-resistant *Pseudomonas aeruginosa* or fungi, a two-stage revision is preferred.

*Two-stage (staged) exchange* includes removal of the prosthesis with implantation of a new prosthe-

**Figure 2**

Surgical treatment algorithm for prosthetic joint infections.  
\* Difficult-to-treat microorganisms include methicillin-resistant *S. aureus* (MRSA), small-colony variants of staphylococci, enterococci, quinolone-resistant *Pseudomonas aeruginosa* and fungi.



sis during a later surgical procedure. If no difficult-to-treat microorganisms are isolated, a short interval until reimplantation (2–4 weeks) and a temporary antimicrobial-impregnated bone cement spacer may be used. If difficult-to-treat microorganisms are isolated, a longer interval (8 weeks) without a spacer is preferred. The two-stage pro-

cedure has the highest success rate usually exceeding 90% [5, 22, 52–55]. However, the costs for the patient and the surgeon are higher than for other surgical options.

*Permanent removal of the device* is usually reserved for patients with a high risk of reinfection (eg, severe immunosuppression, active intra-

**Table 4**

Treatment of prosthetic joint infections (adapted after Zimmerli et al. [5]).

Microorganism	antimicrobial agent <sup>1</sup>	dose	route
<i>Staphylococcus aureus</i> or coagulase-negative staphylococci			
Methicillin-susceptible	rifampicin plus (flu)cloxacillin <sup>2</sup>	450 mg every 12 h 2 g every 6 h	PO/IV IV
	for 2 weeks, followed by		
Methicillin-resistant	rifampicin plus ciprofloxacin or levofloxacin	450 mg every 12 h 750 mg every 12 h 750 mg every 24 h to 500 mg every 12 h	PO PO PO PO
	for 2 weeks, followed by		
	rifampicin plus ciprofloxacin <sup>3</sup> or levofloxacin <sup>3</sup> or teicoplanin <sup>4</sup> or fusidic acid or cotrimoxazole or minocycline	450 mg every 12 h 750 mg every 12 h 750 mg every 24 h to 500 mg every 12 h 400 mg every 24 h 500 mg every 8 h 1 forte tablet every 8 h 100 mg every 12 h	PO PO PO PO IV/IM PO PO PO
	for 2 to 4 weeks, followed by		
<i>Streptococcus</i> spp. (except <i>S. agalactiae</i> )	penicillin G <sup>2</sup> or ceftriaxone	5 million U every 6 h 2 g every 24 h	IV IV
	for 4 weeks, followed by		
<i>Enterococcus</i> spp. (penicillin-susceptible) and <i>S. agalactiae</i>	amoxicillin	750–1000 mg every 8 h	PO
	for 2 to 4 weeks, followed by		
Enterobacteriaceae (quinolone-susceptible)	penicillin G or ampicillin or amoxicillin plus aminoglycoside <sup>5</sup>	5 million U every 6 h 2 g every 4–6 h	IV IV IV
	for 2 to 4 weeks, followed by		
Nonfermenters (eg, <i>Pseudomonas aeruginosa</i> )	amoxicillin	750–1000 mg every 8 h	PO
	for 2 to 4 weeks, followed by		
Anaerobes <sup>6</sup>	cefepime or ceftazidime plus aminoglycoside <sup>5</sup>	2 g every 8 h	IV
	for 2 to 4 weeks, followed by		
Mixed infections (without methicillin-resistant staphylococci)	clindamycin	600 mg every 6–8 h	IV
	for 2 to 4 weeks, followed by		
	clindamycin	300 mg every 6 h	PO
	for 2 to 4 weeks, followed by individual regimens according to antimicrobial susceptibility		
Mixed infections (without methicillin-resistant staphylococci)	amoxicillin/clavulanic acid or piperacillin/tazobactam or imipenem or meropenem	2.2 g every 8 h 4.5 g every 8 h 500 mg every 6 h 1 g every 8 h	IV IV IV IV
	for 2 to 4 weeks, followed by individual regimens according to antimicrobial susceptibility		
	for 2 to 4 weeks, followed by individual regimens according to antimicrobial susceptibility		
	for 2 to 4 weeks, followed by individual regimens according to antimicrobial susceptibility		

PO = orally; IV = intravenously; IM = intramuscularly, forte tablet: trimethoprim 160 mg plus sulfamethoxazole 800 mg.

<sup>1</sup> If implant retention or one-stage exchange is performed, the total duration of antimicrobial treatment is 3 months for hip prosthesis and 6 months for knee prosthesis. For two-stage exchange see text.

<sup>2</sup> In patients with delayed hypersensitivity, cefazolin (2 g every 8 h IV) can be administered. In patients with immediate hypersensitivity, penicillin should be replaced by vancomycin (1 g every 12 h IV).

<sup>3</sup> Methicillin-resistant *Staphylococcus aureus* should not be treated with quinolones since antimicrobial resistance may emerge during treatment.

<sup>4</sup> First day of treatment, teicoplanin dose should be increased to 800 mg IV (loading dose).

<sup>5</sup> Aminoglycosides can be administered in a single daily dose.

<sup>6</sup> Alternatively, penicillin G (5 million U every 6 h IV) or ceftriaxone (2 g every 24 h IV) can be used for gram-positive anaerobes (eg, *Propionibacterium acnes*), and metronidazole (500 mg every 8 h IV or PO) for gram-negative anaerobes (eg, *Bacteroides* spp.).

venous drug use) or when no functional improvement after surgery is expected. Alternatively, long-term antimicrobial suppression may be chosen, if the patient is inoperable, bedridden or debilitated. However, suppressive therapy only controls clinical symptoms rather than cures the infection. Therefore, infection relapses occur in most patients (>80%) when antimicrobials are discontinued.

### Antimicrobial therapy

Table 4 summarises the choice of antimicrobial agents according to the pathogen and its antimicrobial susceptibility. The suggested treatment duration is 3 months for hip prostheses and 6 months for knee prostheses [5]. Intravenous treatment should be administered for the first 2–4 weeks, followed by oral therapy to complete the treatment course. If the two-stage procedure with a long interval (8 weeks) is chosen, all foreign bodies are removed and no spacer is inserted. In such patients, antimicrobial therapy is shortened to 6 weeks after explantation. Two weeks before reimplantation it is stopped, in order to obtain reliable tissue specimens for culture and to document the treatment success. After reimplantation, antimicrobial therapy is reinstalled. If cultures of intraoperative specimens remain negative, treatment is stopped, otherwise it is continued for 3 and 6 months, respectively, as mentioned above.

The optimal antimicrobial therapy is best defined in staphylococcal implant infections, and includes rifampicin in susceptible staphylococcal strains [47]. Rifampicin has an excellent activity on slow-growing and adherent staphylococci, and proved its activity in several additional clinical studies [20, 48, 56]. It must always be combined with another drug to prevent emergence of resistance in staphylococci. Quinolones are excellent combination drugs because of their good bioavailability, activity and safety. Newer quinolones such as moxifloxacin, levofloxacin and gatifloxacin have a better in-vitro activity against quinolone-susceptible staphylococci compared to ciprofloxacin, fleroxacin or ofloxacin. However, when given alone, levofloxacin was neither able to eliminate adherent staphylococci in vitro, nor in vivo [57]. In contrast to older quinolones, no controlled clinical trials of implant-associated infection with a sufficient follow-up period have been performed. Newer quinolones were studied in experimental bone infections [58, 59], but only anecdotal clinical data exist with these new drugs [60, 61]. Moreover, possible interactions of newer quinolones with rifampicin have not yet been systematically assessed. In addition, safety data for long-term therapy with moxifloxacin and gatifloxacin are missing. For levofloxacin, long-term experience is available by extrapolating from the ofloxacin-

experience and from studies in patients with mycobacterial infection [62–64].

Because of increasing resistance to quinolones, other anti-staphylococcal drugs have been combined with rifampicin, such as cotrimoxazole or minocycline or fusidic acid [65]. High-dose oral cotrimoxazole was used in the treatment of infected orthopaedic implants in 39 patients with an overall success rate of 67%, though removal of unstable components was performed 3 to 9 months of treatment [66]. Quinopristin-dalfopristin is active against *Enterococcus faecium* (including vancomycin-resistant strains) and *S. aureus* (including MRSA), but not against *E. faecalis*. In a study of 40 patients with orthopaedic infections with MRSA, clinical success was reported in 78% and microbial eradication in 69% [67]. Linezolid is active against virtually all gram-positive cocci, including methicillin-resistant staphylococci and vancomycin-resistant enterococci (VRE). Twenty consecutive patients treated with linezolid for orthopaedic infections (15 of whom had an orthopaedic device) were retrospectively evaluated [68]. At a mean follow-up of 276 days, 55% achieved clinical cure and 35% had clinical improvement but received long-term antimicrobial suppressive therapy. Adverse events occurred commonly during therapy: 40% of patients developed reversible myelosuppression and 5% irreversible peripheral neuropathy. In another review, long-term use of linezolid (>28 days) was associated with severe peripheral and optic neuropathy. In most cases, optic neuropathies resolved after stopping linezolid but peripheral neuropathies did not [69, 70]. The mechanism of toxicity is unknown but certain pharmacological properties of linezolid that may play a part have been proposed. Only limited data on linezolid combination therapy with rifampicin is available. Daptomycin is active against several gram-positive bacteria, including MRSA, vancomycin-resistant *S. aureus*, and VRE [71]. The efficacy of daptomycin has been tested in an animal model of implant-associated infections, where it showed no advantage compared to vancomycin or teicoplanin [44].

We are grateful to Peter Ochsner, MD for developing many treatment concepts of prosthetic joint infection described in this review.

---

#### Correspondence:

Werner Zimmerli, MD

Medical University Clinic

Kantonsspital

CH-4410 Liestal

Switzerland

E-Mail: [werner.zimmerli@unibas.ch](mailto:werner.zimmerli@unibas.ch)

## References

- 1 Steckelberg JM, Osmon DR. Prosthetic Joint Infection. In: Bisno AL and Waldvogel FA eds. 3rd. Washington, DC: Am Soc Microbiol 2000:173–209.
- 2 Widmer AF. New developments in diagnosis and treatment of infection in orthopedic implants. *Clin Infect Dis* 2001;33(Suppl 2):94–106.
- 3 Hebert CK, Williams RE, Levy RS, Barrack RL. Cost of treating an infected total knee replacement. *Clin Orthop* 1996; 140–5.
- 4 Sulco TP. The economic impact of infected total joint arthroplasty. *Instr Course Lect* 1993;42:349–51.
- 5 Zimmerli W, Trampuz A, Ochsner PE. Prosthetic-joint infections. *N Engl J Med* 2004;351:1645–54.
- 6 Pandey R, Berendt AR, Athanasou NA. Histological and microbiological findings in non-infected and infected revision arthroplasty tissues: The OSIRIS Collaborative Study Group. Oxford Skeletal Infection Research and Intervention Service. *Arch Orthop Trauma Surg* 2000;120:570–4.
- 7 Segawa H, Tsukayama DT, Kyle RF, Becker DA, Gustilo RB. Infection after total knee arthroplasty: A retrospective study of the treatment of eighty-one infections. *J Bone Joint Surg Am* 1999;81:1434–45.
- 8 Brause BD. Infections with prostheses in bones and joints. In: Mandell GL, Bennett JE, and Dolin R eds. 6th. Washington, DC: WB Saunders 2005:1332–7.
- 9 Trampuz A, Osmon DR, Hanssen AD, Steckelberg JM, Patel R. Molecular and antibiofilm approaches to prosthetic joint infection. *Clin Orthop* 2003;414:69–88.
- 10 Stewart PS, Costerton JW. Antibiotic resistance of bacteria in biofilms. *Lancet* 2001;358:135–8.
- 11 Donlan RM. Biofilms: Microbial life on surfaces. *Emerg Infect Dis* 2002;8:881–90.
- 12 Boles BR, Thoendel M, Singh PK. Self-generated diversity produces “insurance effects” in biofilm communities. *Proc Natl Acad Sci USA* 2004;101:16630–5.
- 13 Davies DG, Parsek MR, Pearson JP, Iglewski BH, Costerton JW, Greenberg EP. The involvement of cell-to-cell signals in the development of a bacterial biofilm. *Science* 1998;280:295–8.
- 14 Lewis K. Programmed death in bacteria. *Microbiol Mol Biol Rev* 2000;64:503–14.
- 15 Costerton JW, Stewart PS, Greenberg EP. Bacterial biofilms: A common cause of persistent infections. *Science* 1999;284: 1318–22.
- 16 Darouiche RO. Device-associated infections: a macroproblem that starts with microadherence. *Clin Infect Dis* 2001;33: 1567–72.
- 17 Williams RJ, Henderson B, Sharp LJ, Nair SP. Identification of a fibronectin-binding protein from *Staphylococcus epidermidis*. *Infect Immun* 2002;70:6805–10.
- 18 Zimmerli W, Waldvogel FA, Vaudaux P, Nydegger UE. Pathogenesis of foreign body infection: description and characteristics of an animal model. *J Infect Dis* 1982;146:487–97.
- 19 Zimmerli W, Lew PD, Waldvogel FA. Pathogenesis of foreign body infection: Evidence for a local granulocyte defect. *J Clin Invest* 1984;73:1191–200.
- 20 Giulieri SG, Graber P, Ochsner PE, Zimmerli W. Management of infection associated with total hip arthroplasty according to a treatment algorithm. *Infection* 2004;32:222–8.
- 21 Laffer R, Graber P, Ochsner P, Zimmerli W. The case for differentiated orthopedic management of prosthetic knee-associated infection. 44th ICAAC, American Society for Microbiology, October 30–November 2, 2004, Washington, DC 2004; Abstract K-113.
- 22 Zimmerli W, Ochsner PE. Management of infection associated with prosthetic joints. *Infection* 2003;31:99–108.
- 23 Kaandorp CJ, Dinant HJ, van de Laar MA, Moens HJ, Prins AP, Dijkmans BA. Incidence and sources of native and prosthetic joint infection: a community based prospective survey. *Ann Rheum Dis* 1997;56:470–5.
- 24 Kadoya Y, Kobayashi A, Ohashi H. Wear and osteolysis in total joint replacements. *Acta Orthop Scand Suppl* 1998;278:1–16.
- 25 Bauer TW, Schils J. The pathology of total joint arthroplasty: II: Mechanisms of implant failure. *Skeletal Radiol* 1999;28: 483–97.
- 26 Wilson MG, Kelley K, Thornhill TS. Infection as a complication of total knee-replacement arthroplasty. Risk factors and treatment in sixty-seven cases. *J Bone Joint Surg Am* 1990;72: 878–83.
- 27 Poss R, Thornhill TS, Ewald FC, Thomas WH, Batte NJ, Sledge CB. Factors influencing the incidence and outcome of infection following total joint arthroplasty. *Clin Orthop* 1984; 117–26.
- 28 Salvati EA, Robinson RP, Zeno SM, Koslin BL, Brause BD, Wilson PD Jr. Infection rates after 3175 total hip and total knee replacements performed with and without a horizontal unidirectional filtered air-flow system. *J Bone Joint Surg Am* 1982; 64:525–35.
- 29 Berbari EF, Hanssen AD, Duffy MC, et al. Risk factors for prosthetic joint infection: Case-control study. *Clin Infect Dis* 1998; 27:1247–54.
- 30 Ainscow DA, Denham RA. The risk of haematogenous infection in total joint replacements. *J Bone Joint Surg Br* 1984; 66:580–2.
- 31 Murdoch DR, Roberts SA, Fowler JV Jr, et al. Infection of orthopedic prostheses after *Staphylococcus aureus* bacteremia. *Clin Infect Dis* 2001;32:647–9.
- 32 Trampuz A, Steckelberg JM, Osmon DR, Cockerill FR, Hanssen AD, Patel R. Advances in the laboratory diagnosis of prosthetic joint infection. *Rev Med Microbiol* 2003;14:1–14.
- 33 McCarty DJ. Synovial fluid. In: Koopman WJ ed. 14. Philadelphia, PA: Lippincott Williams & Wilkins, 2001:83–104.
- 34 Trampuz A, Hanssen AD, Osmon DR, Mandrekar J, Steckelberg JM, Patel R. Synovial fluid leukocyte count and differential for the diagnosis of prosthetic knee infection. *Am J Med* 2004;117:556–62.
- 35 Athanasou NA, Pandey R, de Steiger R, Crook D, Smith PM. Diagnosis of infection by frozen section during revision arthroplasty. *J Bone Joint Surg Br* 1995;77:28–33.
- 36 Mackowiak PA, Jones SR, Smith JW. Diagnostic value of sinus-tract cultures in chronic osteomyelitis. *JAMA* 1978;239:2772–5.
- 37 Hughes JG, Vetter EA, Patel R et al. Culture with BACTEC Peds Plus/F Bottle Compared with Conventional Methods for Detection of Bacteria in Synovial Fluid. *J Clin Microbiol* 2001;39:4468–71.
- 38 Atkins BL, Athanasou N, Deeks JJ, et al. Prospective evaluation of criteria for microbiological diagnosis of prosthetic-joint infection at revision arthroplasty: The OSIRIS Collaborative Study Group. *J Clin Microbiol* 1998;36:2932–9.
- 39 Spangehl MJ, Masri BA, O’Connell JX, Duncan CP. Prospective analysis of preoperative and intraoperative investigations for the diagnosis of infection at the sites of two hundred and two revision total hip arthroplasties. *J Bone Joint Surg Am* 1999; 81:672–83.
- 40 Tunney MM, Patrick S, Curran MD, et al. Detection of prosthetic hip infection at revision arthroplasty by immunofluorescence microscopy and PCR amplification of the bacterial 16S rRNA gene. *J Clin Microbiol* 1999;37:3281–90.
- 41 Tigges S, Stiles RG, Roberson JR. Appearance of septic hip prostheses on plain radiographs. *AJR Am J Roentgenol* 1994; 163:377–80.
- 42 Corstens FH, van der Meer JW. Nuclear medicine’s role in infection and inflammation. *Lancet* 1999;354:765–70.
- 43 Smith SL, Wastie ML, Forster I. Radionuclide bone scintigraphy in the detection of significant complications after total knee joint replacement. *Clin Radiol* 2001;56:221–4.
- 44 Widmer AF, Frei R, Rajacic Z, Zimmerli W. Correlation between in vivo and in vitro efficacy of antimicrobial agents against foreign body infections. *J Infect Dis* 1990;162:96–102.
- 45 Widmer AF, Wiestner A, Frei R, Zimmerli W. Killing of non-growing and adherent *Escherichia coli* determines drug efficacy in device-related infections. *Antimicrob Agents Chemother* 1991;35:741–6.
- 46 Zimmerli W, Frei R, Widmer AF, Rajacic Z. Microbiological tests to predict treatment outcome in experimental device-related infections due to *Staphylococcus aureus*. *J Antimicrob Chemother* 1994;33:959–67.
- 47 Zimmerli W, Widmer AF, Blatter M, Frei R, Ochsner PE. Role of rifampin for treatment of orthopedic implant-related staphylococcal infections: a randomized controlled trial. Foreign-Body Infection (FBI) Study Group. *JAMA* 1998;279:1537–41.
- 48 Trebbe R, Piset V, Trampuz A. Treatment of infected retained implants. *J Bone Joint Surg Br* 2005;87:249–56.
- 49 Ure KJ, Amstutz HC, Nasser S, Schmalzried TP. Direct-exchange arthroplasty for the treatment of infection after total hip replacement. An average ten-year follow-up. *J Bone Joint Surg Am* 1998;80:961–8.



- 50 Hope PG, Kristinsson KG, Norman P, Elson RA. Deep infection of cemented total hip arthroplasties caused by coagulase-negative staphylococci. *J Bone Joint Surg Br* 1989;71:851-5.
- 51 Raut VV, Siney PD, Wroblewski BM. One-stage revision of infected total hip replacements with discharging sinuses. *J Bone Joint Surg Br* 1994;76:721-4.
- 52 Langlais F. Can we improve the results of revision arthroplasty for infected total hip replacement? *J Bone Joint Surg Br* 2003;85:637-40.
- 53 Westrich GH, Salvati EA, Brause B. Postoperative infection. In: Bono JV, McCarty JC, Thornhill TS, Bierbaum BE, and Turner RH eds. 1st. New York, NY: Springer-Verlag, 1999:371-390.
- 54 Windsor RE, Insall JN, Urs WK, Miller DV, Brause BD. Two-stage reimplantation for the salvage of total knee arthroplasty complicated by infection. Further follow-up and refinement of indications. *J Bone Joint Surg Am* 1990;72:272-8.
- 55 Colyer RA, Capello WN. Surgical treatment of the infected hip implant. Two-stage reimplantation with a one-month interval. *Clin Orthop* 1994;75-9.
- 56 Widmer AF, Gaechter A, Ochsner PE, Zimmerli W. Antimicrobial treatment of orthopedic implant-related infections with rifampin combinations. *Clin Infect Dis* 1992;14:1251-3.
- 57 Schwank S, Rajacic Z, Zimmerli W, Blaser J. Impact of bacterial biofilm formation on in vitro and in vivo activities of antibiotics. *Antimicrob Agents Chemother* 1998;42:895-8.
- 58 Shirliff ME, Calhoun JH, Mader JT. Comparative evaluation of oral levofloxacin and parenteral nafcillin in the treatment of experimental methicillin-susceptible *Staphylococcus aureus* osteomyelitis in rabbits. *J Antimicrob Chemother* 2001;48:253-8.
- 59 Vaudaux P, Francois P, Bisognano C, Schrenzel J, Lew DP. Comparison of levofloxacin, alatrofloxacin, and vancomycin for prophylaxis and treatment of experimental foreign-body-associated infection by methicillin-resistant *Staphylococcus aureus*. *Antimicrob Agents Chemother* 2002;46:1503-9.
- 60 Greenberg RN, Newman MT, Shariaty S, Pectol RW. Ciprofloxacin, lomefloxacin, or levofloxacin as treatment for chronic osteomyelitis. *Antimicrob Agents Chemother* 2000;44:164-6.
- 61 Frippiat F, Meunier F, Derue G. Place of newer quinolones and rifampicin in the treatment of Gram-positive bone and joint infections. *J Antimicrob Chemother* 2004;54:1158.
- 62 Yew WW, Chan CK, Leung CC, et al. Comparative roles of levofloxacin and ofloxacin in the treatment of multidrug-resistant tuberculosis: preliminary results of a retrospective study from Hong Kong. *Chest* 2003;124:1476-81.
- 63 Drancourt M, Stein A, Argenson JN, Zannier A, Curvale G, Raoult D. Oral rifampin plus ofloxacin for treatment of *Staphylococcus*-infected orthopedic implants. *Antimicrob Agents Chemother* 1993;37:1214-8.
- 64 Drancourt M, Stein A, Argenson JN, Roiron R, Groulier P, Raoult D. Oral treatment of *Staphylococcus* spp. infected orthopaedic implants with fusidic acid or ofloxacin in combination with rifampicin. *J Antimicrob Chemother* 1997;39:235-40.
- 65 Trampuz A, Zimmerli W. New strategies for the treatment of infections associated with prosthetic joints. *Curr Opin Investig Drugs* 2005;6:185-90.
- 66 Stein A, Bataille JF, Drancourt M, et al. Ambulatory treatment of multidrug-resistant *Staphylococcus*-infected orthopedic implants with high-dose oral co-trimoxazole (trimethoprim-sulfamethoxazole). *Antimicrob Agents Chemother* 1998;42:3086-91.
- 67 Drew RH, Perfect JR, Srinath L, Kurkimalis E, Dowzicky M, Talbot GH. Treatment of methicillin-resistant *Staphylococcus aureus* infections with quinupristin-dalfopristin in patients intolerant of or failing prior therapy. For the Synercid Emergency-Use Study Group. *J Antimicrob Chemother* 2000;46:775-84.
- 68 Razonable RR, Osmon DR, Steckelberg JM. Linezolid therapy for orthopedic infections. *Mayo Clin Proc* 2004;79:1137-44.
- 69 Bressler AM, Zimmer SM, Gilmore JL, Somani J. Peripheral neuropathy associated with prolonged use of linezolid. *Lancet Infect Dis* 2004;4:528-31.
- 70 Latronico N, Fenzi F, Recupero D, et al. Critical illness myopathy and neuropathy. *Lancet* 1996;347:1579-82.
- 71 Carpenter CF, Chambers HF. Daptomycin: another novel agent for treating infections due to drug-resistant gram-positive pathogens. *Clin Infect Dis* 2004;38:994-1000.

## The many reasons why you should choose SMW to publish your research

### What Swiss Medical Weekly has to offer:

- SMW's impact factor has been steadily rising, to the current 1.537
- Open access to the publication via the Internet, therefore wide audience and impact
- Rapid listing in Medline
- LinkOut-button from PubMed with link to the full text website <http://www.smw.ch> (direct link from each SMW record in PubMed)
- No-nonsense submission – you submit a single copy of your manuscript by e-mail attachment
- Peer review based on a broad spectrum of international academic referees
- Assistance of our professional statistician for every article with statistical analyses
- Fast peer review, by e-mail exchange with the referees
- Prompt decisions based on weekly conferences of the Editorial Board
- Prompt notification on the status of your manuscript by e-mail
- Professional English copy editing
- No page charges and attractive colour offprints at no extra cost

### Editorial Board

Prof. Jean-Michel Dayer, Geneva  
 Prof. Peter Gehr, Berne  
 Prof. André P. Perruchoud, Basel  
 Prof. Andreas Schaffner, Zurich  
 (Editor in chief)  
 Prof. Werner Straub, Berne  
 Prof. Ludwig von Segesser, Lausanne

### International Advisory Committee

Prof. K. E. Juhani Airaksinen, Turku, Finland  
 Prof. Anthony Bayes de Luna, Barcelona, Spain  
 Prof. Hubert E. Blum, Freiburg, Germany  
 Prof. Walter E. Haefeli, Heidelberg, Germany  
 Prof. Nino Kuenzli, Los Angeles, USA  
 Prof. René Lutter, Amsterdam, The Netherlands  
 Prof. Claude Martin, Marseille, France  
 Prof. Josef Patsch, Innsbruck, Austria  
 Prof. Luigi Tavazzi, Pavia, Italy

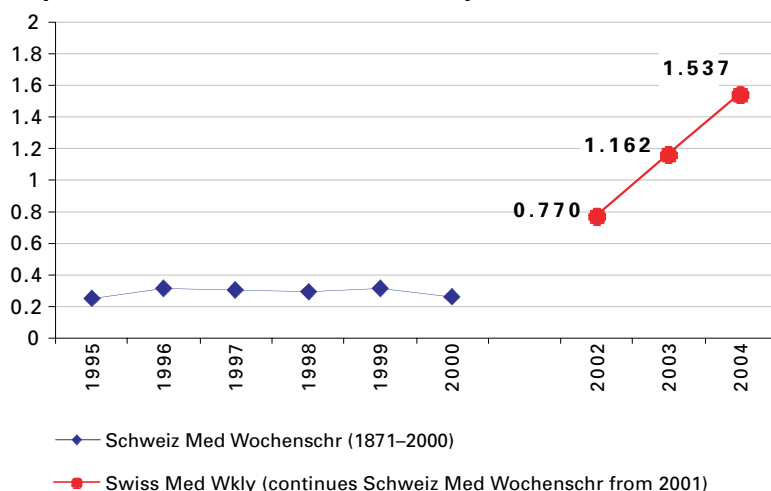
We evaluate manuscripts of broad clinical interest from all specialities, including experimental medicine and clinical investigation.

We look forward to receiving your paper!

Guidelines for authors:

[http://www.smw.ch/set\\_authors.html](http://www.smw.ch/set_authors.html)

### Impact factor Swiss Medical Weekly



All manuscripts should be sent in electronic form, to:

EMH Swiss Medical Publishers Ltd.  
 SMW Editorial Secretariat  
 Farnsburgerstrasse 8  
 CH-4132 Muttenz

Manuscripts: [submission@smw.ch](mailto:submission@smw.ch)  
 Letters to the editor: [letters@smw.ch](mailto:letters@smw.ch)  
 Editorial Board: [red@smw.ch](mailto:red@smw.ch)  
 Internet: <http://www.smw.ch>