

# Elevated troponin levels in the absence of coronary artery disease after supraventricular tachycardia

Michael J. Zellweger, Beat A. Schaer, Thomas A. Cron, Matthias E. Pfisterer, Stefan Osswald

Cardiology Department, University Hospital, Basel, Switzerland

## Summary

Generally speaking elevated troponin levels are consistent with the diagnosis of acute coronary syndrome and haemodynamically relevant coronary artery stenosis. However, they may also point to minor myocardial injury in other circumstances. Four patients with elevated troponin levels after

supraventricular tachycardia without evidence of coronary artery disease and very low risk scores for acute coronary syndrome are described and discussed.

*Key words:* troponin; supraventricular tachycardia

## Introduction

Elevated troponin levels play a pivotal role in the diagnosis of acute coronary syndrome and myocardial infarction [1]. In the past traditional enzyme evaluation left patients with small myocardial injury and cellular death undiagnosed [2]; these patients were wrongly classified as having unstable angina or, worse, non-cardiac chest pain. Troponin elevation now identifies these patients as a subgroup at high risk for subsequent cardiac events [1]. In general, elevated troponin levels are observed in the setting of acute coronary syndrome with ongoing myocardial damage and haemodynamically significant stenosis [3]. However, several conditions with elevated troponin and normal coronary arteries are not linked to acute coronary syndromes or coronary artery intervention, such as pericarditis [4], myocarditis [5], pulmonary embolism [6], sepsis [7], congestive heart failure [8],

tachycardia with haemodynamic compromise [9], renal insufficiency [10], cerebrovascular accidents [11] or prolonged strenuous endurance exercise [12]. In contrast, as far as we know, there has been no report evaluating elevated troponin levels after av-nodal reentry tachycardia (AVNRT).

Patients with positive troponin levels due to conditions other than acute coronary syndrome may receive inappropriate therapy and face delays in final diagnosis and correct treatment [9]. In interpreting troponin results it is important to take into account the context of the patient's clinical presentation.

In the present report four patients with supraventricular tachycardia (AVNRT) and elevated troponin levels without coronary artery disease are discussed.

## Case presentations

### Case 1

A 48-year-old female with a history of supraventricular tachycardia since adolescence underwent minor surgery, after which 2 prolonged episodes of supraventricular tachycardia occurred. In addition, the patient developed atypical chest pain, which she had never experienced before, and it was for this reason that she was referred for cardiac work-up. In addition to atypical chest pain, the troponin and creatine kinase levels were slightly elevated (Table 1). ECG after tachycardia revealed no abnormalities compared to baseline. Before electrophysiological

testing, echocardiography and gated myocardial perfusion (SPECT) were performed. These investigations revealed normal left ventricular function without evidence of ischaemia. Relevant coronary artery disease was therefore ruled out.

During electrophysiological testing AVNRT was easily reproducible (cycle length 355 ms, 170 bpm) and was successfully treated by slow pathway ablation. Subsequently the patient remained free from chest pain and further tachycardia.

**Table 1**  
Tachycardia and laboratory findings.

Patient	tachycardia (beats per minute)	duration (hours)	troponin I	creatine kinase	TIMI risk score
1	170–240	6	3.5 (normal <2 µg/l)	267 (normal <170 U/l)	0/1
2	175–250	22	10 (normal <2 µg/l)	214 (normal <200 U/l)	0/1
3	210	7	32 (normal <2 µg/l)	329 (normal <200 U/l)	0/1
4	180	1½	1.32 (normal <0.5 ng/ml)*	170 (normal <170 U/l)	2

It is worth noting that troponin and creatine kinase levels are consistent with peak levels.

\* In this patient a troponin test with another upper limit was used.

### Case 2

A fifty-year-old male with an unremarkable medical history developed light-headedness, dizziness, shortness of breath and nausea in the course of his daily work. After a near-fainting episode he was referred to the emergency room for cardiac evaluation and therapy. On admission the patient was asymptomatic with respect to anginal chest pain. ECG showed atrial fibrillation with rapid ventricular response and elevated troponin and creatine kinase levels (Table 1). After treatment and conversion to sinus rhythm (no changes to previously acquired ECGs) the patient underwent further work-up with treadmill stress testing and subsequent stress echocardiography. Neither of these examinations provided any clue to coronary artery disease. However, supraventricular tachycardia (cycle length 250 ms; 250 bpm) occurred during recovery from the stress echo and at this point in time the patient experienced the same symptoms as those which had prompted hospital admission. In retrospect it may be hypothesised that atrial fibrillation at first presentation was secondary to the AVNRT.

The results of electrophysiological testing were consistent with AVNRT and slow-pathway modulation was successfully performed. After treatment the patient did well and did not experience chest pain or recurrent sustained tachycardia.

### Case 3

A 44-year-old male, who in the past had had recurrent episodes of supraventricular tachycardia which he had always successfully treated by vagal manoeuvres, was admitted after experiencing a recurrent episode of tachycar-

dia which he had been unable to terminate on his own. In contrast to former episodes this one was further associated with chest pain and shortness of breath. On admission the patient still complained of chest pain and the ECG showed supraventricular tachycardia (cycle length 286 ms; 210 bpm) most probably consistent with AVNRT. The ECG obtained after conversion to sinus rhythm (adenosine) afforded no evidence of ischaemia. In view of remarkably high troponin and CK levels (table) the patient underwent coronary angiography, which revealed normal coronary arteries, normal left ventricular ejection fraction (71%), volumes and left enddiastolic ventricular pressure (10 mm Hg). Additional echocardiography confirmed these findings and demonstrated normal thickness of left ventricular walls. In a first approach the patient was treated medically and did well.

### Case 4

A 57-year-old female patient was referred with dizziness of sudden onset and chest pain. On their way back to the hospital the paramedics diagnosed supraventricular tachycardia (table) which was successfully treated by intravenous adenosine. After conversion to sinus rhythm the patient became symptom-free. However, the ECG showed slight ST depression in infero-lateral leads. In view of this, elevated troponin levels and several cardiovascular risk factors, echocardiography was performed with normal results and coronary angiography showed normal coronary arteries, normal left ventricular ejection fraction (67%), volumes and left ventricular end-diastolic pressure (4 mm Hg). In a first approach the patient was treated medically and did well.

## Discussion

All these patients had supraventricular tachycardia without evidence of coronary artery disease. However, all had elevated troponin levels and three even elevated creatine kinase levels on admission. It can be postulated that the creatine kinase elevation was due to myocardial injury in two of the patients. In the first patient with only slightly elevated troponin levels creatine kinase elevation was very probably due to the surgical procedure the patient had undergone one day before tachycardia. With regard to the ECG changes, only one patient had slight ST depression just after conversion to sinus rhythm. It is worth noting that ST alterations during AVNRT are not evidence for the presence of ischaemia. They are frequently observed without other evidence of ischaemia and with a normal ECG after conversion to sinus rhythm.

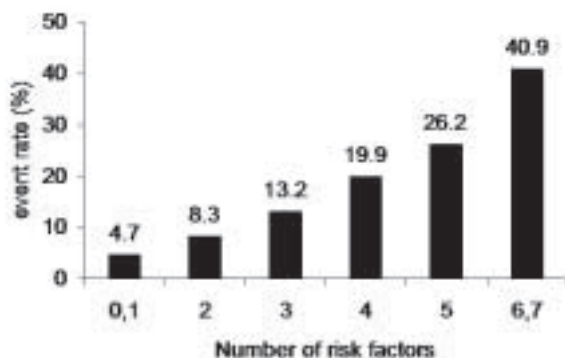
Despite the fact that "clinical" coronary artery disease was ruled out in all of these patients, elevated troponin levels may point to myocardial injury during AVNRT.

The mechanism of myocardial injury in an obviously normal heart is unclear. It may be speculated that increased demand during a relatively long period of rapid tachycardia is combined with a reduced oxygen supply to the myocardium due to the shortened diastole during tachycardia. It is of interest that no correlation between the extent of marker elevation and duration and rate of tachycardia was seen in these patients.

This observation is in accordance with a recently published report [9] describing 21 patients who had elevated troponin levels despite a normal or only mildly abnormal coronary angiogram (<50% diameter loss without complex features or

**Figure 1**

TIMI risk scores: The event rate is consistent with risk of the composite endpoint at 14 days (all-cause mortality, myocardial infarction and severe recurrent ischaemia prompting urgent revascularisation); adapted from [13].



thrombus). Troponin release was attributed to tachycardia (4 supraventricular, 2 ventricular), physical exertion, pericarditis and congestive heart failure in 29%, 10%, 10% and 5% respectively. 46% of patients had no identifiable cause for the troponin elevation.

Elevated troponin levels must thus be interpreted in the clinical context. In patients with unstable angina and non-ST elevation myocardial infarction, the TIMI risk score is a simple, prognostically important scheme which characterises a patient's risk of death and ischaemic events, and provides a basis for clinical and therapeutic decision-making [13]. The TIMI risk score takes into account the patient's age, risk factors for coronary artery disease, existence of >50% prior coronary stenosis, ST deviation, number of severe anginal events 24 h prior to hospital admission, use of aspirin and elevated serum cardiac markers (creatinine kinase MB fraction and/or cardiac-specific troponin level). Since the estimated parameters for each of the 7 predictors were of a similar magni-

tude, the risk score was calculated by assigning a value of 1 when a variable was present and then classifying patients in the test cohort by the number of risk factors present. Event rates increased significantly as the TIMI risk score increased (Figure 1). It is worth noting that all four patients described had a low TIMI risk score with no other risk factor except elevated troponin in three and only one additional risk factor in one. Thus, the presence of an acute coronary syndrome in these four patients was unlikely.

## Conclusions

Generally speaking, elevated troponin levels are consistent with the diagnosis of acute coronary syndrome and haemodynamically significant coronary artery stenosis. However, it must be borne in mind that troponin results (as also other easily available laboratory variables) need to be interpreted in the context of the patient's clinical presentation. The TIMI risk score provides a useful tool in the clinical evaluation of patients with elevated troponin levels. In the absence of clinical coronary artery disease, troponin levels may point to minor myocardial injury, as shown by this report on four cases of supraventricular tachycardia (AVNRT).

### Correspondence:

Stefan Osswald, MD  
Cardiology Department  
University Hospital  
Petersgraben 4  
CH-4031 Basel  
E-Mail: [sosswald@ubbs.ch](mailto:sosswald@ubbs.ch)

## References

- Alpert JS, Thygesen K, Antman E, Bassand JP. Myocardial infarction redefined – a consensus document of The Joint European Society of Cardiology/American College of Cardiology Committee for the redefinition of myocardial infarction. *J Am Coll Cardiol* 2000;36:959–69.
- Malasky BR, Alpert JS. Diagnosis of myocardial injury by biochemical markers: problems and promises. *Cardiol Rev* 2002;10:306–17.
- Jaffe AS. New standard for the diagnosis of acute myocardial infarction. *Cardiol Rev* 2001;9:318–22.
- Bonnefoy E, Godon P, Kirkorian G, Fatemi M, Chevalier P, Touboul P. Serum cardiac troponin I and ST-segment elevation in patients with acute pericarditis. *Eur Heart J* 2000;21:832–6.
- Lauer B, Niederau C, Kuhl U, et al. Cardiac troponin T in patients with clinically suspected myocarditis. *J Am Coll Cardiol* 1997;30:1354–9.
- Meyer T, Binder L, Hruska N, Luthe H, Buchwald AB. Cardiac troponin I elevation in acute pulmonary embolism is associated with right ventricular dysfunction. *J Am Coll Cardiol* 2000;36:1632–6.
- Ammann P, Fehr T, Minder EI, Gunter C, Bertel O. Elevation of troponin I in sepsis and septic shock. *Intensive Care Med* 2001;27:965–9.
- Missouf E, Calzolari C, Pau B. Circulating cardiac troponin I in severe congestive heart failure. *Circulation* 1997;96:2953–8.
- Bakshi TK, Choo MK, Edwards CC, Scott AG, Hart HH, Armstrong GP. Causes of elevated troponin I with a normal coronary angiogram. *Intern Med J* 2002;32:520–5.
- Freda BJ, Tang WH, Van Lente F, Peacock WF, Francis GS. Cardiac troponins in renal insufficiency. Review and clinical implications. *J Am Coll Cardiol* 2002;40:2065–71.
- James P, Ellis CJ, Whitlock RM, McNeil AR, Henley J, Anderson NE. Relation between troponin T concentration and mortality in patients presenting with an acute stroke: observational study. *BMJ* 2000;320:1502–4.
- Neumayr G, Gaenzler H, Pfister R, et al. Plasma levels of cardiac troponin I after prolonged strenuous endurance exercise. *Am J Cardiol* 2001;87:369–71, A10.
- Antman EM, Cohen M, Bernink PJ, et al. The TIMI risk score for unstable angina/non-ST elevation MI: A method for prognostication and therapeutic decision making. *JAMA* 2000;284:835–42.

## The many reasons why you should choose SMW to publish your research

### What Swiss Medical Weekly has to offer:

- SMW's impact factor has been steadily rising, to the current 1.537
- Open access to the publication via the Internet, therefore wide audience and impact
- Rapid listing in Medline
- LinkOut-button from PubMed with link to the full text website <http://www.smw.ch> (direct link from each SMW record in PubMed)
- No-nonsense submission – you submit a single copy of your manuscript by e-mail attachment
- Peer review based on a broad spectrum of international academic referees
- Assistance of our professional statistician for every article with statistical analyses
- Fast peer review, by e-mail exchange with the referees
- Prompt decisions based on weekly conferences of the Editorial Board
- Prompt notification on the status of your manuscript by e-mail
- Professional English copy editing
- No page charges and attractive colour offprints at no extra cost

### Editorial Board

Prof. Jean-Michel Dayer, Geneva  
 Prof. Peter Gehr, Berne  
 Prof. André P. Perruchoud, Basel  
 Prof. Andreas Schaffner, Zurich  
 (Editor in chief)  
 Prof. Werner Straub, Berne  
 Prof. Ludwig von Segesser, Lausanne

### International Advisory Committee

Prof. K. E. Juhani Airaksinen, Turku, Finland  
 Prof. Anthony Bayes de Luna, Barcelona, Spain  
 Prof. Hubert E. Blum, Freiburg, Germany  
 Prof. Walter E. Haefeli, Heidelberg, Germany  
 Prof. Nino Kuenzli, Los Angeles, USA  
 Prof. René Lutter, Amsterdam,  
 The Netherlands  
 Prof. Claude Martin, Marseille, France  
 Prof. Josef Patsch, Innsbruck, Austria  
 Prof. Luigi Tavazzi, Pavia, Italy

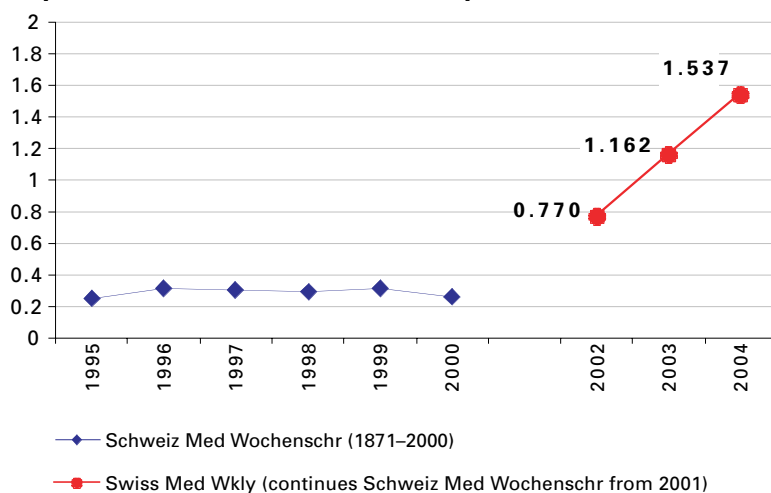
We evaluate manuscripts of broad clinical interest from all specialities, including experimental medicine and clinical investigation.

We look forward to receiving your paper!

Guidelines for authors:

[http://www.smw.ch/set\\_authors.html](http://www.smw.ch/set_authors.html)

### Impact factor Swiss Medical Weekly



All manuscripts should be sent in electronic form, to:

EMH Swiss Medical Publishers Ltd.  
 SMW Editorial Secretariat  
 Farnsburgerstrasse 8  
 CH-4132 Muttenz

Manuscripts: [submission@smw.ch](mailto:submission@smw.ch)  
 Letters to the editor: [letters@smw.ch](mailto:letters@smw.ch)  
 Editorial Board: [red@smw.ch](mailto:red@smw.ch)  
 Internet: <http://www.smw.ch>