

## Systematic review of pneumothoraces after endoscopic retrograde cholangiopancreatography

Virgilio Lehmann<sup>ab</sup>, Walther Keller<sup>bc</sup>, Bernhard Egger<sup>a</sup><sup>a</sup> Department of Surgery, HFR Fribourg Cantonal Hospital, Fribourg, Switzerland<sup>b</sup> Department of Surgery, SZB Biel, Hospital Center Biel, Biel, Switzerland<sup>c</sup> Gastroenterological Private Practice, Biel, Switzerland

### Summary

**AIMS OF THE STUDY:** Pneumothoraces after endoscopic retrograde cholangiopancreatography (ERCP) are an uncommon but potentially lethal complication. Little evidence is available on their epidemiology, diagnosis and therapy. We aimed to evaluate current practices and provide recommendations.

**METHOD:** We systematically reviewed articles from PubMed, Embase, OVID-Medline and the Cochrane Library.

**RESULTS:** Forty-four publications reported pneumothoraces after ERCP in 49 patients (74% females). Twenty-one patients (43%) had atypical gastrointestinal anatomy, including peri-ampullary diverticula ( $n = 8$ ), surgical or endoscopic alterations ( $n = 7$ ), local tumours ( $n = 3$ ), ulcerations ( $n = 2$ ) and ectopic papilla ( $n = 1$ ). Precut (14%) or standard (39%) sphincterotomies were performed. Cannulation was unsuccessful in six ERCPs. Pneumothoraces occurred bilaterally (45%), on the right (37%) or left side (6%), or no side was stated (12%). Nineteen tension pneumothoraces occurred. Perforations were mainly caused by the sphincterotome, peri-ampullary (41%), or the endoscope, distant from the papilla of Vater (23%). Pneumothoraces were sometimes diagnosed only after hospital discharge (14%). Eighteen patients underwent surgical therapy with drainage, repair and/or bypass. Conservative treatment included antibiotics and bowel rest. Most pneumothoraces were drained; 14% resolved without pleural drainage. Overall mortality was 4%. The mean hospital stay was 9.8 days.

**CONCLUSIONS:** A post-ERCP pneumothorax should be considered when subcutaneous emphysema, cardiovascular instability or respiratory distress occurs. Thoraco-abdominal computed tomography facilitates identification and therapy tailoring. Because of possible late or discrete onset, patients should be monitored carefully.

**Keywords:** ERCP, cholangiography, endoscopy, papillotomy, sphincterotomy, pneumomediastinum, pneumothorax, pneumoretroperitoneum, pneumoperitoneum, emphysema

### Introduction

Since its introduction in 1968 [1], endoscopic retrograde cholangiopancreatography (ERCP) has played a pivotal role in the diagnosis and management of biliary obstructions, in which cases it is routinely performed. Patients are either managed in outpatient settings or require short hospitalisations [2]. However, life-threatening complications can occur, such as pancreatitis (1.30%), cholangitis (0.87%), haemorrhage (0.76%) and perforations (0.58%) [1].

A perforation that develops into a pneumothorax is a rare, but potentially lethal, complication. A previous prospective multicentre study evaluated early major complications after diagnostic and therapeutic ERCPs. That study identified only one pneumothorax out of 111 major complications in 2769 consecutive patients [1]. Scattered evidence and few recommendations are currently available on the diagnosis and management of this complication. We conducted a literature review to evaluate the incidence, diagnosis, and treatment recommendations for these events.

### Materials and methods

#### Article selection

A systematic literature search was conducted in PubMed, Embase, Ovid MEDLINE and the Cochrane Library, with the following search terms in all fields and MeSH terms: “pneumothorax” and “ercp”; “pneumothorax” and “sphincterotomy”; or “pneumothorax” and “papillotomy”. We retrieved all articles published up to 23 September 2018. All available publications were evaluated. Then we screened the references of the selected articles for additional cases, by searching with the terms: “ercp”, “sphincterotomy”, or “papillotomy”; moreover, we applied the secondary search items: “air”, “gas”, “emphysema”, “pneumomediastinum”, “pneumothorax”, “pneumoretroperitoneum”, or “pneumoperitoneum”. The search strategy was validated by our hospital librarian.

All relevant articles were included in the review, according to the criteria of the initial search, including those retrieved from the iterative search through the references.

#### Correspondence:

Prof. Bernhard Egger, MD,  
HFR Fribourg Cantonal  
Hospital, Department of  
Surgery, Chemin des Pen-  
sionnats 2–6, CH-1708 Fri-  
bourg, Bernhard-eg-  
ger[at]bluewin.ch

The reporting of the review was conducted according to the Preferred Reporting Items for Systematic Reviews and Meta-Analyses (PRISMA), with the 2009 PRISMA Checklist [3].

### Article eligibility

All original articles were eligible, when they reported cases of uni- or bilateral pneumothoraces after an attempted or successful ERCP.

### Data extraction

The text and images of the reported cases were screened for air localisation and properties (e.g., side of pneumothorax, subcutaneous emphysema, pneumoperitoneum, pneumoretroperitoneum, pneumomediastinum and tension pneumothorax). The articles were also searched for demographic criteria (age and gender); underlying illness (e.g., biliary stricture, common bile duct stones [CBDS]); atypical anatomy near and distant from the peri-ampullary region (e.g., diverticulum, ulceration, tumour, surgical alterations); procedural steps and success (e.g., a precut papillotomy [PCP], a conventional endoscopic sphincterotomy [ES], cannulation, stent placement, stone extraction); probable cause of the pneumothorax (e.g., gastrointestinal perforations with localisation, endoscopy-independent causes); diagnostic tools utilised (fluoroscopy, transit study, conventional radiography, or computed tomography [CT]); treatment modalities (pleural drainage, antibiotic therapy, bowel rest or surgery); time to presentation of the pneumothorax; and the final outcome (hospital stay and/or reported death).

### Definitions

If a PCP was performed, any further mention of an ES was ignored. ERCP was defined as unsuccessful, when a CBD cannulation was not achieved.

The cause of the pneumothorax was defined as the most probable cause mentioned by the original authors. Gastrointestinal perforations were classified, based on elements from the text and images, according to a modified Stapfer classification [4] (table 1), with the localisation prioritised. Type I perforations included all endoscope-linked perforations in the gastrointestinal tract, except for those in the peri-ampullary area (in the direct vicinity of the papilla of Vater), which were classified as type II. Type III perforations included guide-wire-linked bile duct injuries and any air leakage, after a previously placed percutaneous transhepatic cholangiodrainage (PTCD) catheter. Type IV perforations included any perforations that were not documented on endoscopy, with imaging tools, or during surgical revision.

The time to presentation was defined as the time between the ERCP and the first described signs or symptoms of a

pneumothorax (e.g., emphysema, dyspnoea, reduced chest sounds, cardiovascular instability). The time to presentation was classified qualitatively, as follows: immediate – onset during or in the first hour after the procedure; early – onset within 6 hours of the procedure; or late – later findings or discovery after the initial hospital discharge.

A tension pneumothorax was defined as cardiovascular instability (simultaneous hypotension and tachycardia); a mediastinal shift detected on imaging studies; or the performance of emergency decompression procedures.

### Quality assessment

Owing to the nature of the evidence (individual case reports, retrospective case series, reviews of case reports, retrospective cohorts), we conducted a quality assessment according to the tool proposed by Murad et al. [5] and displayed it in a fashion analogous to that suggested by Higgins et al. for systematic reviews of interventions [6].

### Statistical analysis

Categorical variables are expressed as the frequency and percentage. Numerical data are expressed as the mean, median and range. Because of the nature of the review (a collection of individual cases), the limited number of cases and the rarity of this complication in prospective studies, further statistical analyses were not conducted.

## Results

### Article selection

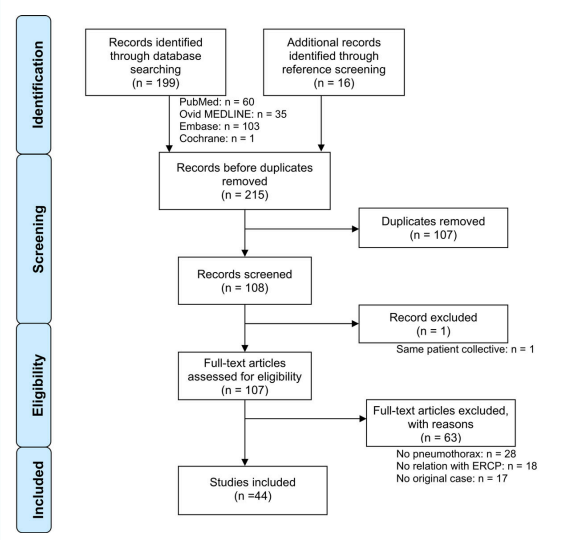
A total of 164 articles were identified and screened. Only one original publication was found in the Cochrane Library. The PRISMA flow chart of the study selection procedure is shown in figure 1. The vast majority of the 44 included publications were in English [4, 7–46], 4 were in German [42, 47], Spanish [48] or Czech [49]. No publication was excluded for language reasons.

The above-mentioned search results included all the cases described in the two included reviews [7, 40]. One record, a congress communication, was excluded since its patient

**Table 1:** Modified Stapfer classification [4].

Type	Location of perforation	Typical cause
I	Gastrointestinal tract wall (classically, the medial or lateral duodenal wall)	Endoscope
II	Peri-ampullary area (in the immediate vicinity of the papilla of Vater)	Sphincterotome
III	Bile ducts	Guide-wire / Basket
IV	No proven perforation (retroperitoneal air alone)	Compressed air

**Figure 1:** Flow chart of article selection, according to the Preferred Reporting Items for Systematic Reviews and Meta-Analyses (PRISMA) [3]



collective was already analysed in another publication [8] included in our review.

Three articles included multiple cases [4, 32, 40]. In total, 49 separate cases were identified (table 2).

### Quality assessment

The results of the quality assessment analysis are displayed in figure 2. For the assessment of the two included reviews, we only considered the quality of their original cases. By design, all case reports and retrospective studies had a selection bias. Exposure (ERCP) was always ascertained, in retrospective studies the outcome (pneumothoraces) was often insufficiently documented. The causes of pneumothoraces were better documented in case reports; however, other causes were not always actively excluded in Stapher IV injuries. Reporting quality was mostly sufficient to allow an adequate extraction of data, with the exception of retrospective studies.

### Data

Table 3 summarises the characteristics of the included cases. There were 36 female and 9 male patients (the gender of 4 patients was not reported), with a median age of 67 years (range 23–94). Atypical local anatomy was present in 21 cases (43%). Peri-ampullary diverticula, a peri-ampullary tumour, a duodenal ulceration or a pancreatic neoplasia that deformed the duodenum were noted on endoscopy in 16, 4, 4 and 2% of cases, respectively. One additional case presented with an ectopic papilla [25]. Six patients had relevant prior surgery, namely one unspecified surgical modification necessitating a double-balloon enteroscopy [24]; three roux-en-Y gastrojejunal reconstructions [19, 27, 45]; two biliodigestive anastomoses, one performed during a liver transplantation [42] and one performed during the repair of a congenital biliary obstruction [12]. One patient had a modified papilla due to previous ES [21]. The main interventional procedures in the entire patient collective were an ES (39%) and a PCP (14%), as well as stenting (31%) or stone extraction (31%). In 6 patients (12%), the intended common bile duct cannulation was not achieved.

In most cases, the cause of the pneumothorax was a duodenal perforation near (type II = 41%) or distant from the papilla (type I = 23%). The next most frequent cause was the appearance of air in a retroperitoneal location, but without a proven perforation (type IV = 10%). Five type III perforations were found: two were due to guide-wire injuries in gastrointestinal strictures [12, 23]; one was caused by the trapping of a CBDS between the wall and a balloon during dilatation [13]; and two were due to insufflation, with air tracking through a previously inserted PTCD catheter [19, 27]. Of the latter two, one resulted from overpressure in the afferent loop of a roux-en-Y reconstruction, with air consecutively tracking through the drained bile ducts, the liver parenchyma, and, eventually, the pleural space; and the other one was the result of an iatrogenic injury due to a transdiaphragmatic catheter insertion. In one rather peculiar case, a very late onset pneumothorax occurred, owing to a biliary stent dislocation and perforation in an intrathoracic herniated colon, which caused a colothoracic fistula [42]. Finally, three publications report-

ed extra-intestinal causes, including a tracheal perforation [16] and a forced Valsalva manoeuvre [32, 37].

Most reported pneumothoraces (74%) were diagnosed peri-interventionally, as a result of the immediate onset of clinical symptoms; only 6% were diagnosed early after the intervention. In 7 cases (14%) with no or few specific symptoms, the pneumothorax was diagnosed as late as 3 days after the procedure [46]. Moreover, the stent migration was diagnosed at an unclear, but even later time point [42].

Variable diagnostic tools were used to identify the site of perforation, including peri-interventional cholangiography (or fluoroscopy), X-rays, and CT scans. Pneumothoraces were described as bilateral, right-sided or left-sided, in 22,

**Table 3:** Summary of findings.

		n (N = 49)	% or range
Patient demographics	Gender	Female	36 74%
		Male	9 18%
		Unreported	4 8%
	Median age, y	67	23–94
Anatomy	No anomaly reported		28 58%
	Atypical anatomy		21 42%
		Peri-ampullary diverticula	8 16%
		Surgical alterations	6 12%
		Peri-ampullary or duodenal tumours	3 6%
		Ulcerations	2 4%
		Ectopic papilla	1 2%
Endoscopic alteration		1 2%	
Procedures	Standard endoscopic sphincterotomy		19 39%
	Precut papillotomy		7 14%
	Stent		15 31%
	Stone extraction		15 31%
	Unsuccessful cannulation		6 12%
Pneumothorax	Bilateral		22 45%
	Right		18 37%
	Left		3 6%
	Unreported		6 12%
Tension pneumothorax		19	39%
Cause of pneumothorax	Type I perforation		11 23%
	Type II perforation		20 41%
	Type III perforation		5 10%
	Type IV perforation		5 10%
	Other		4 8%
	Unreported		4 8%
Time to pneumothorax	Immediate (<1 h)		36 74%
	Early (1–6 h)		3 6%
	Late (>6 h or after discharge from hospital)		7 14%
	Unreported		3 6%
Pleural drainage	All pneumothoraces drained		30 62%
	Unilateral drainage in bilateral pneumothoraces		6 12%
	Not drained		7 14%
	Unreported		6 12%
Therapy for the perforation	Surgical repair		18 37%
	Conservative treatment		29 59%
	Unreported		2 4%
Outcome	Mean hospital stay, d		9.8 4–21
	Median stay, d		8.5
	Death		2 4%

Table 2: Characteristics of case studies and reviews.

Reference	Year	Patient		Patho.	Atypical anatomy	Procedure	Time to pres.	Pneumothorax			Air repartition	Drainage (side)	Therapy	Outcome	
		Gender	Age (y)					Side	Tension	Cause					
[7]	Al-Ashaal	2011	W	25	CBDS		UnC	Immediate	R	T	I	Prp, Pp, Pm	R	OP	14
[8]	Bartosz	2014	U	U	U	U	PCP	U	U		U	U	U	U	U
[47]	Brueck	2010	W	39	CBDS	Div	ES, StEx, stent	Immediate	B		IV	Prp, Pp, Pm, SE	OL	Cons	7
[9]	Colemont	1988	W	62	Stricture		ES, stent	Immediate	R		IV	Prp, Pm, SE	Ø	Cons	S
[10]	Doerr	1996	W	81	CBDS	Div		Immediate	R		II	Pp, Pm, SE	R	Cons	S
[11]	Ferrara	2009	M	82	CBDS		ES, StEx	Immediate	L	T	IV	Prp, Pp, Pm, SE	L	Cons	9
[12]	Fujii	2010	W	73	Stricture	Biliodig	Stent	Immediate	B		III	Prp, Pp, Pm, SE	B	Cons	7
[13]	García-Cano	2016	W	79	CBDS		ES, StEx	Early	R		III	Prp, Pm, SE	Ø	Cons	7
[14]	Garmon	2013	W	23	CBDS			Immediate	B	T	I	Prp, Pp, Pm, SE	O1	OP	5
[15]	Goddard	2016	M	68	Stricture	Tumour	UnC	Immediate	B		II	Prp, Pp, Pm, SE	OR	Cons	6
[16]	Greilich	2016	W	U	CBDS		ES, stent	Immediate	B		Tracheal tear	Pm, SE	U	OP	21
[17]	Gya	1989	W	63	CBDS		PCP	Late	R		II	Prp, Pm, SE	R	OP	S
[18]	Han	2008	M	63	CBDS	Ulc	UnC	Immediate	R	T	I	Pp	R	OP	S
[19]	Hui	2001	W	89	CBDS	BII+RY	LARCP, UnC	Immediate	R	T	III		R	Cons	S
[20]	Iyilikci	2009	W	24	CBDS		ES, StEx	Immediate	B	T	II	SE	B	OP	13
[21]	Keber	2015	W	63	CBDS	Endoscopic alt.	StEx	Immediate	B		II	Prp, Pp, SE	B	OP	S
[22]	Keskin	2014	W	56	CBDS		ES, StEx	Immediate	B		II	Prp, Pp, Pm, SE	B	OP	7
[23]	Kocaman	2009	M	24	Stricture		Stent	Immediate	B		III	Prp, Pp, Pm, SE	B	OP	8
[24]	Kogure	2014	U	U	U	Surgical alt.	DBE	U	U	T	U	U	U	U	U
[25]	Lagoudianakis	2006	M	55	CBDS	Ect	PCP, UnC	Late	R		II	Prp, SE	Ø	Cons	16
[26]	Linssen	2013	W	89	CBDS	Div	UnC	Immediate	L		II	Pp, Pm, SE	L	Cons	S
[27]	Lopes	2009	U	U	U	RY		Immediate	U	T	III		1	Cons	U
[28]	Lutchmansingh	2013	W	57	Stricture		ES, stent	Immediate	B		U	Prp, Pm, SE	OL	Cons	U
[29]	Makni	2012	W	40	CBDS		ES, StEx	Late	R	T	I	Prp, Pp, Pm, SE	R	OP	S
[30]	Markogiannakis	2007	W	56	CBDS		ES, StEx	Immediate	B	T	IV	Prp, Pp, Pm, SE	B	Cons	10
[48]	Menéndez	2012	W	79	CBDS			Early	B		I	Prp, Pp, Pm, SE	U	OP	S
[31]	Morley	1997	W	80	Stricture	Ulc	PCP	Immediate	R	T	I	Pp, SE	R	OP	S
[32]	Neofytou	2013	W	45	CBDS		ES, StEx	Immediate	R		II	Prp, Pp, Pm, SE	R	Cons	5
			W	94	CBDS			Immediate	R	T	Valsalva		R	Cons	8
[33]	Ozgonul	2010	W	62	Stricture		Stent	Late	B	T	II	Prp, Pp, Pm, SE	B	OP	S
[34]	Plönes	2012	W	67	Stricture		Stent	Immediate	B		I	Pm, SE	O1	Cons	9
[35]	Rappaport	2017	M	65	Stricture		Stent	Late	B		I	Prp, Pm	B	OP	S
[36]	Samies	2015	W	81	Stricture	Div	ES, stent	Immediate	L		IV	Prp, Pm, SE	Ø	Cons	S
[37]	Sampaziotis	2010	W	68	CBDS		ES, StEx	Immediate	B		Valsalva	Prp, Pp, Pm, SE	B	Cons	4
[38]	Savides	1993	W	79	Stricture	Tumour	ES, stent	Immediate	B		I	Prp, Pm, SE	B	OP	12
[39]	Scarlett	1994	W	59	Stricture		PCP	Immediate	R		II	Prp, Pp	R	Cons	5
[40]	Schepers	2012	W	76	CBDS	Tumour	ES, StEx, stent	Immediate	B	T	II	Prp, Pp, Pm, SE	B	Cons	10
			M	77	Stricture		PCP, stent	Immediate	B		II	Prp, Pm, SE	Ø	Cons	7
			W	88	CBDS	Div	ES	Early	R	T	II	Prp, Pm, SE	R	Cons	S
			W	58	Jaundice		PCP	Immediate	R		II	Prp, Pm	Ø	Cons	S
[41]	Schiavon	2010	W	79	CBDS	Div	ES, StEx	Immediate	R		II	Pm, SE	Ø	Cons	10
[42]	Schilling	2014	M	41	Stricture	Biliodig	Stent	Immediate	R	T	Stent migration	U	R	OP	S
[43]	Seymann	2010	W	78	CBDS	Div	StEx	Immediate	B		II	Prp, Pm, SE	B	Cons	S
[44]	Shen	2015	W	82	Stricture		ES, stent	Immediate	B	T	II	Prp, Pm, SE	O1	Cons	S
[45]	Shimatani	2009	U	U	U	RY	DBE	U	U		U	SE	1	Cons	S





included articles. First, there might have been a reporting bias due to a reluctance of authors to expose disastrous complications, as suggested previously by Schepers [40]. In addition, there might have been a publication bias, because we found studies only on dramatic cases; recently published cases were almost exclusively about bilateral or tension pneumothoraces. Other biases might have arisen because of the heterogeneous case report descriptions and collected data; this heterogeneity might be partly explained by the different professions of the authors (e.g., gastroenterologists, anaesthesiologists, emergency physicians and even cardiologists). However, despite these limitations, we provided a summary of the current evidence, and we highlighted the practices and some correlations and properties that were not previously discussed.

Intervention-related pneumothoraces are always due to leakage of intraluminal air. Therefore, it seems appropriate to compare our findings with studies that reported ERCP-linked perforations. Women and older patients were predominantly affected by this complication. Savides [38] suggested that age-related thinning of the duodenal wall might be a determining factor. However, age and female gender are also the most predominant factors in patients suffering from gallstone disease. Therefore, intervention-related pneumothoraces are much more related to ERCP performed to treat CBDS and much less directly to these two factors [50]. Although studies have shown that women were more prone to developing post-ERCP pancreatitis, no link has been demonstrated between patient sex and a susceptibility to perforations [51].

Consistently with a previous retrospective case control study [52], we identified several local and interventional risk factors for the occurrence of ERCP-related pneumothorax, including an ES, PCP, dilated common bile duct, a dilatation manoeuvre and atypical anatomy. Other recognised contributing factors include the duration of the procedure and the insufflation time after the injury [53]. Because the insufflation time probably determines the amount of air that will leak through the injury, it might contribute to the development of significant pneumothoraces. As a result of the above-mentioned lack of data in the reviewed cases, corroboration was not possible.

Strategies to avoid ERCP-linked complications were not discussed in the reviewed articles. However, such strategies are nicely described in the literature: for example, a magnetic resonance cholangiopancreatography (MRCP)-first approach might minimise unnecessary diagnostic ERCPs; however, it remains a matter of debate whether this approach might diminish the overall complication rate [54]. Anatomical information gained by an MRCP could, in combination with demographic and clinical factors, provide a partial basis for the anticipation of risky constellations. Intra-interventional bail-out strategies could additionally limit injuries in complicated cannulations. Conducting another ERCP after a few days is often successful and should be considered, particularly in the setting of bleeding or increasing papillary oedema. Alternative strategies might also be considered, such as a PTC or even a surgical revision. These strategies could at least minimise the intervention time and the need for PCPs [55].

The pathophysiological mechanisms of pneumothorax formation during ERCP have been described in the literature.

In summary, there are four possible routes to the mediastinal and pleural spaces: (1) in a retroperitoneal perforation, air can track throughout the continuous fascial planes, up to the thoracic cavity [56]; (2) in a free peritoneal perforation, air can communicate between the abdominal and thoracic cavities through diaphragmatic orifices (peritoneal stomata) in porous diaphragm syndromes [23]; (3) in the absence of a true perforation, air can enter the mucosa at a weak spot (e.g., anastomosis, diverticulum) and track along the perineural and perivascular sheaths [12]; (4) finally, air from a ruptured alveolus (through hyperventilation, the Valsalva manoeuvre, or excess positive pressure during ventilation) can track into the perivascular sheath, which could lead to pulmonary interstitial emphysema, and eventually, cause endoscopy-independent pneumothoraces, also known as the Macklin effect [10].

To the best of our knowledge, the right-sided predominance of pneumothoraces remains unexplained. We postulated that air might follow the path of least resistance. Indeed, the development of left pneumothoraces might be discouraged by the presence of adhesions between the retroperitoneum and the anterior aortic sheath, which might form an anatomic barrier.

The consistent presence of a pneumomediastinum in bilateral pneumothoraces suggested bilateral mediastinal tears caused by a tension pneumomediastinum with air leaking into both pleural cavities. Alternatively, some patients might have a congenital or surgically acquired communication between the two pleural spaces; this is known as “buffalo chest syndrome” [57]. In this condition, bilateral pneumothoraces could occur without a pneumomediastinum [20].

The high prevalence of tension (39%) and bilateral (45%) pneumothoraces among the reviewed cases might be due to the above-mentioned publication bias, because only severe cases were published. Alternatively, high pressure insufflation might be another contributing factor; this pressure could either cause decompression to the second hemithorax or lead to the development of tension.

The clinical signs and diagnosis of an ERCP-related perforation have been described extensively [4, 12, 39, 58]. A thoraco-abdominal CT scan is the diagnostic gold standard for evaluating the problem (fig. 3) [59]. The classical clinical signs of small pneumothoraces, such as diminished breath sounds and tympanic percussion, are frequently overlooked, particularly in patients who are otherwise stable post-ERCP. Subcutaneous emphysema, which was often present in the reported cases (78%), is a highly suspicious sign of an air-containing organ perforation, even without pneumothorax formation. A tension pneumothorax should be suspected when patients exhibit neck vein distention, tracheal deviation, tachycardia, and/or desaturation. Moreover, decompensation signs, such as respiratory distress or circulatory instability, should rouse suspicion of a tension pneumothorax, and after clinical confirmation, it should lead to immediate decompression, without further delay, even for imaging. However, in stable patients suspected of having a perforation with pneumothorax, radiographic evaluation should be performed before drainage, as suggested by the authors of a recent review [60].

A simple chest X-ray or sonography [53, 61] may exclude relevant pneumothorax formations. However, in accor-

dance with the newest recommendations from the European Society of Gastrointestinal Endoscopy on iatrogenic endoscopic perforations [59], we strongly recommend an imaging evaluation with a thoraco-abdominal CT scan in such patients. The presence of a duodenal diverticulum, the performance of a PCP or ES and long procedure times should be considered reasons to lower the threshold for additional diagnostic studies after the intervention. In the specific case of intra-interventional suspicion of perforation and the beginning of a tension pneumothorax, the use of fluoroscopy, which is typically available in the ERCP-room, might enable an immediate diagnosis [18, 22, 31, 40]. However, minimum pneumothorax formations might be overlooked, due to the supine positioning. Finally, a loss of image resolution might be an indirect sign of extraluminal air formation. This finding should suggest the need for additional imaging studies, such as CT.

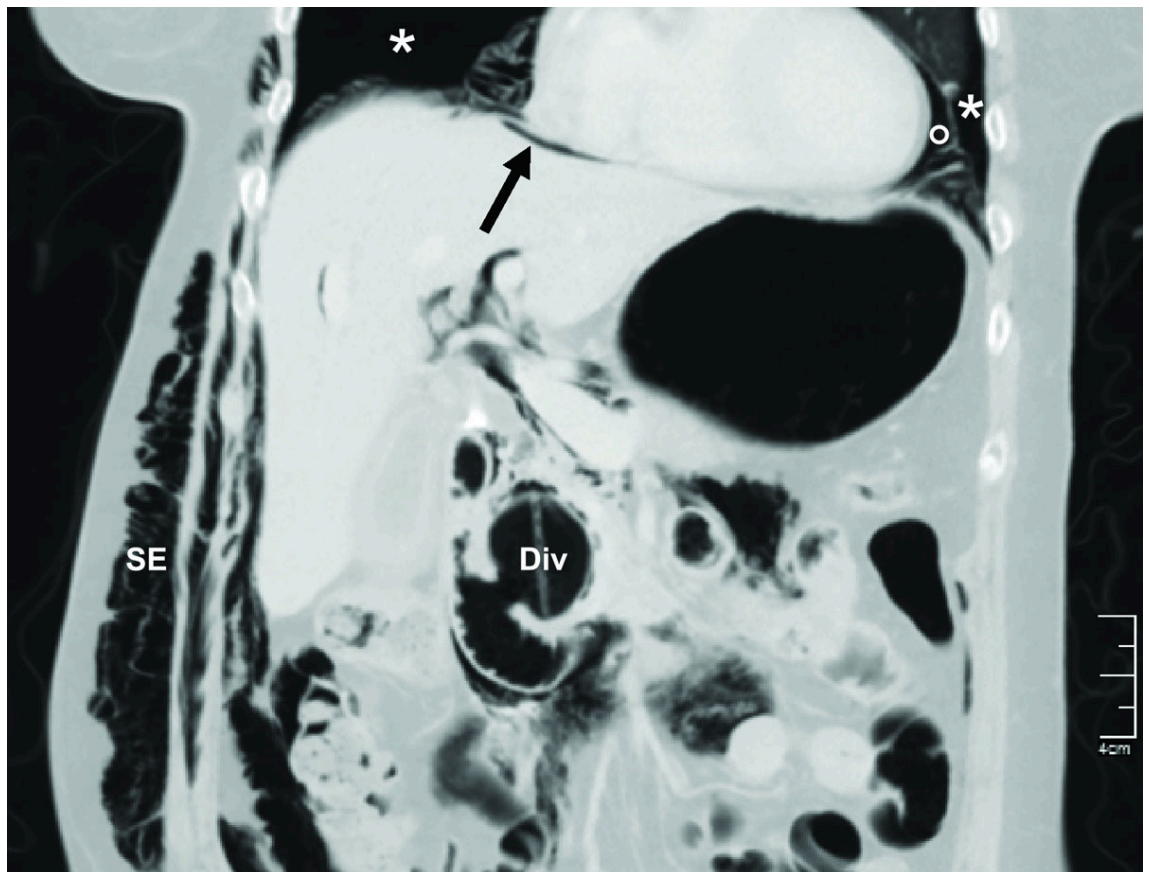
It would be appropriate to tailor therapies for treating perforations and pneumothoraces. A step-by-step approach has been advocated, based on the degree of perforation and the evolution of the patient's injury [4, 12, 39, 58]. In our review, we found that type I perforations were commonly managed operatively, except for small oesophageal tears that could be detected with CT but not by endoscopy [34]. Types II and III perforations were mainly managed conservatively, which is consistent with literature recommendations. However, the time and specifications of antibiotic therapy and bowel rest have not been standardised.

Early treatments for pneumothoraces include supplemental oxygen, close monitoring and iterated evaluations of drainage procedures. Drainage should be evaluated according to the amount of collapsed pulmonary tissue and patient compensation, which also depends on previous lung function. One-sided drainage may be sufficient, even in bilateral pneumothoraces. Therefore, in symmetrical pneumothoraces without instability, decompression and drainage should first be performed on the right side, and then, according to the evolution, a tailored contralateral drainage might be warranted. In any case, pleural drainage might accelerate recovery. In the literature, hospital stays were only reported for four of seven patients who did not receive drainage. As mentioned above, a tension pneumothorax requires prompt management.

It is of pivotal importance to monitor the patient after ERCP. A review [2] suggested that patients in good general condition, without additional risk factors, might be eligible for outpatient ERCs. The authors mentioned that only 10% of all post-ERCP complications that required treatment presented symptoms after 24 hours. The present review demonstrated that late symptom onset occurred in 14% of patients. Therefore, close monitoring for at least 6 hours after the procedure is mandatory, and at our institutions an overnight stay is standard.

None of the patients included in this review died as a direct result of a pneumothorax; in the patients who died, the perforation and related sepsis were ultimately the cause of death. However, a missed pneumothorax could be lethal

**Figure 3:** Post-ERCP abdominal computed tomography scan of a 75-year old patient at our institution demonstrating bilateral pneumothoraces (\*), pneumomediastinum (\*), pneumoperitoneum (arrow), and subcutaneous emphysema (SE). A peri-ampullary diverticulum (Div) is also present. A smaller but significant pneumothorax could have been missed, since the thorax was incompletely scanned.



when left untreated [60], particularly in patients who require intubation for a surgical revision. Therefore, we advocate that pneumothorax formation should be actively excluded in cases of ERCP-linked perforation, before any further action is taken.

In conclusion, pneumothorax is a rare, but significant complication of ERCP, and it might not become evident until days after the procedure. In particular, after unsuccessful attempts to cannulate the common bile duct, it is mandatory to observe the patient closely. Because of the rarity of this complication, it is essential to report new cases frequently to ensure that physicians remain alert to this phenomenon. Additionally, reviews of reported cases might further refine our knowledge of diagnostic and treatment modalities.

#### Disclosure statement

This research received no specific grant from any funding agency in the public, commercial, or not-for-profit sectors; the authors remain independent of any funding influence and declare no support from any organisation for the submitted work. All authors declare no financial relationships with any organisations that might have an interest in the submitted work in the previous three years and no other relationships or activities that could appear to have influenced the submitted work.

#### References

- Loperfido S, Angelini GBenedetti G, Chilovi F, Costan F, De Berardinis F. Major early complications from diagnostic and therapeutic ERCP: a prospective multicenter study. *Gastrointest Endosc.* 1998;48(1):1–10. [http://dx.doi.org/10.1016/S0016-5107\(98\)70121-X](http://dx.doi.org/10.1016/S0016-5107(98)70121-X). PubMed.
- Jeumink SMP, Poley JW, Steyerberg EW, Kuipers EJS, Siersema PD. ERCP as an outpatient treatment: a review. *Gastrointest Endosc.* 2008;68(1):118–23. <http://dx.doi.org/10.1016/j.gie.2007.11.035>. PubMed.
- Moher DL, Liberati A, Tetzlaff J, Altman DG, PRISMA Group. Preferred reporting items for systematic reviews and meta-analyses: the PRISMA statement. *Int J Surg.* 2010;8(5):336–41. <http://dx.doi.org/10.1016/j.ijsu.2010.02.007>. PubMed.
- Stapfer MS, Selby RR, Stain S, CKatkhouda N, Parekh DJ, Jabour N. Management of duodenal perforation after endoscopic retrograde cholangiopancreatography and sphincterotomy. *Ann Surg.* 2000;232(2):191–8. <http://dx.doi.org/10.1097/0000658-200008000-00007>. PubMed.
- Murad MHS, Sultan SH, Faffar SB, Zerbachi F. Methodological quality and synthesis of case series and case reports. *BMJ Evid Based Med.* 2018;23(2):60–3. <http://dx.doi.org/10.1136/bmjebm-2017-110853>. PubMed.
- Higgins J, Thomas J, Chandler J, Cumpston M, Li T, Page M, et al. *Cochrane Handbook for Systematic Reviews of Interventions* version 6.0 (updated July 2019). Cochrane. 2019. Available from [www.training.cochrane.org/handbook](http://www.training.cochrane.org/handbook).
- Al-Ashaal YH, Hefny AFS, Safi F, Abu-Zidan FM. Tension pneumothorax complicating endoscopic retrograde cholangiopancreatography: case report and systematic literature review. *Asian J Surg.* 2011;34(1):46–9. Published online April 26, 2011. [http://dx.doi.org/10.1016/S1015-9584\(11\)60018-3](http://dx.doi.org/10.1016/S1015-9584(11)60018-3). PubMed.
- Bartosz CK, Kovach A, Forssell K, Winter MK, Kothari S, Ullah A. Needle Knife Sphincterotomy for Biliary Access at ERCP: Experience At Two United States Academic Tertiary Referral Centers: 288. *Am J Gastroenterol.* 2014;109:S88. doi: <http://dx.doi.org/10.14309/0000434-201410002-00288>.
- Colemont LJ, Pelckmans P, Moorkens GH, Van Maercke YM. Unilateral periorbital emphysema: an unusual complication of endoscopic papillectomy. *Gastrointest Endosc.* 1988;34(6):473–5. [http://dx.doi.org/10.1016/S0016-5107\(88\)71440-6](http://dx.doi.org/10.1016/S0016-5107(88)71440-6). PubMed.
- Doerr RJK, Kulaylat MN, Booth FVC, Corasanti J. Barotrauma complicating duodenal perforation during ERCP. *Surg Endosc.* 1996;10(3):349–51. Published online March 01, 1996. <http://dx.doi.org/10.1007/BF00187390>. PubMed.
- Ferrara FL, Luigiano CB, Illi P, Jovine EC, Quantini FD, Imperio N. Pneumothorax, pneumomediastinum, pneumoperitoneum, pneumoretroperitoneum, and subcutaneous emphysema after ERCP. *Gastrointest Endosc.* 2009;69(7):1398–401. <http://dx.doi.org/10.1016/j.gie.2008.08.004>. PubMed.
- Fujii LL, Lau AF, Leischer DE, Harrison ME. Successful nonsurgical treatment of pneumomediastinum, pneumothorax, pneumoperitoneum, pneumoretroperitoneum, and subcutaneous emphysema following ERCP. *Gastroenterol Res Pract.* 2010;2010. Published online June 14, 2010. <http://dx.doi.org/10.1155/2010/289135>. PubMed.
- García-Cano JF, Ferri-Bataller RG, Gómez-Ruiz CJ. Common bile duct perforation sealed with a metal fully-covered stent. *Rev Esp Enferm Dig.* 2016;108(8):495–6. Published online August 25, 2016. PubMed.
- Garmon EH, Contreras E, Conley J. Tension pneumothorax and widespread pneumatosis after endoscopic retrograde cholangiopancreatography. *Anesthesiology.* 2013;119(3):699. <http://dx.doi.org/10.1097/ALN.0b013e31827bcd8a>. PubMed.
- Goddard AG, McConomy BB, Athla GF, Furqan MS, Silverman WB. Air leakage in multiple compartments after endoscopy. *Cleve Clin J Med.* 2016;83(10):705–7. Published online October 12, 2016. <http://dx.doi.org/10.3949/cjm.83a.15168>. PubMed.
- Greilich NB, Gasanova I, Farrell BJ, Joshi GP. The diagnosis and management of patient with delayed symptoms from a tracheal tear. *A A Case Rep.* 2016;6(8):230–3. <http://dx.doi.org/10.1213/XAA.0000000000000289>. PubMed.
- Gya DS, Sali AA, Angus D. Subcutaneous emphysema and pneumothorax following endoscopic sphincterotomy. *Aust N Z J Surg.* 1989;59(11):900–2. <http://dx.doi.org/10.1111/j.1445-2197.1989.tb07038.x>. PubMed.
- Han M-L, Wu Y-M, Liu K-L, Su W-C, Wang H-P. Tension pneumothorax after an ERCP in a patient with hepatic hydrothorax and sealed-off perforated duodenal ulcer. *Gastrointest Endosc.* 2008;68(4):771–2, discussion 772. <http://dx.doi.org/10.1016/j.gie.2008.03.007>. PubMed.
- Hui C-K, Lai K-C, Yuen M-F, Lam S-K. Tension pneumothorax complicating ERCP in a patient with a Billroth II gastrectomy. *Gastrointest Endosc.* 2001;54(2):254–6. <http://dx.doi.org/10.1067/mge.2001.114962>. PubMed.
- Iyilikci L, Akarsu MD, Duran ES, Sarikaya H, Bıyıklı B. Duodenal perforation and bilateral tension pneumothorax following endoscopic sphincterotomy. *J Anesth.* 2009;23(1):164–5. <http://dx.doi.org/10.1007/s00540-008-0710-7>. PubMed.
- Keber TM, Mojskerc K, Makuc J. Bilateral Pneumothorax and Subcutaneous Emphysema following Endoscopic Retrograde Cholangiopancreatography with Sphincterotomy. *Signa Vitae.* 2015;10(2):192–201. doi: <http://dx.doi.org/10.22514/SV102.122015.13>.
- Keskin KB, Şakurt MA, Türk F, Conkbayır C. A rare cause of chest pain mimicking myocardial infarction. *Türk Kardiyol Dern Ars.* 2014;42(5):472–4. <http://dx.doi.org/10.5543/tkda.2014.27163>. PubMed.
- Kocaman OS, Sipahi MC, Bucuk AB, Baykara ZN, Hülügü S. Porous diaphragm syndrome after ERCP in a patient with bile duct stricture. *Türk J Gastroenterol.* 2009;20(2):157–8. Published online June 17, 2009. PubMed.
- Kogure HW, Watabe HY, Yamada A, Sawayama HT, Sujino TN, Nagano R, Su S. Therapeutic ERCP Using Short Double-Balloon Enteroscopy in Patients With Surgically Altered Anatomy. *Gastrointest Endosc.* 2011;73(4):AB271. doi: <http://dx.doi.org/10.1016/j.gie.2011.03.509>.
- Lagoudianakis EE, Tsekouras DP, Papatima AG, Genetzakis MP, Pappas MG, Giannopoulos P. Pneumothorax complicating endoscopic sphincterotomy successfully treated conservatively. *Acta Gastroenterol Belg.* 2006;69(3):342–4. Published online December 16, 2006. PubMed.
- Linssen V, D'Tan ACITL, Schouten JA. Massive subcutaneous emphysema, unilateral pneumothorax, pneumomediastinum and pneumoperitoneum after endoscopic retrograde cholangiopancreatography. *Netherlands Journal of Critical Care.* 2013;17(4):16–8.
- Lopes TL, Clements RH, Wilcox CM. Laparoscopy-assisted ERCP: experience of a high-volume bariatric surgery center (with video). *Gastrointest Endosc.* 2009;70(6):1254–9. <http://dx.doi.org/10.1016/j.gie.2009.07.035>. PubMed.
- Lutchmansingh DR, Yu CA, Mzuta I. The Path Less Traveled: Bilateral Pneumothoraces as a Complication of Endoscopic Retrograde Cholangiopancreatography. *Chest.* 2013;144(4):494A. doi: <http://dx.doi.org/10.1378/chest.1671537>.
- Makni AC, Hebbi F, Ben Safta Z. Pneumoretroperitoneum, bilateral pneumothorax and emphysema following endoscopic biliary sphincterotomy. *Acta Chir Belg.* 2012;112(4):307–9. <http://dx.doi.org/10.1080/00015458.2012.11680844>. PubMed.
- Markogiannakis HT, Toutouzias KG, Pararas NV, Romanos A, Theodorou D, Bramis I. Bilateral pneumothorax following endoscopic retrograde cholangiopancreatography: a case report. *Endoscopy.* 2007;39(Suppl 1):. doi: <http://dx.doi.org/10.1080/00015458.2012.11680844>. PubMed.
- Morley APL, Lau JY, Young RJ. Tension pneumothorax complicating a perforation of a duodenal ulcer during ERCP with endoscopic sphinc-



- terotomy. *Endoscopy*. 1997;29(4):332 . <http://dx.doi.org/10.1055/s-2007-1004205>. PubMed.
- 32 Neofytou KPetrou ASavva CPetrides CAndreou CFelekouras E Pneumothorax following ERCP: Report of two cases with different pathophysiology. *Case Rep Med*. 2013;2013: . <http://dx.doi.org/10.1155/2013/206564>. PubMed.
- 33 Ozgonul ACEce HSogut ODemir DKurkcuoglus IC. Pneumoperitoneum, pneumoretroperitoneum and bilateral pneumothorax caused by ERCP. *J Pak Med Assoc*. 2010;60(1):60–1. Published online January 09, 2010. PubMed.
- 34 Plönes TReuland A-KPasslick B. Bilateral pneumothoraces, pneumomediastinum and subcutaneous emphysema as a rare complication of endoscopic cholangiopancreatography. *BMJ Case Rep*. 2012;2012(dec03 1): . <http://dx.doi.org/10.1136/bcr-2012-007412>. PubMed.
- 35 Rappaport DESolano JEdlow JA. Bilateral pneumothoraces as a complication of endoscopic retrograde cholangiopancreatography. *J Emerg Med*. 2017;52(4):573–5 . <http://dx.doi.org/10.1016/j.jemermed.2016.11.023>. PubMed.
- 36 Samies N3rdReidman DFraga D. Diffuse subcutaneous emphysema after endoscopic retrograde cholangiopancreatography with subsequent pneumothorax and pneumomediastinum. *Am Surg*. 2015;81(2):E67–9. PubMed.
- 37 Sampaziotis FWiles AShaik SDickinson RJ. Bilateral pneumothorax and subcutaneous emphysema following endoscopic retrograde cholangiopancreatography: a rare complication. *Diagn Ther Endosc*. 2010;2010: . Published online August 11, 2010 . <http://dx.doi.org/10.1155/2010/894045>. PubMed.
- 38 Savides TSherman SKadell BCryer HDerezin M. Bilateral pneumothoraces and subcutaneous emphysema after endoscopic sphincterotomy. *Gastrointest Endosc*. 1993;39(6):814–7 . [http://dx.doi.org/10.1016/S0016-5107\(93\)70273-4](http://dx.doi.org/10.1016/S0016-5107(93)70273-4). PubMed.
- 39 Scarlett PYFalk GL. The management of perforation of the duodenum following endoscopic sphincterotomy: a proposal for selective therapy. *Aust N Z J Surg*. 1994;64(12):843–6 . <http://dx.doi.org/10.1111/j.1445-2197.1994.tb04561.x>. PubMed.
- 40 Schepers NJvan Buuren HR. Pneumothorax following ERCP: report of four cases and review of the literature. *Dig Dis Sci*. 2012;57(8):1990–5. Published online March 31, 2012 . <http://dx.doi.org/10.1007/s10620-012-2150-3>. PubMed.
- 41 Schiavon LLRodrigues RANakao FSDi Sena VOFerrari APLibera EDJr. Subcutaneous emphysema, pneumothorax and pneumomediastinum following endoscopic sphincterotomy. *Gastroenterol Res*. 2010;3(5):216–8. Published online September 20, 2010 . <http://dx.doi.org/10.4021/gr232w>. PubMed.
- 42 Schilling MSailer ASHeinz GKutilek M. Intrathorakale Perforation von Gallenwegsstenosen bei St. p. Lebertransplantation. *RoFo Fortschr Geb Rontgenstr Nuklearmed*. 2014;186(9):887–8 . <http://dx.doi.org/10.1055/s-0033-1356313>. PubMed.
- 43 Seymann GBSavides TRichman KM. Massive subcutaneous emphysema after endoscopic retrograde cholangiopancreatography. *Am J Med*. 2010;123(9):e15–6 . <http://dx.doi.org/10.1016/j.amjmed.2009.12.040>. PubMed.
- 44 Shen T-CChen C-PChen C-H. An elderly woman with air leakage. *Intern Med*. 2015;54(5):533–4 . <http://dx.doi.org/10.2169/internalmedicine.54.3652>. PubMed.
- 45 Shimatani MMatsushita MTakaoka MKoyabu Mikeura TKato K Effective “short” double-balloon enteroscope for diagnostic and therapeutic ERCP in patients with altered gastrointestinal anatomy: a large case series. *Endoscopy*. 2009;41(10):849–54 . <http://dx.doi.org/10.1055/s-0029-1215108>. PubMed.
- 46 Song SYLee KSNa KJAhm BH. Tension pneumothorax after endoscopic retrograde pancreatocholangiogram. *J Korean Med Sci*. 2009;24(1):173–5. Published online March 10, 2009 . <http://dx.doi.org/10.3346/jkms.2009.24.1.173>. PubMed.
- 47 Brueck MBandorski DRauber KLotterer E. [Pneumoretroperitoneum and bilateral pneumothorax after endoscopic biliary sphincterotomy]. *Dtsch Med Wochenschr*. 2010;135(17):853–6 . <http://dx.doi.org/10.1055/s-0030-1253667>. PubMed.
- 48 Menéndez PPadilla DVillarejo PGarcía A. Neumoperitoneo, neumoretroperitoneo, neumotórax bilateral, neumomediastino y enfisema subcutáneo secundario a CPRE. *Rev Gastroenterol Peru*. 2012;32(1):94–7. [Spanish]. PubMed.
- 49 Valkovský JVrána JŠmíd JKraus JKovala PKremer M Neobvyklá komplikace ERCP. *Gastroenterologie a Hepatologie*. 2014;68:209–11. Czech. doi:<http://redakce.ambitmedia.cz/index.php/gh/article/view/410>
- 50 Ko CWLee SP. Epidemiology and natural history of common bile duct stones and prediction of disease. *Gastrointest Endosc*. 2002;56(6, Suppl):S165–9 . [http://dx.doi.org/10.1016/S0016-5107\(02\)70005-9](http://dx.doi.org/10.1016/S0016-5107(02)70005-9). PubMed.
- 51 Williams EJTaylor SFairclough PHamlyn ALogan RFMartin D Risk factors for complication following ERCP: results of a large-scale, prospective multicenter study. *Endoscopy*. 2007;39(9):793–801 . <http://dx.doi.org/10.1055/s-2007-966723>. PubMed.
- 52 Enns RELoubeidi MAMergener KJowell PSBranch MSPappas TM ERCP-related perforations: risk factors and management. *Endoscopy*. 2002;34(4):293–8 . <http://dx.doi.org/10.1055/s-2002-23650>. PubMed.
- 53 Cotton PBLEhman GVennes JGeenen JERussell RCGMeyers WC Endoscopic sphincterotomy complications and their management: an attempt at consensus. *Gastrointest Endosc*. 1991;37(3):383–93 . [http://dx.doi.org/10.1016/S0016-5107\(91\)70740-2](http://dx.doi.org/10.1016/S0016-5107(91)70740-2). PubMed.
- 54 Bhat MRomagnuolo Jda Silveira EReinhold CValois EMartel M Randomised clinical trial: MRCP-first vs. ERCP-first approach in patients with suspected biliary obstruction due to bile duct stones. *Aliment Pharmacol Ther*. 2013;38(9):1045–53 . <http://dx.doi.org/10.1111/apt.12481>. PubMed.
- 55 Chen QJin PJi XDu HLu J. Management of difficult or failed biliary access in initial ERCP: A review of current literature. *Clin Res Hepatol Gastroenterol*. 2019;43(4):365–72 . <http://dx.doi.org/10.1016/j.clinre.2018.09.004>. PubMed.
- 56 Maunder RJPierson DJHudson LD. Subcutaneous and mediastinal emphysema. *Pathophysiology, diagnosis, and management*. *Arch Intern Med*. 1984;144(7):1447–53 . <http://dx.doi.org/10.1001/archinte.1984.00350190143024>. PubMed.
- 57 Hartin DJKendall RBoyle AAAtkinson PRT. Case of the month: Buffalo chest: a case of bilateral pneumothoraces due to pleuropleural communication. *Emerg Med J*. 2006;23(6):483–6 . <http://dx.doi.org/10.1136/emj.2005.030981>. PubMed.
- 58 Howard TJTan TLehman GASherman SMadura JAFogel E Classification and management of perforations complicating endoscopic sphincterotomy. *Surgery*. 1999;126(4):658–63, discussion 664–5 . [http://dx.doi.org/10.1016/S0039-6060\(99\)70119-4](http://dx.doi.org/10.1016/S0039-6060(99)70119-4). PubMed.
- 59 Paspatis GADumonceanu J-MBarthet MMeisner SRepici ASaunders BP Diagnosis and management of iatrogenic endoscopic perforations: European Society of Gastrointestinal Endoscopy (ESGE) Position Statement. *Endoscopy*. 2014;46(8):693–711 . <http://dx.doi.org/10.1055/s-0034-1377531>. PubMed.
- 60 Leigh-Smith SHarris T. Tension pneumothorax—time for a re-think? *Emerg Med J*. 2005;22(1):8–16 . <http://dx.doi.org/10.1136/emj.2003.010421>. PubMed.
- 61 Machado NO. Management of duodenal perforation post-endoscopic retrograde cholangiopancreatography. When and whom to operate and what factors determine the outcome? A review article. *JOP*. 2012;13(1):18–25. PubMed.