

Endovascular stent-grafting for diseases of the descending thoracic aorta

M. Gerber, F. F. Immer, D. D. Do, T. Carrel, J. Schmidli

Clinic for Cardiovascular Surgery, Division of Angiology, University Hospital, Berne, Switzerland

Summary

Principles: Endoluminal stent-grafts are emerging as a less invasive alternative to conventional open surgery in the management of descending thoracic aortic dissections and aneurysms. We describe our experience with endovascular stent-grafting in the treatment of thoracic aorta pathology.

Methods: 17 Patients were treated with 23 endovascular stents. The underlying pathology was an atherosclerotic aneurysm verum ($n = 5$), a type B dissection with contained rupture ($n = 3$), an intramural haematoma with contained rupture ($n = 1$) and a false aneurysm of unknown origin ($n = 1$). One patient had Marfan's syndrome and six patients had a traumatic rupture of the descending aorta.

Results: Overall 23 stent-grafts were implanted. In one patient, conversion to an open graft replacement of the descending aorta was necessary. One patient died. In four patients (23.5%) a left carotid-subclavia bypass or transposition was per-

formed to achieve a sufficient neck for the proximal stent-graft landing zone. The postoperative control-CT scans revealed a total of six endoleaks (EL) (four type I, one type II and one type IV). Two patients needed a graft extension in a second operation (4 days and 18 month after the first operation), two EL (one type I and one type II) disappeared after 9 and 18 months, respectively and two EL are still under observation. One patient developed a paresis after conversion to open graft replacement.

Conclusions: A variety of diseases of the descending aorta can be treated by endoluminal stent-grafting, which seems to be a valid alternative to open repair in well selected cases. Mortality and morbidity in our small series were low. Continuous follow-up is mandatory.

Key words: endovascular; stent-graft; thoracic aorta; type B dissection; rupture

Introduction

Diseases of the descending thoracic aorta such as traumatic rupture, acute dissection, aneurysm and intramural haematoma (IMH) represent life-threatening conditions.

Aneurysms exceeding a maximum diameter of 6 cm are considered for surgery. Traumatic rupture is an indication for operation either immediately because of a free rupture with haemodynamic instability or later because of formation of a coarctation, a true or false aneurysm, a contained rupture or an expanding haematoma [1].

While the standard treatment of Stanford type B dissection is medical therapy, surgery can become necessary in patients with signs of impending rupture (persisting pain, uncontrollable hypertension, left sided haemothorax), visceral or leg ischaemia, renal failure, paraparesis or paraplegia [1]. Nonetheless, the current early mortality rate of type B dissection treated by medicaments/drugs remains high (20–40% mortality in the first year [2, 3]).

Although substantial progress in the perioperative management of aortic surgery has been made in the past years, mortality (5–20%) and morbidity rates still remain high. The major postoperative complications include myocardial infarction, respiratory failure, renal failure, stroke and paraparesis or paraplegia [1, 4–7].

The technique of endoluminal aortic stent-graft placement in abdominal aneurysms is now an established procedure. Although long-term results

Glossary

EL = Endoleak

IMH = Intramural haematoma

PAU = Penetrating atherosclerotic ulcer

ICU = Intensive care unit

AAA = Abdominal aortic aneurysm

have to validate the promising initial results, this method may become the new gold standard for selected patients and may be lifesaving in a contained rupture [8–10].

The use of endovascular stent-grafts in the thoracic aorta is less common than in AAA. The

first series of 13 patients was published in 1994 [11], followed by further publications with encouraging results [12–15]. The present report describes a single centre experience with endovascular stent-grafting in the treatment of descending thoracic aorta diseases.

Materials and methods

From 1/97 to 12/2001, 17 out of 72 patients (23.6%) presenting with a pathology limited to the descending aorta and who would require surgical treatment, were treated by endovascular stent-graft placement.

The underlying pathologies / patient data are summarised in table 1.

A total of 23 stents were used. 11 patients were initially treated with one stent graft, four patients

needed an immediate and two a delayed extension due to a proximal leak (type I EL), 4 and 15 month after the first intervention. In most cases we used a Talent® stent graft (Medtronic Inc., USA), in one case a Vanguard® stent graft (Boston Scientific Inc., USA), and in two cases a Thoracic Excluder® (Gore Inc., USA) was used.

Cardiovascular risk factors were mainly present in older patients. Eight patients suffered from

Table 1

Underlying pathologies and patient data.

Patient	age / sex	pathology	localisation of the lesion	stent graft *	time of surgery after trauma / admission	special
1	26/m	covered aortic rupture after trauma	directly distal to the origin of the left subclavian artery	Talent	10 days	open aortic arch reconstruction due to pseudocoarctation, false aneurysm of aortic arch, 4 days after stent
2	29/m	aneurysm increasing in size	directly distal to the origin of the left subclavian artery	Talent 28/102	elective 3 years after trauma	carotid-subclavian transposition
3	30/m	covered aortic rupture, pseudocoarctation, uncontrollable hypertension of the upper extremities	directly distal to the origin of the left subclavian artery	Talent 34/99 mm and Talent 24/91 mm	14 days	
4	31/m	contained rupture after trauma	3 cm distal to the origin of the subclavian artery	Talent 36/38 mm	14 days	
5	31/m	false aneurysm, peripheral embolism	distal aortic arch	Talent 28/102	elective, 10 years after trauma	carotid-subclavian transposition
6	32/m	Marfan's disease, replacement of aortic arch 7 days previously, leak at the distal anastomosis	distal aortic arch	Talent Thoracic LPS, 34/80 mm, 48 mm covered	7 days after aortic arch replacement	
7	33/m	covered aortic rupture, pseudocoarctation, uncontrollable hypertension of the upper extremities	directly distal to the origin of the left subclavian artery	Vanguard® 26/90mm	14 days	conversion to open surgery, replacement of the descending aorta with a dacron graft (Vascutec);
8	46/m	acute type B dissection, visceral malperfusion	entry tear directly distal to the origin of the left subclavian artery	Talent 40–42/97	1 day	
9	59/m	contained rupture after type B dissection, visceral malperfusion	6 cm distal to the origin of the left subclavian artery	2* Talent 2 stents;	36 h after aorto-visceral revascularisation	retrograde dissection into aortic arch; patient died
10	67/f	true aneurysm increasing in it's size	middle third of descending aorta	thoracic excluder	elective	iliac access through lumbotomy
11	69/m	true aneurysm increasing in size	middle third of descending aorta	talent	elective, 7 years after trauma	endoleak type I, disappeared after 18 month
12	70/f	acute contained type B rupture	5 cm distal to the origin of the left subclavian artery	talent	1 day	endoleak type I, under surveillance
13	74/f	intramural haematoma of the descending aorta	proximal third of descending aorta	Thoracic Excluder 100 mm	8 days	endoleak type II, disappeared spontaneously after 9 months
14	79/m	true aneurysm	directly distal to the origin of the left subclavian artery	2* Talent 34/99 (2 stents);	elective	carotid-subclavian transposition

Patient	age / sex	pathology	localisation of the lesion	stent graft *	time of surgery after trauma / admission	special
15	79/m	false aneurysm of unknown aetiology	distal aortic arch	2* Talent (2 Stents);	elective	carotid-subclavian bypass endoleak Type IV, under surveillance
16	80/f	contained rupture of a true aneurysm	distal third of descending aorta	Talent 38/100 mm, Talent 38/98 mm	2 days and 6 days	endoleak type I, successful overstenting after 4 days. iliac access through lumbotomy
17	80/m	true aneurysm increasing in size	middle third of descending aorta	2* Talent (2 Stents);	elective 2 nd stent after 15 months	endoleak type I; reoperation (stent); after 15 months

* Talent,, Medtronic Inc., USA; Vanguard,, Boston Scientific Inc., USA; Thoracic Excluder,, Gore Inc., USA; Vascutec,, Sulzer, UK

arterial hypertension, four were smokers and three had elevated blood cholesterol. One patient had coronary heart disease.

Endovascular procedure

15 procedures were carried out under general anaesthesia (89.4%), one in peridural and one in local anaesthesia. The intervention was performed in the operating room by a team consisting of a cardiovascular surgeon, an interventional angiologist and / or an interventional radiologist. Femoral artery access was achieved in 15 patients (mainly the right femoral artery). In two patients the femoral artery was either too small or diseased. Iliac graft access was then achieved through a retroperitoneal approach. In patient #16 a second stent was in-

serted four days later due to a type I endoleak, using the same access [16].

In 12 cases (70.5%) a supplementary diagnostic catheter was used for proper device positioning and delivery using intermittent contrast angiography. In 10 patients the catheter was introduced through the brachial artery (seven from the right side, three from the left side). In two patients the contralateral femoral artery was punctured.

In all patients 70 IE Heparin per kilogram body weight was administered intravenously. The stent-graft system was inserted through a transverse arteriotomy and positioning of the graft was achieved under fluoroscopy. Before releasing the device mean arterial pressure was lowered to 50–60 mm Hg using stepwise perlinganit [17].

Figure 1

Angiography of the aneurysm.

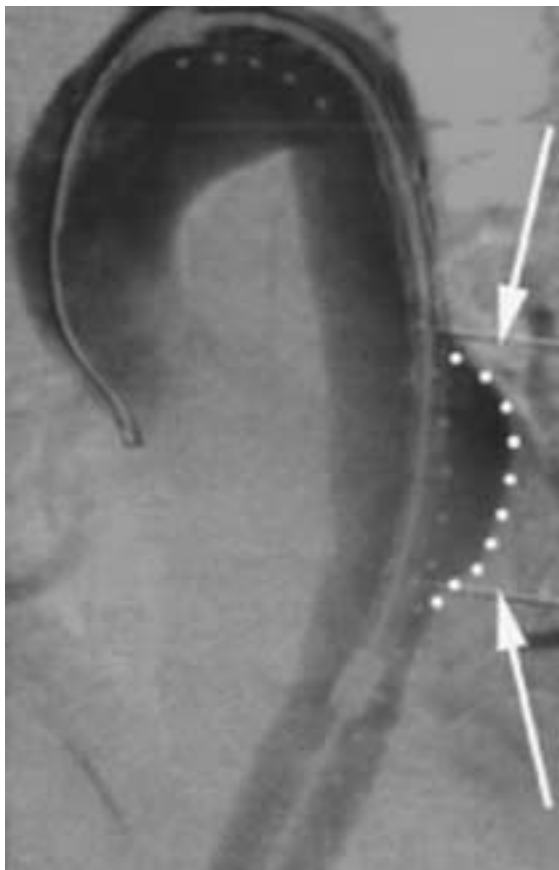


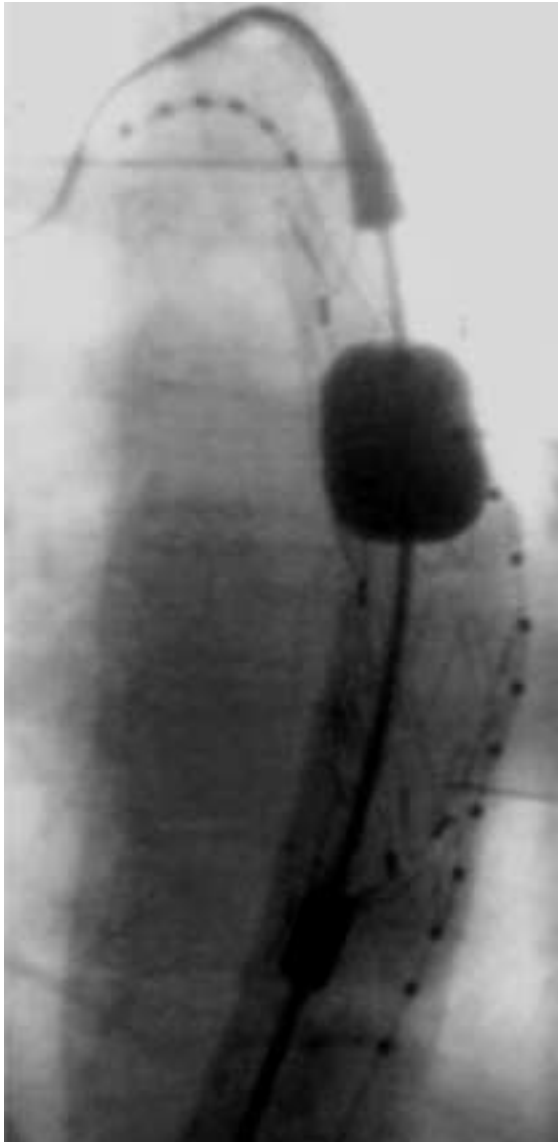
Figure 2

Angiography while placing the stent.

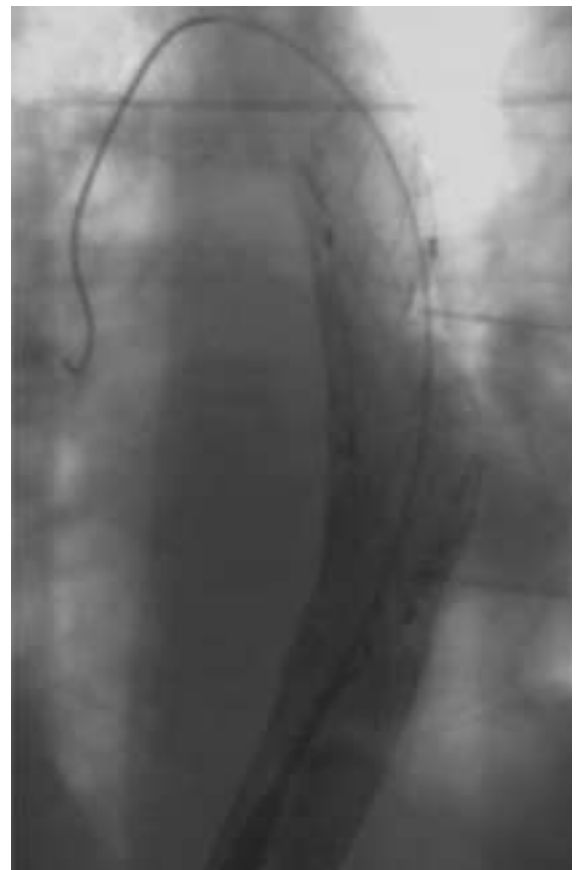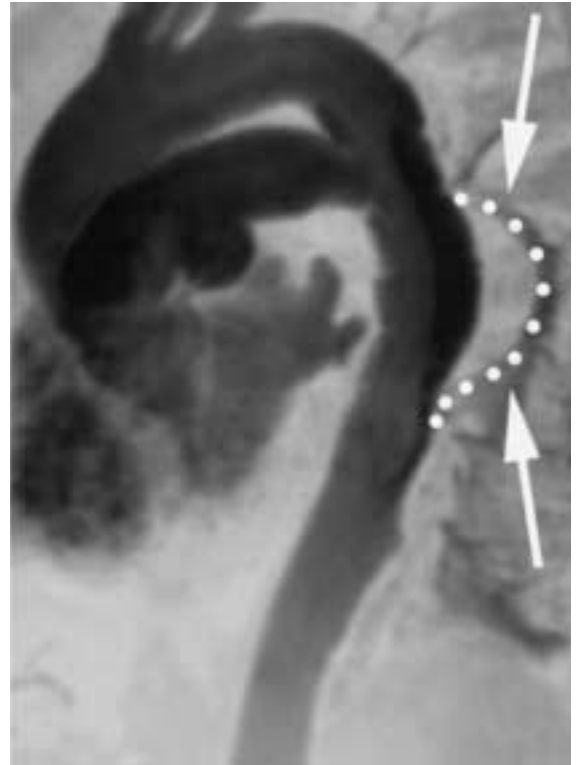


Figure 3

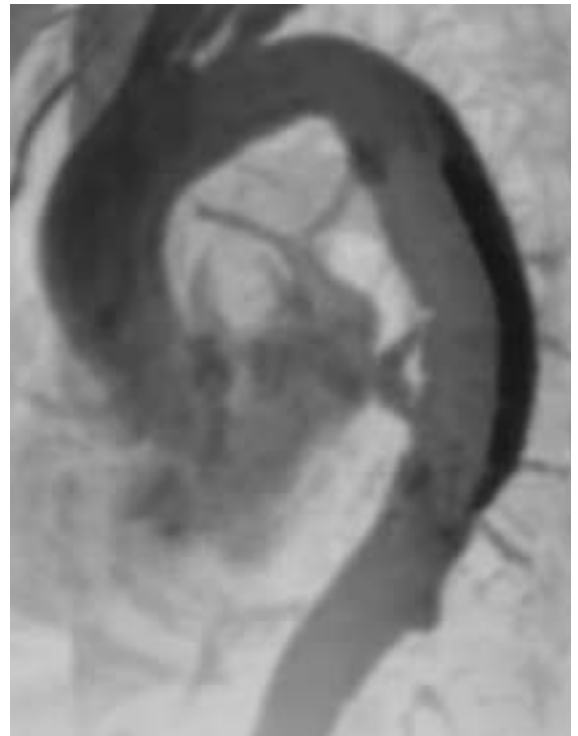
Modelling of the stent by the balloon.

**Figure 4**

Angiography of the excluded aneurysm.

**Figure 5**

MRI of the excluded aneurysm.

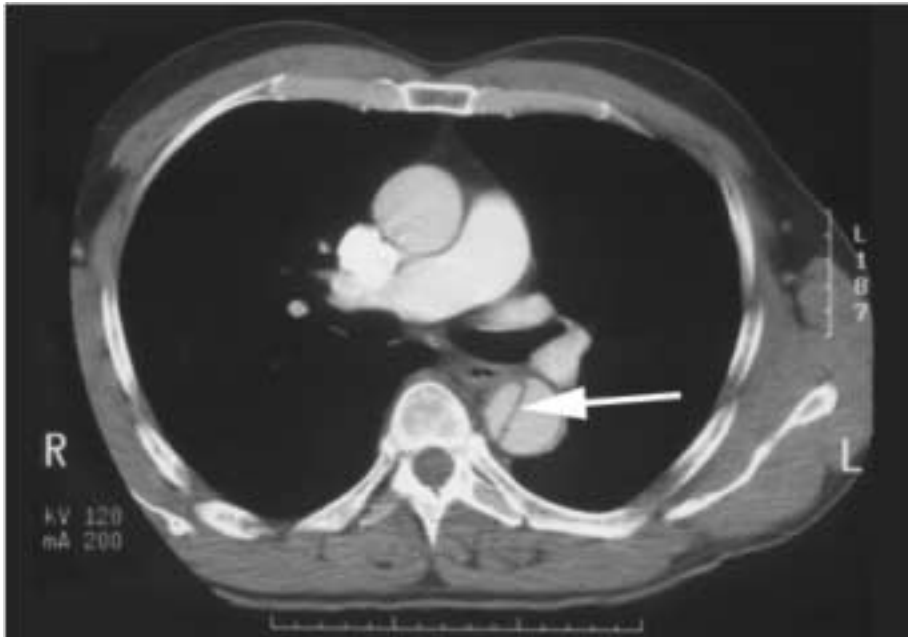

In four patients (23.5%) the origin of the left subclavian artery was overstented to achieve a sufficient neck for the proximal landing zone of the stent-graft. Therefore the subclavian revascularisation procedure was performed directly before endovascular stent deployment (two subclavian-carotid transpositions, two carotid-subclavian bypass using either a saphenous vein graft or 6 mm PTFE graft).

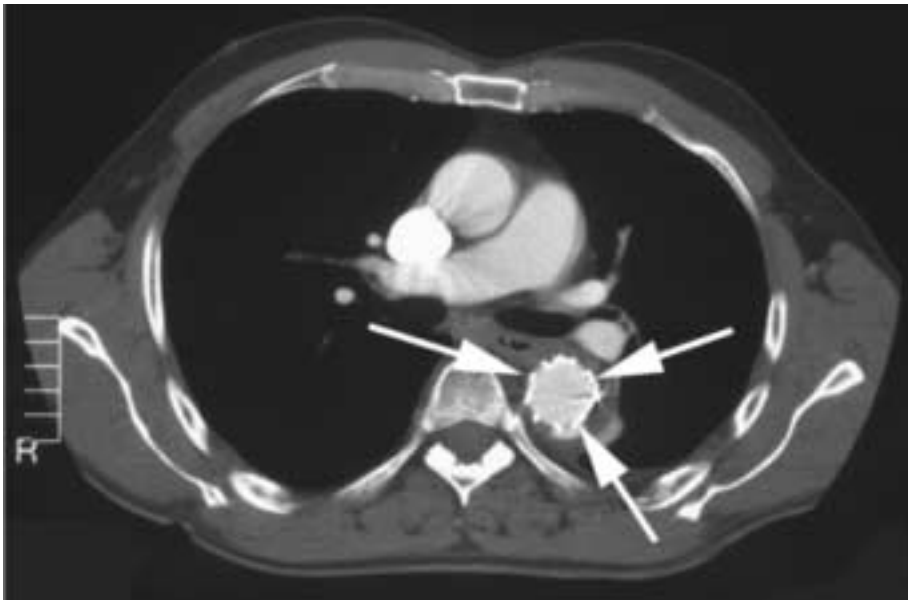
At the end of the procedure control angiography was performed. Routine surveillance included conventional radiographs in two projections and contrast-enhanced spiral CT scans prior to discharge and at 3, 6, 12, 18 and 24 month postoperatively and yearly thereafter. In patients, in whom placement of the stent was possible (16/17 = 94.1% with one conversion to open surgery), average operation time was 157 minutes (range from 60 to 350 minutes).

Figure 6

CT of acute type B dissection.

**Figure 7**

Successful stenting of the dissection.



Results

Technical success, defined as a perfect stent graft delivery and no primary endoleak, was achieved in 13 patients (76%). Early mortality was 5.8% (one patient). The following problems were observed:

1. Patient #7 had to be converted to open graft replacement because of stent kinking during delivery and overstenting of the left subclavian artery. The stent was removed and the proximal third of the descending aorta was replaced. The operation was performed with partial left heart bypass in mild hypothermia (32°C). Postoperatively the patient suffered from a transient paresis of the left leg and a persistent left recurrent nerve palsy.
2. In patient #11 a type I endoleak could not be eliminated despite balloon re-modelling. The endoleak disappeared 18 months after the operation spontaneously.
3. In patient #16 the leaking aneurysm was incompletely excluded. Another stent for distal extension was not available. In a second operation four days later distal extension was completed. Postoperative course was free of complications.
4. Patient #9 with acute type B dissection developed acute visceral ischaemia. Fenestration of the infrarenal abdominal aorta, re-vascularisation of the coeliac trunk and the superior mesenteric artery, hemicolectomy and cholecystectomy were performed. The following day, the proximal descending aorta began to leak. As the patient was not suitable for surgery, a stent implantation was considered to be

adequate treatment. Intraoperative TEE revealed a retrograde dissection into the aortic arch, which could not be sealed by two endovascular stents. Due to the poor general condition, medical treatment was discontinued and the patient died.

No persistent paraparesis / paraplegia, distal embolisation or other major complications occurred. One patient required neck revision due to a lymphatic fistula after subclavia-carotid bypass. One inguinal haematoma had to be evacuated and one inguinal infection had to be treated surgically. No renal failure was encountered and all patients were discharged with a serum creatinin corresponding to the preoperative value.

The average ICU stay was 4.3 days (0–23 days), including the three patients with multiple other injuries due to accidents. The patients were discharged after a median stay of 11, 6 days (7–34 days). Ten patients were discharged home, three to a rehabilitation clinic and three to a regional hospital.

Endoleaks

Two out of 15 patients showed a type I endoleak in the control angiography. Postoperative CT scans revealed another four endoleaks. One type I endoleak was sealed by distal extension four days later and one disappeared after 18 months of surveillance. Of the four newly detected endoleaks, two were type I, one type II and one type IV. In a type I endoleak, a reduction of the size of the endoleak was observed in control CT scans postoperatively and is still under observation. In another patient the type I EL was treated 18 months after first stent implantation with a new stent-graft placement for distal extension. The diameter of the aneurysm sac had increased. One type II endoleak disappeared after 9 months of surveillance. In the patient with type IV endoleak the aneurysm remained stable in size four months postoperatively and is still under observation. All endoleaks were observed in elderly patients. No late rupture occurred. The median follow-up by CT scans was 13.2 months (range 0–36 months). The clinical follow up is 18.6 months range (0–43 months).

Discussion

In 1991 the first successful implantation of an endovascular stent graft in a patient with abdominal aneurysm was described by Parody et al. [18]. This success encouraged surgeons all over the globe to investigate the feasibility of thoracic aortic repair with transluminally placed endovascular stents. The first report of a successful thoracic aortic repair with an endovascular stent originates from Dake et al. in 1994 [11]. Recent publications reported encouraging results, but nevertheless some concerns and drawbacks remain [7, 12–15].

The selection of possible candidates for an endovascular treatment has to be made carefully. Three major factors have to be considered: 1) the location and morphology of the aortic lesion, 2) the suitability of the vascular access and 3) the procedure limiting tortuosity of the abdominal and thoracic aorta.

The results in the present series are promising, especially in younger patients with traumatic rupture of the descending aorta. In this group of patients the technical difficulties concerning the vascular access are negligible and endovascular aortic repair can be performed even in patients with multiple injuries, including brain injury or bleeding disorders.

Emergent or early endovascular stent grafting for traumatic rupture of the thoracic aorta showed promising results. Lachat et al. [8] reported a series of 12 patients with 11 survivors, despite various additional severe concomitant lesions. Even in patients with brain injury, or liver and kidney lacerations, which represent a contraindication for open surgical repair, were successfully treated with

stent grafts and survived. Endovascular treatment of aortic lesions close to the aortic isthmus does not seem to have a larger risk of postoperative paraplegia, when compared to open surgical repair in acute thoracic aortic rupture [19]. The reason for this is probably the frequent location of the lesion within the proximal descending thoracic aorta.

Another indication for endovascular repair may be an intramural haematoma (IMH) in the descending aorta with or without a penetrating atherosclerotic ulcer (PAU). The difficulty with this pathology resides in the fact that the exact origin of the intramural bleeding can not always be easily verified. Ganaha et al [20] recently claimed both symptoms and radiological findings, such as recurrent pain, pleural effusion and both size and depth of the ulcer-like projection to be predictive of disease progression and therefore of a risk to the patient. Von Kodolitsch and Nienaber described the natural course of patients with IMH in a meta-analysis [21, 22]. Typical IMH without PAU led to overt aortic dissection in 12% of descending IMH, ended in aortic rupture in 9% or in stabilisation in 76%. 30-day mortality after open surgery was 18% with repair of proximal IMH and 33% with repair of distal IMH, compared with 60% and 8% in-hospital mortality with medical treatment of proximal and distal IMH, respectively.

Determination of the so-called “landing zones” for safe proximal and distal graft attachment is absolutely essential. A minimum of 1.5 cm to 2 cm of normal aorta is required to anchor the stent. If the lesion is close to the level of the left

subclavian artery and if the stent has to be placed within the aortic arch, prior revascularisation of the left subclavian artery has to be considered. In case of intentional covering of the left subclavian artery origin to increase the proximal landing zone, either a carotid-subclavian bypass or a subclavian-carotid transposition was used to restore subclavian artery blood flow. In contrary to a recent publication by Goerich et al. [23] in which 78, 5% of 23 patients reported no postinterventional complaints and therefore revascularisation was not considered to be primarily necessary, we believe that by covering the origin of the subclavian artery we prevent at least type II endoleaks. Whether this can be achieved by merely inserting an endovascular on-plug stent graft instead of ligation of the LSA during the revascularisation procedure has yet to be proven. Increasing the landing zone into the aortic arch but leaving a large branch open as a potential type II EL source does not seem to make sense.

The role of stent grafts in acute type B dissections at this time is not clear. Several reports [24–28] have demonstrated the use of endovascular techniques for the treatment of complication in aortic dissection. It seems to make sense that aortic wall and diameter behaviour would be more favourably influenced by early covering of the intimal entry tear leading to re-pressurisation of the true lumen. On the other hand, acute clotting of the false lumen may cause visceral and spinal cord ischaemia. However, prospective trials with endovascular stent grafting of the acute dissected descending aorta have to be awaited before any conclusions can be drawn.

To introduce the stent successfully a suitable access has to be available. The femoral artery served as access in 15 patients (88%). In two cases (both women) a lumbotomy was necessary to provide iliac graft access since the femoral artery diameter was too small [16]. Careful preoperative investigations are required – either with ultrasound or angiography – to choose optimal access. Further miniaturisation of the stent delivery systems should allow the introduction of the stent through the femoral artery in most cases.

The use of a second angiography catheter can be very helpful, either to determine the origin of the subclavian artery exactly or to identify the true

and the false lumen of a dissection. In type B dissection it is imperative to verify the entry tear near the subclavian artery very precisely to allow a perfect stent placing. Intravascular ultrasound (IVUS) and trans-oesophageal echocardiography (TEE) are helpful for accurate stent placement, although the TEE probe can interfere visually at the aortic arch.

Although described by some authors [29], we did not encounter paraplegia after successful stent implantation in our patients. The patient who had to be converted suffered from a transient paresis of one leg. The lack of the need for aortic cross-clamping and circulatory arrest compared to open surgery are considered to be major advantages in preventing ischaemic paraplegia.

A well-known and so far unsolved problem is the appearance of endoleaks. In 6 of 15 patients endoleaks were detected, making the incidence a high 40%. Although two EL disappeared spontaneously (after 9 respectively 18 months), two needed a second intervention and two are still under surveillance. Since type I EL is a significant risk factor for late rupture in endovascular repair of AAA, the same must be assumed in thoracic aneurysms [30]. Whereas completion angiography showed an EL in only two patients, postoperative CT scan detected four more ELs. As we are reluctant to take a patient back to the OR immediately for open conversion, we tend to keep the EL under surveillance and hope that it will disappear spontaneously. Interestingly in the follow-up CT scans no new endoleaks developed.

When choosing an endovascular stent-graft procedure, the problems and limitations of this treatment have to be considered. Results of successful treatment of traumatic aortic rupture or of leaking aneurysms have shown that stent-grafts can be life saving. Although the withdrawal of a commercially available stent-graft because of spine breakages in one single stent can be understood from the point of view of the company, from the point of view of the patient in an urgent, life threatening situation it is a pity. When treating patients on an elective basis for aneurysm or dissection, issues of material stability, increasing aortic diameter in the natural course and potential endoleak appearance have to be considered.

Conclusion

In conclusion, endovascular stent-grafting of the descending aorta is a promising alternative technique to open surgery in well selected patients. Older patients profit from a minimal invasive procedure and regional anaesthesia. In younger patients with a completely different pathology, the results are excellent. Both patient selection and the technical development of the stent graft system itself have to be optimized in order to improve clin-

ical results in the future. However, studies with larger series of patients and longer follow-up periods are highly desirable to confirm these early positive results and evaluate this new technique in the treatment of diseases of the descending thoracic aorta. A defined, closely matched control of these patients has to be done. Until this is available, our approach will remain cautious.

Endoleak Classification [31]

- Type I: Endoleak related to the stent graft device itself, mostly due to an insufficient sealing of the proximal or distal part of the stent.
- Type II: Retrograde flow from collateral branches (lumbar, inferior mesenteric).
- Type III: Endoleak due to fabric tears, graft wall defect, modular disconnection or disintegration
- Type IV: Flow through the graft presumed to be associated with graft wall “porosity”, endotension.

Correspondence:

J. Schmidli

Clinic for Cardiovascular Surgery

University Hospital Berne

CH-3010 Berne

E-Mail: juerg.schmidli@insel.ch

References

- 1 Kouchoukos N, Dougenis D. Surgery of the thoracic aorta. *N Engl J Med* 1997;336:1876–88.
- 2 Elefteriades JA, Hartleroad J, Gusberg RJ, Salazar AM, et al. Long-term experience with descending aortic dissection: the complication-specific approach. *Ann Thorac Surg* 1992;53: 11–21.
- 3 Pressler V, McNamara JJ. Thoracic aortic aneurysm: natural history and treatment. *J Thorac Cardiovasc Surg* 1980;79: 489–98.
- 4 Schepens M, Defauw J, Hamerlijck R, De Geest R, Vermeulen F. Surgical treatment of thoracoabdominal aortic aneurysms by simple cross-clamping. Risk factors and late results. *J Thorac Cardiovasc Surg* 1994;107: 134–42.
- 5 Svensson L, Crawford E, Hess KR, Coselli JS, Safi HJ. Variables predictive of outcome in 832 patients undergoing repairs of the descending thoracic aorta. *Chest* 1993;104: 1248–53.
- 6 Rectenwald JE, Huber TS, Martin TD, Ozaki CK, et al. Functional outcome after thoracoabdominal aortic aneurysm repair. *J Vasc Surg* 2002;35: 640–7.
- 7 Heijmen RH, Deblier IG, Moll FL, Dossche KM, et al. Endovascular stent-grafting for descending thoracic aortic aneurysms. *Eur J Cardio-thorac Surg* 2002;21:5–9.
- 8 Lachat M, Pfammatter T, Witzke H, Bernard E, Wolfensberger U, Künzli A, Turina M. Acute traumatic aortic rupture: early stent-graft repair. *Eur J Cardio-thorac Surg* 2002;21:959–63.
- 9 Morgan R, Loosemore T, Belli AM. Endovascular repair of contained rupture of the thoracic aorta. *Cardiovasc Intervent Radiol* 2002;25:291–4.
- 10 Duda SH, Pusich B, Raygrotzki S, Uckmann FP, et al. Endovascular implantation of stent-grafts in the thoracic aorta – mid-term results of a prospective controlled study. *Rof Fortschr Geb Rontgenstr Neuen Bildgeb Verfahr* 2002;174: 485–9.
- 11 Dake MD, Miller DC, Semba CP, Mitchell RS, Walker PJ, Liddell RP. Transluminal placement of endovascular stent-grafts for the treatment of descending thoracic aortic aneurysms. *N Engl J Med* 1994;331:1729–34.
- 12 Grabenwoger M, Hutschala D, Ehrlich MP, Cartes-Zumelzu F, et al. Thoracic aortic aneurysms: Treatment with endovascular self-expandable stent grafts. *Ann Thorac Surg* 2000;69:441–5.
- 13 Nienaber CA, Fattori R, Lund G, Dieckmann C, et al. Non surgical reconstruction of thoracic aortic dissection by stent graft implantation. *N Engl J Med* 1999;340:1539–45.
- 14 Dake MD, Kato N, Mitchell RS, Semba CP, et al. Endovascular stent graft placement for the treatment of acute aortic dissection. *N Engl J Med* 1999;340:1546–52.
- 15 Bortone AS, Schena S, Mannatrizio G, Paradiso V, et al. Endovascular stent-graft treatment for diseases of the descending thoracic aorta. *Eur J Cardio-thorac Surg* 2001;20:514–9.
- 16 Schmidli J, Do DD, Triller J, Widmer MK, Savolainen H, Carrel T. Iliac graft access to facilitate endovascular repair of a ruptured thoracic aortic aneurysm. *Vasc Endovasc Surg* 2002;36/3: 237–9.
- 17 Lachat ML, Pfammatter T, Witzke HJ, Bettex D, Kunzli A, et al. Endovascular repair with bifurcated stent-grafts under local anaesthesia to improve outcome of ruptured aortoiliac aneurysms. *Eur J Vasc Endovasc Surg* 2002;236:528–36.
- 18 Parodi JC, Palmaz JC, Barone HD. Transfemoral intraluminal graft implantation for abdominal aortic aneurysms. *Ann Vasc Surg* 1991;5:49–59.
- 19 Kato N, Dake MD, Miller DC, et al. Traumatic thoracic aortic aneurysm: treatment with endovascular stent-grafts. *Radiology* 1997;205:657–62.
- 20 Ganaha n, Fumikiyo n, Miller n, Craig n, et al. Prognosis of aortic intramural hematoma with and without penetrating atherosclerotic ulcer: A Clinical and Radiological Analysis. *Circulation* 2002;106:342–8.
- 21 Von Kodolitsch Y, Nienaber CA. Intramural hemorrhage of the thoracic aorta: Natural history, diagnostic and prognostic profiles of 209 cases with in vivo diagnosis [Abstract]. *Z Kardiol* 1998;87 797–807.
- 22 Von Kodolitsch Y, Nienaber CA. Penetrating ulcer of the thoracic aorta: natural history, diagnostic, and prognostic profiles [Abstract]. *Z Kardiol* 1998;87: 917–27.
- 23 Goerlich J, Asquan Y, Seifarth H, Kramer S, et al. Initial experience with intentional stent-graft coverage of the subclavian artery during endovascular thoracic aortic repairs. *J Endovasc Ther* 2002;9: 39–43.
- 24 Marty-Ané CH, Alric P, Prudhomme M, Chircop R, Serres-Cousiné O, Mary H. Intravascular stenting of traumatic abdominal aortic dissection. *J Vasc Surg* 1996;23/1: 156–61.
- 25 Walker PJ, Dake MD, Mitchell RS, Miller DC. The use of endovascular techniques for the treatment of complications of aortic dissection. *J Vasc Surg* 1993;18: 1042–51.
- 26 Slonim SM, Nyman UR, Semba CP, Miller DC, Mitchell RS, Dake MD. True lumen obliteration in complicated aortic dissection: endovascular treatment. *Radiology* 1996;201:161–6.
- 27 Kato N, Shimono T, Hirano T, Suzuki T, et al. Midterm results of stent-graft repair of acute and chronic aortic dissection with descending tear: the complication-specific approach. *Thorac Cardiovasc Surg* 2002;124: 306–12.
- 28 Slonim SM, Nyman U, Semba CP, Miller DC, Mitchell RS, Dake MD. Aortic dissection: Percutaneous management of ischemic complications with endovascular stents and balloon fenestration. *J Vasc Surg* 1996;23/2: 241–53.
- 29 Mitchell RS, Dake MD, Semba CP, Fogarty TJ, et al. Endovascular stent-graft repair of thoracic aortic aneurysms. *J Thorac Cardiovasc Surg* 1996;111:1054–62.
- 30 Criado FJ, Clark NS, Barnatan MF. Stent graft repair in the aortic arch and descending thoracic aorta: A 4-year experience. *J Vasc Surg* 2002;36/6: 1121–28.
- 31 White GH, May J, Waugh RC, Chaufour X, Yu W. Type III and type IV endoleak: toward a complete definition of blood flow in the sac after endoluminal AAA repair. *J Endovasc Surg* 1998;5: 305–9.

The many reasons why you should choose SMW to publish your research

What Swiss Medical Weekly has to offer:

- SMW's impact factor has been steadily rising, to the current 1.537
- Open access to the publication via the Internet, therefore wide audience and impact
- Rapid listing in Medline
- LinkOut-button from PubMed with link to the full text website <http://www.smw.ch> (direct link from each SMW record in PubMed)
- No-nonsense submission – you submit a single copy of your manuscript by e-mail attachment
- Peer review based on a broad spectrum of international academic referees
- Assistance of our professional statistician for every article with statistical analyses
- Fast peer review, by e-mail exchange with the referees
- Prompt decisions based on weekly conferences of the Editorial Board
- Prompt notification on the status of your manuscript by e-mail
- Professional English copy editing
- No page charges and attractive colour offprints at no extra cost

Editorial Board

Prof. Jean-Michel Dayer, Geneva
 Prof. Peter Gehr, Berne
 Prof. André P. Perruchoud, Basel
 Prof. Andreas Schaffner, Zurich
 (Editor in chief)
 Prof. Werner Straub, Berne
 Prof. Ludwig von Segesser, Lausanne

International Advisory Committee

Prof. K. E. Juhani Airaksinen, Turku, Finland
 Prof. Anthony Bayes de Luna, Barcelona, Spain
 Prof. Hubert E. Blum, Freiburg, Germany
 Prof. Walter E. Haefeli, Heidelberg, Germany
 Prof. Nino Kuenzli, Los Angeles, USA
 Prof. René Lutter, Amsterdam, The Netherlands
 Prof. Claude Martin, Marseille, France
 Prof. Josef Patsch, Innsbruck, Austria
 Prof. Luigi Tavazzi, Pavia, Italy

We evaluate manuscripts of broad clinical interest from all specialities, including experimental medicine and clinical investigation.

We look forward to receiving your paper!

Guidelines for authors:

http://www.smw.ch/set_authors.html

Impact factor Swiss Medical Weekly



All manuscripts should be sent in electronic form, to:

EMH Swiss Medical Publishers Ltd.
 SMW Editorial Secretariat
 Farnsburgerstrasse 8
 CH-4132 Muttenz

Manuscripts: submission@smw.ch
 Letters to the editor: letters@smw.ch
 Editorial Board: red@smw.ch
 Internet: <http://www.smw.ch>