

**SMW**

Established in 1871

# Swiss Medical Weekly

Formerly: Schweizerische Medizinische Wochenschrift

An open access, online journal • [www.smw.ch](http://www.smw.ch)

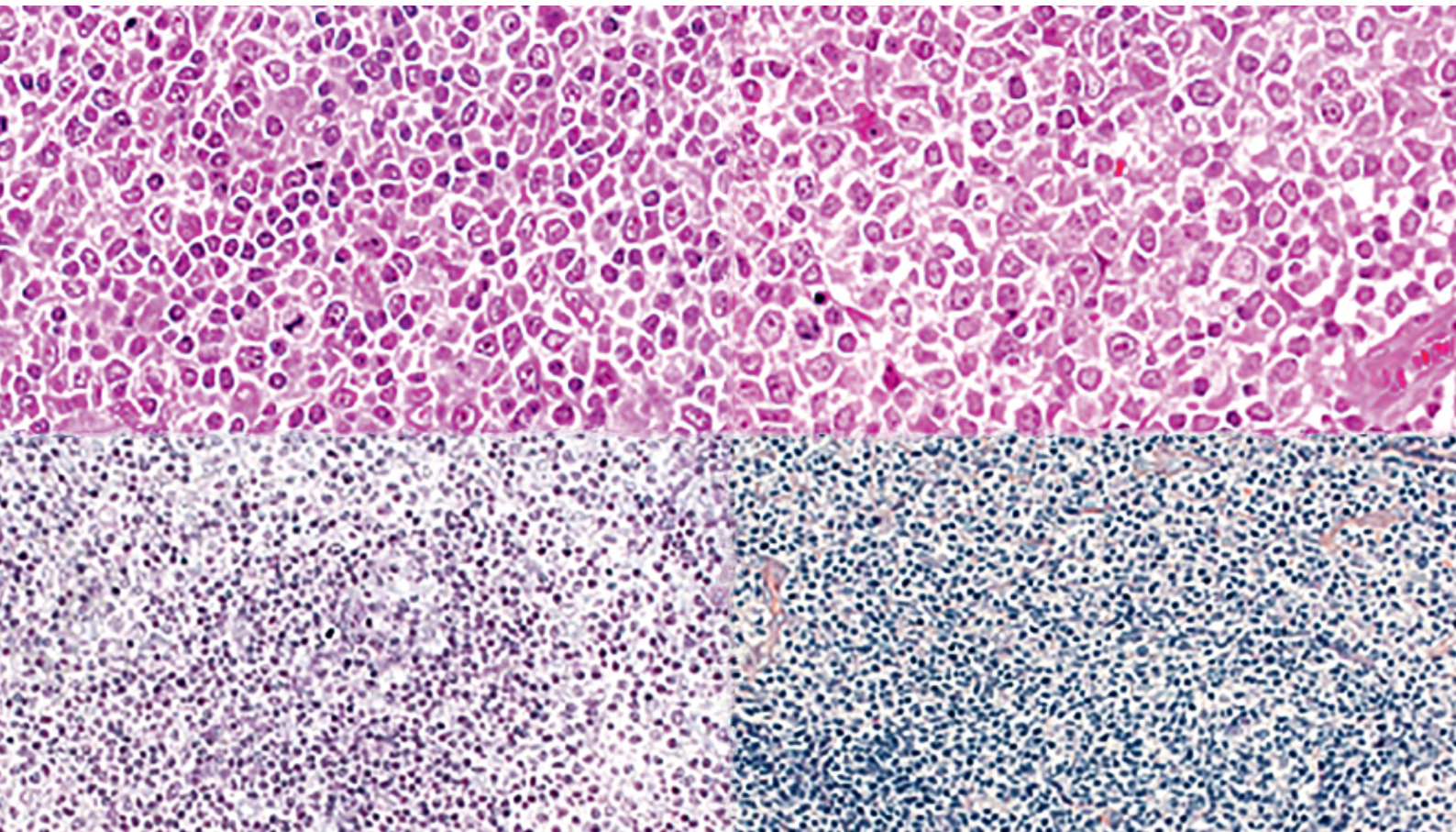
**Supplementum 216**

ad Swiss Med Wkly

2016;146

August 9, 2016

## Diagnosis and treatment of marginal zone lymphoma



The preparation and the publication of this article were supported by Roche Pharma (Schweiz) AG, Reinach, Switzerland, the manufacturer and local distributor of rituximab (MabThera®). The article was evaluated and sent for external peer review by the Swiss Medical Weekly editorial board.

---

## Impressum

### Editorial board:

Prof. Adriano Aguzzi, Zurich (ed. in chief)  
Prof. Manuel Battegay, Basel  
Prof. Jean-Michel Dayer, Geneva  
Prof. Douglas Hanahan, Lausanne  
Prof. Beat Müller, Aarau  
Prof. André P. Perruchoud, Basel  
(senior editor)  
Prof. Christian Seiler, Berne  
Prof. Peter Suter, Genève (senior editor)

### Head of publications

Natalie Marty, MD (nmarty@emh.ch)

### Papers administrator

Gisela Wagner (gwagner@emh.ch)

© EMH Swiss Medical Publishers Ltd. (EMH), 2016. The Swiss Medical Weekly is an open access publication of EMH. Accordingly, EMH grants to all users on the basis of the Creative Commons license "Attribution – Non commercial – No Derivative Works" for an unlimited period the right to copy, distribute, display, and perform the work as well as to make it publicly available on condition that (1) the work is clearly attributed to the author or licensor (2) the work is not used for commercial purposes and (3) the work is not altered, transformed, or built upon. Any use of the work for commercial purposes needs the explicit prior authorisation of EMH on the basis of a written agreement.

### All communications to:

EMH Swiss Medical Publishers Ltd.  
Swiss Medical Weekly  
Farnsburgerstrasse 8  
CH-4132 Muttenz, Switzerland  
Phone +41 61 467 85 55  
Fax +41 61 467 85 56  
office@smw.ch

### Listed in:

Index Medicus / MEDLINE  
Web of science  
Current Contents  
Science Citation Index  
EMBASE

### Guidelines for authors

The Guidelines for authors are published on our website [www.smw.ch](http://www.smw.ch)  
Submission to this journal proceeds totally on-line: [www.smw.ch](http://www.smw.ch)

ISSN printed version: 1424-7860  
ISSN online version: 1424-3997

# Diagnosis and treatment of marginal zone lymphoma

Sergio Cogliatti<sup>a\*</sup>, Mario Bargetzi<sup>b</sup>, Francesco Bertoni<sup>c,d</sup>, Felicitas Hitz<sup>e</sup>, Andreas Lohri<sup>f</sup>, Ulrich Mey<sup>g</sup>, Alexandros Papachristofilou<sup>h</sup>, Christian Taverna<sup>i</sup>, Emanuele Zucca<sup>c\*</sup>, Christoph Renner<sup>i\*</sup>

<sup>a</sup> Institute of Pathology, Kantonsspital St. Gallen, Switzerland; <sup>b</sup> Oncology-Haematology, Kantonsspital Aarau, Switzerland; <sup>c</sup> IOSI Oncology Institute of Southern Switzerland, Bellinzona, Switzerland; <sup>d</sup> Lymphoma and Genomics Research Programme, IOR Institute of Oncology Research, Bellinzona, Switzerland; <sup>e</sup> Oncology-Haematology, Kantonsspital St. Gallen, Switzerland; <sup>f</sup> Oncology-Haematology, Kantonsspital Baselland, Liestal, Switzerland; <sup>g</sup> Oncology and Haematology, Kantonsspital Graubünden, Chur, Switzerland; <sup>h</sup> Radio-Oncology, Universitätsspital Basel, Switzerland; <sup>i</sup> Oncology, Kantonsspital Münsterlingen, Switzerland; <sup>j</sup> Onkozentrum Hirslanden & Zürich, Zürich, Switzerland

\*SC, EZ, and CR contributed equally to this manuscript

## Summary

Marginal zone B-cell lymphoma (MZL) comprises three distinct entities, namely extranodal MZL of mucosa-associated lymphoid tissue (MALT lymphoma), nodal MZL and splenic MZL. Although these three diseases are somewhat related by their histogenetic origins, each displays its own clinical and biological characteristics that are reflected in the individual diagnosis, therapy and outcome. The rarity and heterogeneity of MZL have greatly hampered patient management and therefore no clear guidelines are available on the optimal treatment regimens. This review discusses the main features, diagnosis and treatment of these MZL subtypes.

**Key words:** marginal zone lymphoma; extranodal marginal zone lymphoma; mucosa-associated lymphoid tissue; splenic marginal zone lymphoma; nodal marginal zone lymphoma; pathology; diagnosis; treatment; chemotherapy; rituximab

Patients with splenic MZL typically present with enlarged spleens and involvement of the abdominal lymph nodes and bone marrow that displays a rather specific sinusoidal growth pattern. A subset of patients shows liver infiltration and leukaemic conversion with or without the presence of villous lymphocytes [7].

## Abbreviations

BR:	bendamustine plus rituximab
CHOP:	cyclophosphamide, doxorubicin, vincristine and prednisone
CLL:	chronic lymphocytic leukaemia
CR:	complete response
CT:	computed tomography
DLBCL:	diffuse large B-cell lymphoma
ESMO:	European Society for Medical Oncology
<sup>18</sup> F-FDG:	fluorine-18-fluorodeoxyglucose
FISH:	fluorescence <i>in-situ</i> hybridisation
FL:	follicular lymphoma
GELA:	Groupe d'Etude des Lymphomes de l'Adulte
GI:	gastrointestinal
HBV:	hepatitis B virus
HCL:	hairy cell leukaemia
HCV:	hepatitis C virus
HIV:	human immunodeficiency virus
IFN- $\alpha$ :	interferon $\alpha$
IGHV:	immunoglobulin heavy chain variable region
LDH:	lactate dehydrogenase
LPL:	lymphoplasmacytic lymphoma
MALT:	mucosa-associated lymphoid tissue
MCL:	mantle cell lymphoma
MNDA:	myeloid cell nuclear differentiation antigen
MZL:	marginal zone lymphoma
NHL:	non-Hodgkin's lymphoma
ORR:	overall response rate
OS:	overall survival
PAS:	periodic acid-Schiff
PET:	positron emission tomography
PFS:	progression-free survival
PPI:	proton pump inhibitors
RT:	radiation therapy
SLL:	small lymphocytic lymphoma
WHO:	World Health Organization.

## Introduction

The term “marginal zone B-cell lymphoma” (MZL) refers to a group of indolent B-cell lymphomas that originate from the marginal zone of lymphoid follicles [1]. The World Health Organization (WHO) classifies MZL into three distinct entities: extranodal MZL (MALT lymphoma), nodal MZL and splenic MZL [2]. Mucosa-associated lymphoid tissue (MALT) lymphoma is the most commonly occurring subtype. It can arise at almost any extranodal site and is often associated with chronic antigenic stimulation, either as a result of chronic infection (such as gastric *Helicobacter pylori* infection) or autoimmune diseases [3–6]. MALT lymphomas may be subdivided into gastric and non-gastric tumours. In a recent survey of 18 US cancer registries, MALT lymphomas comprised 5%, nodal MZL 2.4% and splenic MZL 0.7% of all B-cell lymphomas [6]. Primary nodal MZL is rare and the least understood entity, and has to be clearly distinguished from secondary nodal involvement that arises as a consequence of disseminated extranodal or splenic MZL [7].



Although these MZL subtypes share some morphological and immunophenotypic features, their distinct biological characteristics have led to their separation into three individual entities in order to facilitate treatment. As a result of the rarity of the disease, there are only a few randomised trials testing the various treatment options and consequently very little guidance on how to manage MZL.

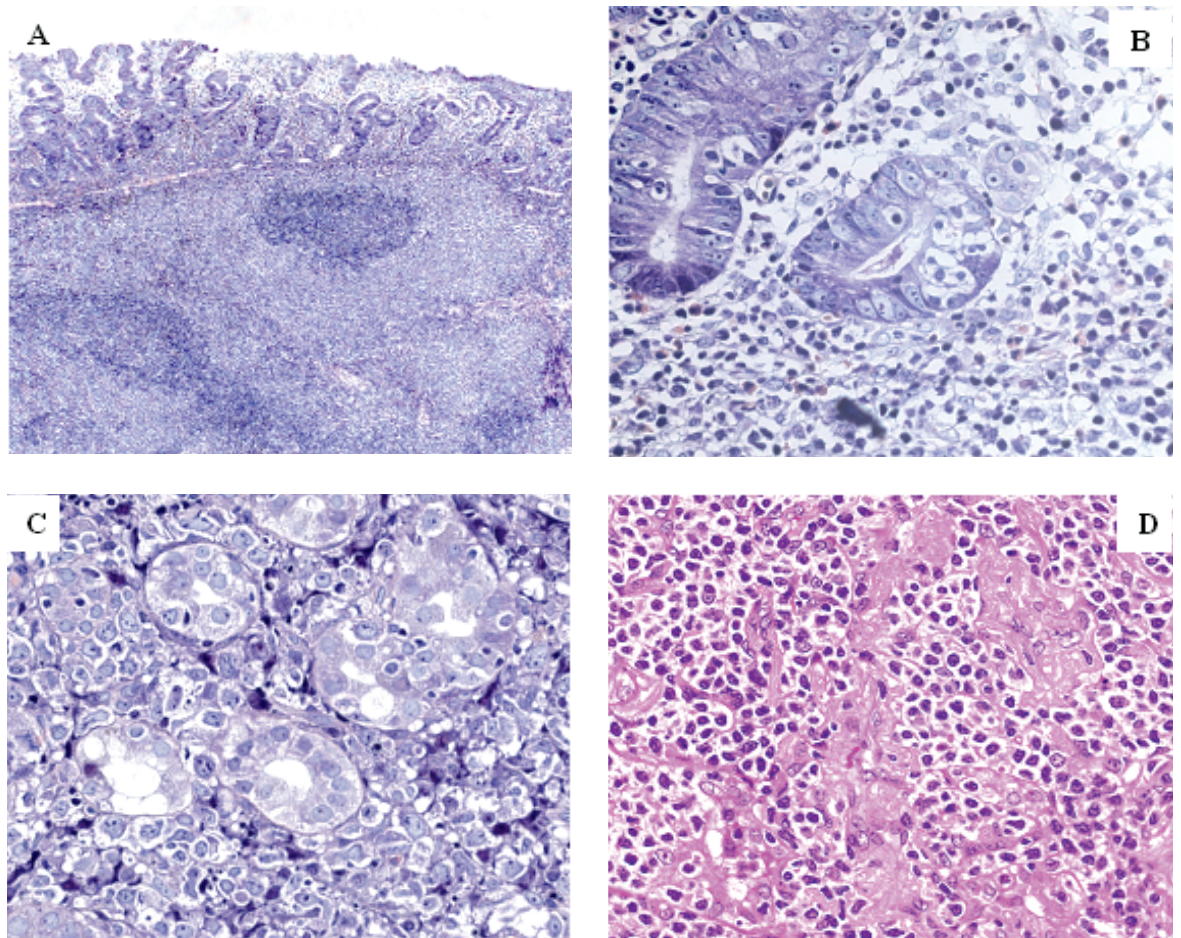
This review discusses the clinical features, diagnosis and management of each subtype alongside the open questions that should be considered by the physicians who treat this complex disease.

### MALT lymphoma (extranodal MZL)

#### Clinical features and diagnosis

MALT lymphomas often arise in areas that are genuinely devoid of lymphoid tissue, usually following a period of chronic inflammation that results in the accumulation of B cells [8]. The median age at presentation

is around 60 years, with a slightly higher proportion of females affected [9]. According to the 2008 WHO classification, MALT lymphoma is by definition an extranodal tumour composed of morphologically heterogeneous marginal zone B cells of varying centrocytoid, monocytoid or lymphocytoid appearance intermingled with scattered immunoblasts and centroblasts [2]. MALT lymphomas are generally indolent and have a good prognosis with 5-year overall survival (OS) rates over 85% [9]. The most common site of MALT lymphoma is the stomach (accounting for one third of cases), but the disease also occurs in the salivary glands, ocular adnexa, thyroid, lungs, breast and other tissues. The clinical features and symptoms of MALT lymphomas greatly depend on the organ of origin. Patients with gastric MALT lymphoma commonly suffer from nonspecific dyspepsia, nausea, epigastric pain and eventually from gastrointestinal bleeding. One area of uncertainty relates to the optimal staging system that should be used for MALT lymphomas, par-



**Figure 1:** Representative micrographs of (mucosa associated lymphoid tissue (MALT) lymphomas. A) Low grade gastric MALT lymphoma (overview of a surgical specimen), B) low grade gastric MALT lymphoma with lymphoepithelial lesions C) high-grade blastoid gastric MALT lymphoma, and D) low grade pulmonary MALT lymphoma.

ticularly for gastric tumours. The Ann Arbor staging system has been commonly applied, although it was originally designed for use with nodal lymphomas and therefore is not fully applicable to the specific characteristics of extranodal tumours in general or gastric MALT lymphomas in particular [9]. Thus, the modified Ann Arbor system is more appropriate [10]. Due to the possibility of disease dissemination to multiple extranodal sites [11, 12], it may be challenging to detect and identify additional occult lymphoma manifestations.

Raderer et al. performed an extensive staging evaluation in 140 patients, and their findings suggested that initially advanced and disseminated disease occurs more frequently in cases where the lymphoma is not primarily localised in the gastrointestinal tract [13]. Due to the possibility of disseminated disease, a thorough work-up is recommended for all MALT lymphomas regardless of the site of presentation [14]. A recent meta-analysis of studies published up to February 2014 on the detection rate of fluorine-18-fluorodeoxyglucose (<sup>18</sup>F-FDG) positron emission tomography (PET) and PET / computed tomography (CT) showed that MALT lymphoma is a <sup>18</sup>F-FDG-avid tumour in many cases, especially in those with extra-gastric presentation, with a pooled detection rate of 71% (95% confidence interval [CI] 61–80%) [15]. These findings suggest a potential role of <sup>18</sup>F-FDG PET/CT in the initial evaluation, particularly in patients for whom radiotherapy alone is planned to treat localised disease. Diffusion-weighted magnetic resonance imaging has been recently reported to be a very valuable tool, possibly superior to CT and <sup>18</sup>F-FDG PET/CT scans in pre-therapeutic assessment and staging of MALT lymphoma [16].

Today, diagnosis of gastric MALT lymphoma is based on the histopathological evaluation of gastric biopsies [17] (fig. 1). Immunohistochemically, MALT lymphomas are typically positive for CD20 and CD79a, and negative for CD5, CD10 and CD23. They may also express CD21 and CD35. However, no specific marker exists for conclusively identifying MALT lymphomas [18]. The European Society for Medical Oncology (ESMO) clinical practice guidelines recommend endoscopy of the oesophagus, stomach and duodenum accompanied by multiple biopsies taken from each of these regions, as well as from any site with an abnormal appearance. The guidelines also recommend endoscopic ultrasound for assessment of the lymph nodes and depth of gastric wall infiltration. Special care should be taken to rule out histologically the presence of confluent sheets of transformed large B cells highlighted by an elevated proliferation rate as measured by Ki67 (MIB-1) immunoreactivity, which represent diffuse large B-cell lymphoma (DLBCL) [17].

Table 1 summarises the recommended diagnostic work-up procedures for MALT lymphoma.

Upon diagnosis of gastric MALT lymphoma, it is important to assess the presence of *H. pylori*, as this will have an impact on the subsequent therapy. *H. pylori* is a Gram-negative bacterium considered to be one of the most infectious agents in the stomach and in parts of the gastrointestinal tract, producing inflammation. Although a wide battery of tests exists for the detection of *H. pylori* (including serology, urea breath tests, faecal antigen tests, histology and cultures from biopsy samples) [19], it is noteworthy that these are not standardised and no guidelines exist as to which test(s) should be performed. A negative *H. pylori* histological status should be verified using several strategies such as the urea breath test or the stool antigen and serological tests [20–22].

### Pathogenesis

There is a strong association between chronic infection/inflammation and the pathogenesis of MALT lymphoma [23, 24]. Of all these, the infectious aetiology of gastric MALT lymphoma has been the most extensively documented. *H. pylori* infection is a major causa-

**Table 1:** Summary of work-up procedures for mucosa-associated lymphoid tissue (MALT) lymphomas.

#### All MALT lymphomas [8, 14, 17]

Clinical history and physical examination (including lymph nodes, eye, ear, nose throat, liver and spleen)

#### Laboratory tests

Complete blood cell count

Evaluation of liver and kidney function

Serum LDH and  $\beta$ 2-microglobulin levels

Serological HIV, HCV and HBV testing

CT scan of the chest, abdomen and pelvis

Bone marrow biopsy

Biopsy of the affected tissue(s)

Morphological and immunophenotypic (modified Giemsa, pan-CK, CD20, CD3, MIB-1) investigations

#### Gastric MALT [17]

*Helicobacter pylori* serology and/or stool antigen test

Endoscopic ultrasound

Evaluation of *t(11;18)/BIRC3(API2)-MALT1* [genetic evaluation is not mandatory for the initial diagnosis]

#### Non-gastric MALT [8, 14]

Endoscopic examinations of the gastroduodenal tract to rule out concomitant gastric involvement

Endoscopic otorhinolaryngologic examinations

MRI of the orbit

CT scan of the parotid/salivary glands

CT = computed tomography; HBV = hepatitis B virus; HCV = hepatitis C virus; HIV = human immunodeficiency virus; LDH = lactate dehydrogenase; MRI = magnetic resonance imaging

tive factor in the development of gastric MALT lymphoma, where it has been hypothesised that the lymphoma arises from *H. pylori*-stimulated B cells. Recent evidence also points towards an infectious origin for orbital MALT lymphomas, with the potential culprit being the intracellular bacterium *Chlamydia psittaci* [25, 26]. Other infectious agents that have been implicated in the pathogenesis of MZL include *Borrelia burgdorferi* (MALT lymphomas in the skin), *Campylobacter jejuni* (MALT lymphomas in the small intestine) [27] and *Achromobacter xylosoxidans* in the lung [24]. Autoimmune diseases also increase the risk of devel-

oping non-gastric MALT lymphomas [23]. Both Hashimoto thyroiditis and immune sialadenitis as part of Sjögren syndrome are characterised by the infiltration of B cells in the thyroid and salivary glands, respectively, followed by progressive lymphoproliferation [23, 28]. However, it is important to note that not all patients infected with *H. pylori*, *C. psittaci* or those with autoimmune disorders develop lymphoma, indicating that other risk factors also play a role in the development of these tumours. There is some evidence indicating that recipients of solid transplants have an increased risk of certain lymphomas (including MZL of MALT-type), suggesting a possible role for immunosuppression in the aetiology of certain lymphoma subtypes [29, 30].

**Table 2:** Summary of immunophenotypic and cytogenetic findings in marginal zone B-cell lymphoma (MZL) including differential diagnoses [2, 8, 9, 14, 17, 50, 51, 85].

#### MALT lymphomas [18, 24, 87, 89, 97]

Positive for IgM, CD20, CD79a, CD21, CD35

Negative for CD5, CD10, CD23, and cyclin D1

*t(11;18)* translocation in gastric MALT lymphoma in 30–50% of cases

Trisomy of chromosomes 3 and 18

Inactivation of *TNFAIP3* (6q23)

*Differential diagnoses* [2]:

Absence of CD5 is against MCL and SLL/CLL

Absence of cyclin D1/SOX11 is against MCL

Absence of CD10 is against FL

#### Nodal MZL [8, 50, 51]

Positive for CD19, CD20, CD79a and PAX5

Usually negative for CD5, CD10, and CD23

Positive for MND1

Trisomy of chromosomes 3 and 18.

Somatic mutations of *PTPRD*, *NOTCH2*, *MLL2*

*Differential diagnoses*:

FL with marginal zone differentiation: Careful histological review to identify BCL2-negative centroblasts, and centrocytes positive for BCL6 and CD10. FL is often positive for GCET1, LMO2 and HGAL and shows *t(14;18)* translocations. Stathmin1 may be helpful for identifying FLs that are negative for BCL2 and/or CD10.

LPL: clinical features, LPL presents with Waldenström's macroglobulinaemia, nodal MZL presents with lymphadenopathy. Nodal MZL has monocytoid cellular morphology, marginal zone growth pattern, and follicular colonisation. MYD88 L265P mutations are more common in LPLs.

#### Splenic MZL [2, 44]

Positive for CD20, CD79a, co-expression of IgM/IgD

Usually negative for CD5, CD10, CD23, CD43, and CD103

Trisomy of chromosomes 3 and 18

Deletion of *7q31-q32*

Cytogenetic aberrations involving chromosome 8

Somatic mutations of *NOTCH2*, *KLF2*, *MLL2*, *TP53*

Frequent use of IGHV1-02

*Differential diagnoses* [2]:

Absence of cyclin D1/SOX11 is against MCL

Absence of CD5 is against SLL/CLL

Absence of CD103 and annexin A1 against HCL

Absence of CD10 and BCL6 is against FL

CLL = chronic lymphocytic leukaemia; FL = follicular lymphoma; LPL = lymphoplasmacytic lymphoma; MALT = mucosa-associated lymphoid tissue; MCL = mantle cell lymphoma; MND1 = myeloid cell nuclear differentiation antigen; SLL = small lymphocytic lymphoma

#### Cytogenetic, molecular and immunophenotypic findings

A common genetic aberration associated with gastric MALT lymphomas is *t(11,18)(q21;q21)*. This translocation results in a fusion between the *BIRC3* (*API2*) gene and the *MALT1* gene, producing a chimeric protein with the ability to enhance cell survival and proliferation by apoptosis inhibition and activation of the NF-κB pathway, respectively [24, 31]. The 30–50% of patients with gastric MALT lymphoma who have this translocation are more likely to exhibit widely disseminated disease and are more likely to be *H. pylori* negative [32]. The *t(14;18)(q32;q21)* translocation involving an abnormal recombination at the *IGH* locus on chromosome 14 and the *MALT1* locus on chromosome 18 is more frequently seen in non-gastric MALT lymphomas [24, 33]. Trisomy of chromosomes 3 and 18 and inactivation of *TNFAIP3* (6q23) occur frequently [18]. High levels of the FOXP1 protein (a result of chromosomal translocations or copy number changes) is also associated with poor prognosis in MALT lymphoma [34, 35]. The molecular and cytogenetic aberrations associated with the MZL entities are summarised in table 2.

#### Treatment

The optimal front-line treatment of patients with MALT lymphoma remains to be determined. The ESMO guidelines emphasise *H. pylori* eradication therapy for all gastric MALT lymphomas, regardless of stage [17]. The recommendation for first-line treatment is triple therapy, consisting of the use of a proton pump inhibitor (PPI) in combination with clarithromycin and amoxicillin (or metronidazole) [17]. The results from one study suggest that the presence of the *t(11;18)* translocation in patients with gastric MALT lymphoma may predict lack of response to *H. pylori* eradication therapy [32]. There is still a controversy regarding the use of



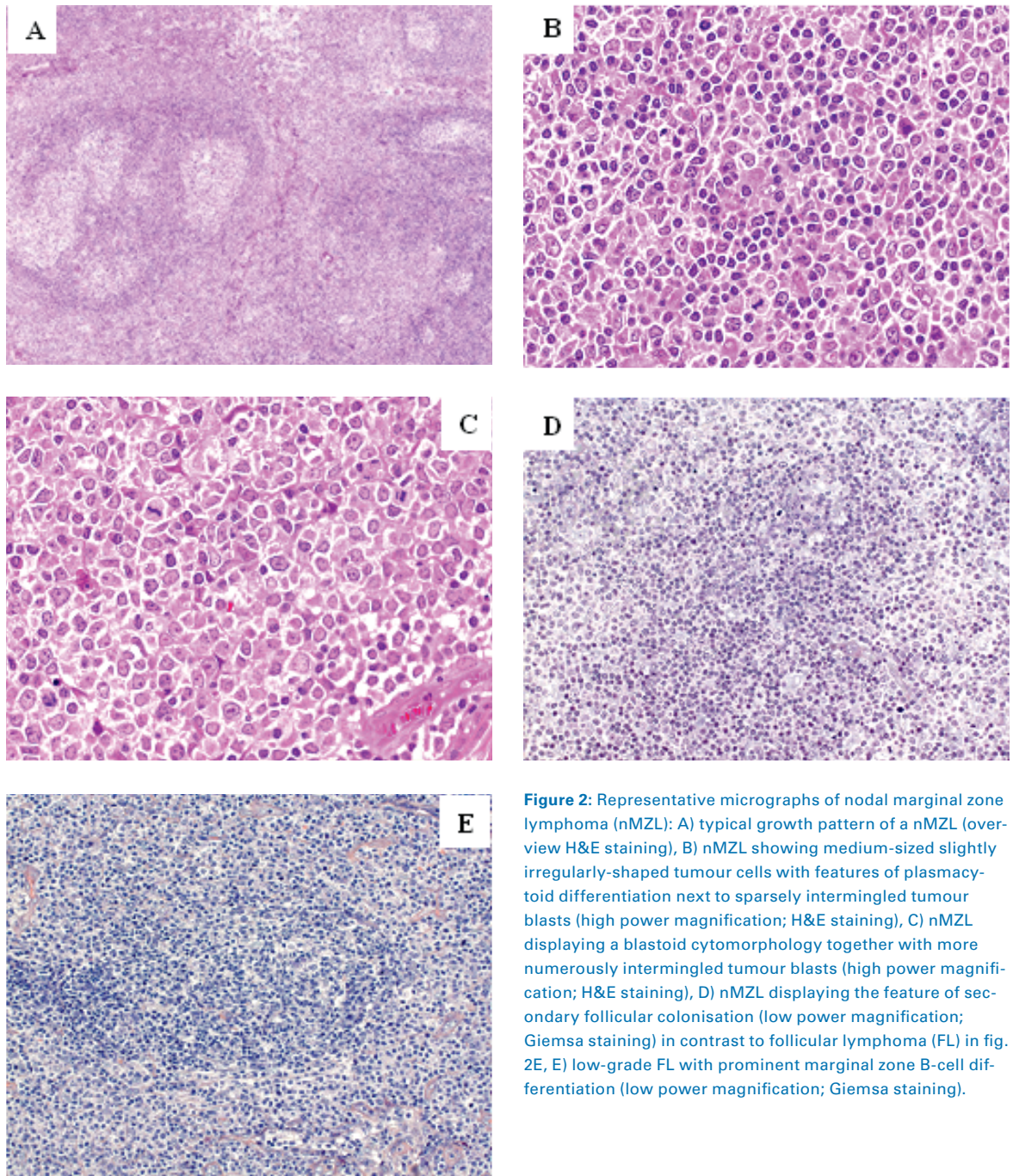
antibiotic therapy for non-gastric MALT lymphomas, excluding MALT lymphoma of the ocular adnexa, where eradication of *C. psittaci* with tetracycline has been associated with improved response rates and progression-free survival (PFS) [36, 37]. For gastric MALT lymphoma, antibiotic therapy is considered worthwhile even for *H. pylori*-negative cases, with respect to false negative testing or the presence of other *Helicobacter* species (such as *H. heilmannii* or *H. felis*) [17, 38]. There is no robust evidence-based guidance for the treatment of patients who require further therapy beyond *H. pylori* eradication or for those with non-gastric MALT lymphoma. For patients who do not respond to *H. pylori* eradication, those with early-stage gastric MALT lymphoma, or those with non-gastric MALT lymphoma, there is some data supporting the efficacy of localised radiation therapy. Disease control can be achieved by a medium dose of involved-field radiation therapy (24–30 Gy administered within a 3–4 week period is suggested by the ESMO guidelines) [17, 39, 40]. Data from several studies indicate that low-dose radiation therapy (between 2–4 Gy) is effective and well tolerated for the treatment of MALT lymphomas [41, 42], and could be particularly useful for minimising radiation-associated morbidity in certain tissues such as the ocular adnexa [41]. Immunochemotherapy and/or chemotherapy are also effective for all stages of MALT lymphomas [17]. The combination of rituximab plus various chemotherapy agents has been shown to yield good response rates [43–46]. So far, the only immunochemotherapy regimen that has been tested in a relatively large randomised study is rituximab plus chlorambucil. Results from the IELSG-19 study in patients with non-gastric MALT lymphomas and gastric MALT lymphomas refractory to prior antibiotic therapy suggested that the combination of chlorambucil plus rituximab yielded a better outcome compared with either single regimen, although it should be noted that the 5-year OS rate was similar in all three treatment arms [45]. Results from a recent phase II study by the Spanish GELTAMO group in 60 patients with MALT lymphoma (at any site, and at any stage) showed that the combination of bendamustine plus rituximab yielded good response rates [47]. At 2 years and 4 years, event-free survival rates were 93% and 88%, respectively. The ESMO guidelines suggest the use of rituximab plus chemotherapy for systemic treatment, but there is no further guidance to indicate which chemotherapy agent(s) should be used in combination with rituximab [17].

## Nodal MZL

### Clinical features and diagnosis

Nodal MZL is a rare entity, accounting for approximately 2% of lymphomas [6, 48, 49]. The median age at diagnosis is ~60 years; however, there is a wide age distribution. Most patients present with stage III or IV disease [50]. There is an equal prevalence in males and females. It is thought to be an indolent disease with a clinical course similar to that of follicular lymphoma (FL), but with a highly variable presentation [7]. By definition, the disease has a nodal origin showing morphological, immunophenotypic, and genetic characteristics that overlap with those of extranodal, rather than those of splenic MZL (fig. 2). Clinical features at presentation usually include peripheral lymphadenopathy often involving the head and neck region. Bone marrow involvement is seen in 30–60% of cases. Laboratory findings show elevated levels of  $\beta$ 2-microglobulin and lactate dehydrogenase in roughly one-third of patients, and the presence of an M component (~10% of patients), although the proportions vary depending on the series [50, 51]. Since nodal MZL was only recognised and accepted as a distinct entity by the WHO classification in 2008, data on the clinical features, pathology and outcome are limited and vary considerably.

In terms of morphology, nodal MZL displays a para-, peri-, or interfollicular growth pattern in strands and sheets, which in the beginning excludes reactive lymphoid follicles. These may, however, be colonised in later disease phases. Cytologically, nodal MZL shows small to medium sized lymphoid tumour cells of monocytoid, centrocytoid, or lymphocytoid appearance, intermingled with tumour blasts in varying numbers. MZL is characterised by plasmacytoid differentiation to varying degrees and may display intranuclear PAS-positive inclusions (Dutcher bodies). In general, nodal MZL cannot be strictly distinguished from secondary lymph node involvement by primary extranodal or splenic tumours and requires full knowledge of the clinical features of these malignancies [52] (fig. 2). Morphologically, there is a significant overlap between nodal MZL and lymphoplasmacytic lymphoma (LPL). However, the latter is more typically associated with IgM-paraproteinaemia that manifests as a result of Waldenström's macroglobulinaemia, as it is characterised by the MYD88 L265P somatic mutation [53]. MZL also displays a morphological resemblance to FL, inasmuch as on the one hand MZL typically colonises reactive germinal centres mimicking FL, whereas on the other hand FL may display the feature of a marginal zone differentiation [54] (fig. 2). In cases where the tumour cells have colonised the follicle, neoplastic cells



**Figure 2:** Representative micrographs of nodal marginal zone lymphoma (nMZL): A) typical growth pattern of a nMZL (overview H&E staining), B) nMZL showing medium-sized slightly irregularly-shaped tumour cells with features of plasmacytoid differentiation next to sparsely intermingled tumour blasts (high power magnification; H&E staining), C) nMZL displaying a blastoid cytomorphology together with more numerous intermingled tumour blasts (high power magnification; H&E staining), D) nMZL displaying the feature of secondary follicular colonisation (low power magnification; Giemsa staining) in contrast to follicular lymphoma (FL) in fig. 2E, E) low-grade FL with prominent marginal zone B-cell differentiation (low power magnification; Giemsa staining).

express BCL2 and MUM1 but are negative for BCL6 and CD10 [55]. Recently, myeloid cell nuclear differentiation antigen (MNDA) has been reported as a potential diagnostic marker that may distinguish positive nodal MZL from negative FL [56]. However in such cases FISH analysis is a more reliable tool and should be performed for the detection of *t(14;18)(q32;q21)* chromosomal translocation, a rather specific molecular marker for FL.

As for the other MZL entities, the optimal diagnostic and staging procedures remain to be defined. The staging procedures recommended by the ESMO guidelines

include full blood and differential counts, complete biochemical tests for liver and kidney function, LDH,  $\beta_2$ -microglobulin, and protein electrophoresis [57]. Bone marrow biopsies and chest/abdominal CT scanning are also part of the ESMO staging checklist. Although some reports are optimistic about the use of PET for studying the extent of the disease [58, 59], this matter is still under debate and the ESMO guidelines do not advocate the use of PET in routine staging and follow-up [57]. A summary of the work-up procedures for nodal MZL is shown in table 3.



**Table 3:** Summary of work-up procedures for nodal marginal zone B-cell lymphoma (MZL) [57].

<b>Nodal MZL</b>
History and physical examination
Bone marrow biopsy
Laboratory tests
Complete blood count
Evaluation of liver and kidney function markers
Protein electrophoresis
Calcium, LDH, albumin and $\beta$ 2-microglobulin levels
HCV, HBV and HIV testing
<i>Helicobacter pylori</i> testing in the case of gastric symptoms
CT scan of the chest, abdomen and pelvis
Gastroduodenal endoscopy plus ear, nose and throat evaluation to exclude extranodal disease

CT = computed tomography; HBV = hepatitis B virus; HCV = hepatitis C virus; HIV = human immunodeficiency virus; LDH = lactate dehydrogenase

### Pathogenesis

Several reports hint at an association with autoimmune disorders including rheumatoid arthritis, vitiligo, systemic lupus erythematosus, chronic thyroiditis and Sjögren's syndrome [51, 60]. Other studies have shown a high hepatitis C virus (HCV) seroprevalence amongst patients with nodal MZL [61–63]. As for the MALT lymphomas, chronic inflammation may play a role in the disease aetiology at least in some patients, but the pathogenic mechanisms of nodal MZL remain unknown.

### Cytogenetic, molecular and immunophenotypic findings

It is difficult to establish a characteristic immunophenotypic or cytogenetic profile for nodal MZL. It expresses the B-cell markers CD19, CD20, CD79a and PAX5, but is usually negative for CD5, CD10, and CD23 [50;51]. IgM/IgD co-expression (a characteristic of splenic MZL) is found in only a small percentage of nodal cases and its significance is still under debate. Plasmacytic differentiation can be highlighted by expression of plasmacytic markers, such as CD38, CD138 and MUM1 [64]. The molecular and cytogenetic aberrations in nodal MZL are summarised in table 2.

The majority of patients with nodal MZL exhibit somatic mutations in the IGHV genes, which are more commonly of the IGHV3 and 5 families [65]. There are often trisomies of chromosomes 3 and 18 [2, 18, 44]. The arrival at a diagnosis of nodal MZL is usually via exclusion of other less likely diseases with overlapping features (table 2).

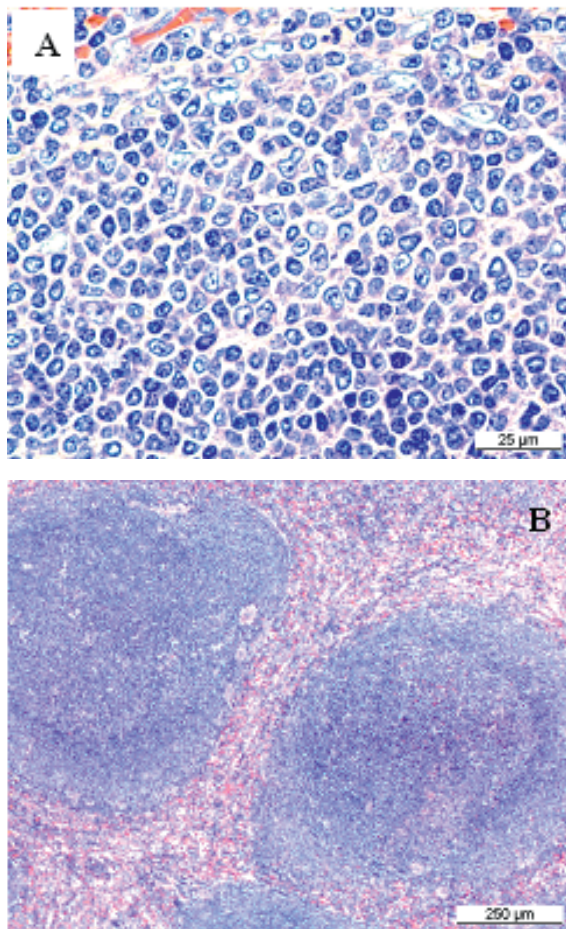
### Treatment

There are no guidelines for the preferred treatment of nodal MZL. The ESMO guidelines recommend that patients are managed with the same strategies as for FL [57]. In patients with limited disease, localised radiation therapy can achieve good tumour control. Current recommendations support the use of a 24 Gy dose applied only to the involved disease sites [66–68]. The use of low-dose (4 Gy) radiation therapy has shown good results in the palliative treatment setting [69, 70]. In advanced stages of the disease, immunochemotherapy is the main treatment option [57]. A recent study in patients with indolent and mantle cell lymphomas (MCL) (including a subset of patients with nodal MZL) tested rituximab plus cyclophosphamide, doxorubicin, vincristine and prednisone (R-CHOP) versus bendamustine plus rituximab (BR) [71]. The data showed that BR yielded similar outcomes to R-CHOP in terms of PFS, but BR was preferable because it was less toxic [71]. However, owing to the rarity of nodal MZL, there is no robust evidence base from which to select the optimal regimen.

### Splenic MZL

#### Clinical features and diagnosis

Splenic MZL accounts for <2% of all lymphomas, but is the most common lymphoma originating in the spleen [6, 72]. The median age at presentation is around 65 years with equal incidence in both genders. Splenic MZL is believed to be indolent. Median OS is >10 years but around one third of patients have more aggressive disease, resulting in a shorter OS (4 years). In ~5% of patients, the disease undergoes transformation into large B-cell lymphoma. The tumour consists mainly of small lymphoid cells. It originates in the marginal zone within the white pulp of the spleen and may secondarily involve splenic hilar lymph nodes and bone marrow, where it may show a typical and rather specific sinusoidal pattern (fig. 3). The liver is also a frequent site of secondary involvement [72]. Some patients may become leukaemic but no peripheral lymphadenopathy is found [2]. Most patients are asymptomatic and their disease discovered incidentally as anaemia and/or thrombocytopenia in a routine blood count [72]. On the other hand, splenomegaly can be detected upon clinical examination, sometimes accompanied by anaemia, autoimmune thrombocytopenia and variably by villous lymphocytes in peripheral blood [2, 44]. The main clinical symptoms in patients with advanced disease are due to splenomegaly (abdominal discomfort or pain, cytopenias). As for the other MZL entities, arrival at a correct diagnosis of splenic MZL requires the integration of clinical



**Figure 3:** Representative micrographs of splenic marginal zone lymphoma (MZL). A) Splenic MZL and B) splenic MZL with low-magnification view of the growth pattern.

cal, laboratory, imaging and pathological data (table 2 and table 4). However, a diagnosis of splenic MZL no longer strictly requires splenectomy [57] since characteristic features that allow a diagnosis based on bone marrow examination and peripheral blood flow cy-

tometry have recently been established [73, 74]. The tumour cells are positive for cell surface IgM, CD20 and CD79a. They are usually negative for CD5, CD10, CD23 and CD43. It is important to distinguish splenic MZL from hairy cell leukaemia (HCL); in this case, the absence of CD103 and (even more specifically) of annexin A1 weighs against a diagnosis of HCL [75] (table 2). Histology plays a pivotal role in the diagnostic procedure for splenic MZL (table 2 and table 4). Screening for HCV is important to identify those patients who may benefit from antiviral therapy [72]. As for non-splenic MZL, the patient's hepatitis B virus (HBV) and human immunodeficiency virus (HIV) status should also be tested. Complete medical history, physical examination, full blood counts, renal and liver biochemical tests, and serum levels of lactate dehydrogenase (LDH) and  $\beta$ 2-microglobulin should be performed [73]. Autoimmune diseases are found in 10–15% of patients, and thus should be taken into special consideration [76]. Anaemia, thrombocytopenia, the presence of extrahilar lymphadenopathy, elevated LDH and reduced albumin levels are the main clinical prognostic factors that can be used for risk stratification [76–78]. Tumour infiltration of non-haematopoietic tissues is also an unfavourable prognostic factor [41].

### Pathogenesis

The aetiology is unknown but chronic antigen stimulation is possibly a trigger for disease onset [79, 80]. In circumscribed populations such as those in southern Italy and parts of the US, splenic MZL occurs more frequently in HCV carriers and eradication of the virus results in lymphoma remission [81–84], comparable to the effect of *H. pylori* eradication in gastric MALT lymphoma.

### Cytogenetic, molecular and immunophenotypic findings

Pathophysiologically, splenic MZL has yet no known specific genetic marker [85]. The most frequently encountered cytogenetic abnormalities are trisomy of chromosomes 3 and 18, and deletion at 7q31.31–q32.3, with the latter considered typical of splenic MZL [18, 86]. Somatic mutations of *KLF2* and of genes involved in the Notch and NF- $\kappa$ B pathways are frequent events [87–89]. Other aberrations have also been reported (table 2), but these are not present in all patients.

About half of patients have somatic mutations in the IGHV genes, and there is a biased usage of IGHV1-2 and IGHV3-23 [79, 86]. A large case series recently indicated that one third of splenic MZL patients carry the IGHV1-02 gene, with a strong bias (90% of cases) towards involvement of the allele O4 polymorphic variant [79],

**Table 4:** Summary of work-up procedures for splenic marginal zone B-cell lymphoma (MZL) [72].

#### Splenic MZL

History and physical examination (particularly spleen)

Spleen histology

Bone marrow biopsy

Laboratory tests

Complete blood cell count

Evaluation of liver and kidney markers

Serum LDH, albumin and  $\beta$ 2-microglobulin levels

HCV, HBV and HIV testing

Screening for autoimmunity

CT scan of the chest, abdomen and pelvis

CT = computed tomography; HBV = hepatitis B virus; HCV = hepatitis C virus; HIV = human immunodeficiency virus; LDH = lactate dehydrogenase



suggesting a selection by antigenic stimulation and/or an origin from progenitor cells that are adapted to particular antigenic challenges through selection of specific VH domains [79].

### Treatment

There are no treatment recommendations for splenic MZL. Because the disease is believed to be indolent, a watch and wait strategy appears to be feasible in many cases. There is no evidence that early intervention would favour patients with only mild splenomegaly and no systemic symptoms [72], except for HCV-positive patients, who may benefit even more from an early onset of antiviral therapy [90]. However, one open question is whether patients with a poor prognostic profile should not receive earlier treatment. The ESMO guidelines list the criteria indicative for starting treatment, namely: progressive splenomegaly, progressive cytopenias, decrease of haemoglobin <10 g/dl, platelet count <80 000/ $\mu$ l, and neutrophil count <1000/ $\mu$ l [57]. There are several possible treatment strategies. Splenectomy has been a traditional first-line option which can alleviate splenomegaly-related symptoms and improve cytopenias in the majority of patients, resulting in a median PFS of 5 years [91]. However, removal of the spleen will not influence bone marrow or peripheral blood involvement [92]. Chemotherapy or immunochemotherapy regimens may be proposed for patients who are unable or unwilling to undergo splenectomy. Chemotherapy regimens are

based on alkylating agents such as chlorambucil or cyclophosphamide [44]. Single-agent fludarabine has also been used with some success, although the data come from case series with small patient numbers [93, 94]. Rituximab, alone or in combination with chemotherapy, also achieves high overall and complete response rates. The ESMO guidelines suggest the use of four weekly doses of rituximab at 375 mg/m<sup>2</sup> as a first-line alternative to splenectomy, although the optimal treatment regimen and long-term outcome still needs to be established [57].

### Follow-up for all MZL entities

Follow-up of non-gastric MALT disease should proceed in the same manner as for other indolent lymphomas (table 5). For *H. pylori*-positive gastric MALT lymphoma patients, eradication of *H. pylori* cannot be conclusively confirmed earlier than 6 weeks after antibiotic treatment [17]. Endoscopic examinations and a harvest of multiple biopsies 3–6 months after completion of antibacterial treatment should follow to exclude potential residuals [95]. Histological evaluation of repeated biopsies remains an essential part of the follow-up procedure. It should be noted that the interpretation of post-treatment lymphoid infiltrates in gastric biopsies is a challenge [17]. ESMO guidelines recommend that new biopsies should be compared to previous biopsies using the Groupe d'Etude des Lymphomes de l'Adulte (GELA) scoring system [96]. The same procedure of endoscopy plus biopsies should be performed at least twice a year for another 2 years after treatment to monitor stable lymphoma regression. Although it is possible to encounter transient local relapses upon histological examination, these are usually self-limiting, particularly when there is no *H. pylori* re-infection [57]. Another open question is for how long these patients should be followed up. For the time being, the ESMO guidelines state that in the long run, all gastric MALT lymphoma patients should be re-evaluated clinically and endoscopically every 12–18 months. It should be noted that patients with gastric MALT lymphoma have a reported six-fold higher risk of gastric adenocarcinoma compared with the general population [57]. For patients with splenic or nodal MZL who are asymptomatic, monitoring should be performed every 6 months (table 5). The follow-up procedures should be done more frequently (every 4–6 weeks in the first 3 months) in patients who have undergone treatment. Clinicians and pathologists performing the follow-up on all MZL entities should keep a watchful eye for potential high grade tumour transformation.

**Table 5:** Summary of follow-up and monitoring procedures for the marginal zone B-cell lymphoma (MZL) entities [57].

#### MALT (non-gastric and gastric)

Complete clinical examination (at completion of treatment)

Laboratory work-up (at completion of treatment)

Radiological or ultrasound examinations (at completion of treatment)

Biopsy of any remaining lesions (at completion of treatment)

Clinical and endoscopic follow-up every 12–18 months

#### Gastric MALT

After antibiotic treatment, test for eradication of *Helicobacter pylori* (stool antigen test, breath test)

Endoscopic follow-up with biopsies (2–3 months after treatment, then twice a year for the next 2 years)

#### Splenic and nodal MZL

Complete clinical examination

Blood counts

Laboratory work-up

– For asymptomatic patients, every 6 months

– For treated patients, at the end of treatment, 4–6 weeks during the first 3 months, then every 6 months

MALT = mucosa-associated lymphoid tissue

## Conclusions

MZL lymphomas are rare and in the majority of cases they have an indolent clinical course. The extranodal, nodal, and splenic subtypes share some overlapping features but nevertheless represent individual entities. Because of their rarity, there are not many randomised trials evaluating therapeutic options, nor guidelines or protocols for the treatment and follow-up of these patients. Treatment decisions should be a result of collaboration between the clinician, the pathologist and the patient.

## Acknowledgements

The authors thank Karen Yeow (Biomedcomm Ltd.) for editorial assistance during the preparation of this manuscript.

## Disclosure statement

This work was supported by Roche Pharma (Schweiz) AG, Reinach, Switzerland.

## References

- 1 A clinical evaluation of the International Lymphoma Study Group classification of non-Hodgkin's lymphoma. The Non-Hodgkin's Lymphoma Classification Project. *Blood*. 1997;89(11):3909–18.
- 2 Swerdlow SH, Campo E, Harris NL, et al. WHO Classification of Tumours of Haematopoietic and Lymphoid Tissue (IARC WHO Classification of Tumours). World Health Organization 2008; 4th edition.
- 3 Bracci PM, Benavente Y, Turner JJ, et al. Medical History, Lifestyle, Family History, and Occupational Risk Factors for Marginal Zone Lymphoma: The InterLymph Non-Hodgkin Lymphoma Subtypes Project. *J Natl Cancer Inst Monogr*. 2014;2014(48):52–65.
- 4 Isaacson PG, Du MQ. MALT lymphoma: from morphology to molecules. *Nat Rev Cancer*. 2004;4(8):644–53.
- 5 Nishishinya MB, Pereda CA, Munoz-Fernandez S, et al. Identification of lymphoma predictors in patients with primary Sjogren's syndrome: a systematic literature review and meta-analysis. *Rheumatol Int*. 2015;35(1):17–26.
- 6 Olszewski AJ, Castillo JJ. Survival of patients with marginal zone lymphoma: analysis of the Surveillance, Epidemiology, and End Results database. *Cancer*. 2013;119(3):629–38.
- 7 Reid R, Friedberg JW. Management of marginal zone lymphoma. *Oncology (Williston Park)* 2013;27(9):840, 842, 844.
- 8 Kahl B, Yang D. Marginal zone lymphomas: management of nodal, splenic, and MALT NHL. *Hematology Am Soc Hematol Educ Program*. 2008;359–64.
- 9 Bertoni F, Coiffier B, Salles G, et al. MALT lymphomas: pathogenesis can drive treatment. *Oncology (Williston Park)* 2011;25(12):1134–42, 1147.
- 10 Radaszkiewicz T, Dragosics B, Bauer P. Gastrointestinal malignant lymphomas of the mucosa-associated lymphoid tissue: factors relevant to prognosis. *Gastroenterology*. 1992;102(5):1628–38.
- 11 Thieblemont C, Berger F, Dumontet C, et al. Mucosa-associated lymphoid tissue lymphoma is a disseminated disease in one third of 158 patients analyzed. *Blood*. 2000;95(3):802–6.
- 12 Zucca E, Conconi A, Pedrinis E, et al. Nongastric marginal zone B-cell lymphoma of mucosa-associated lymphoid tissue. *Blood*. 2003;101(7):2489–95.
- 13 Raderer M, Wöhrer S, Streubel B, et al. Assessment of disease dissemination in gastric compared with extragastric mucosa-associated lymphoid tissue lymphoma using extensive staging: a single-center experience. *J Clin Oncol*. 2006;24(19):3136–41.
- 14 Zucca E, Stathis A, Bertoni F. The management of nongastric MALT lymphomas. *Oncology (Williston Park)* 2014;28(1):86–93.
- 15 Treglia G, Zucca E, Sadeghi R, et al. Detection rate of fluorine-18-fluorodeoxyglucose positron emission tomography in patients with marginal zone lymphoma of MALT type: a meta-analysis. *Hematol Oncol*. 2014;Jul. 22-doi: 10.1002/hon.2152
- 16 Mayerhoefer ME, Karanikas G, Kletter K, et al. Evaluation of diffusion-weighted MRI for pretherapeutic assessment and staging of lymphoma: results of a prospective study in 140 patients. *Clin Cancer Res*. 2014;20(11):2984–93.
- 17 Zucca E, Copie-Bergman C, Ricardi U, et al. Gastric marginal zone lymphoma of MALT type: ESMO Clinical Practice Guidelines for diagnosis, treatment and follow-up. *Ann Oncol*. 2013;24(Suppl 6):vi144–vi148.
- 18 Rinaldi A, Mian M, Chigrinova E, et al. Genome-wide DNA profiling of marginal zone lymphomas identifies subtype-specific lesions with an impact on the clinical outcome. *Blood*. 2011;117(5):1595–604.
- 19 Di Rienzo TA, D'Angelo G, Ojetti V, et al. 13C-Urea breath test for the diagnosis of *Helicobacter pylori* infection. *Eur Rev Med Pharmacol Sci*. 2013;17(Suppl 2):51–8.
- 20 Olafsson S, Patel B, Jackson C, Cai J. *Helicobacter pylori* breath testing in an open access system has a high rate of potentially false negative results due to protocol violations. *Helicobacter*. 2012;17(5):391–5.
- 21 Funakoshi R, Yokoyama H, Kawai N, et al. Effect of pharmaceutical care in the diagnosis of *Helicobacter pylori* infection using 13C-urea breath test. *Yakugaku Zasshi*. 2012;132(5):601–7.
- 22 Genta RM, Lash RH. *Helicobacter pylori*-negative gastritis: seek, yet ye shall not always find. *Am J Surg Pathol*. 2010;34(8):e25–e34.
- 23 Thieblemont C, Bertoni F, Copie-Bergman C, et al. Chronic inflammation and extra-nodal marginal-zone lymphomas of MALT-type. *Semin Cancer Biol*. 2014;2433–42.
- 24 Zucca E, Bertoni F, Vannata B, Cavalli F. Emerging role of infectious etiologies in the pathogenesis of marginal zone B-cell lymphomas. *Clin Cancer Res*. 2014;20(20):5207–16.
- 25 Ferreri AJ, Dolcetti R, Magnino S, et al. Chlamydial infection: the link with ocular adnexal lymphomas. *Nat Rev Clin Oncol*. 2009;6(11):658–69.
- 26 Stefanovic A, Lossos IS. Extranodal marginal zone lymphoma of the ocular adnexa. *Blood*. 2009;114(3):501–10.
- 27 Vannata B, Stathis A, Zucca E. Management of the marginal zone lymphomas. *Cancer Treat Res*. 2015;165227–249.
- 28 Nocturne G, Mariette X. Sjogren Syndrome-associated lymphomas: an update on pathogenesis and management. *Br J Haematol*. 2015;168(3):317–27.
- 29 Clarke CA, Morton LM, Lynch C, et al. Risk of lymphoma subtypes after solid organ transplantation in the United States. *Br J Cancer*. 2013;109(1):280–8.
- 30 Gibson SE, Swerdlow SH, Craig FE, et al. EBV-positive extranodal marginal zone lymphoma of mucosa-associated lymphoid tissue in the posttransplant setting: a distinct type of posttransplant lymphoproliferative disorder? *Am J Surg Pathol*. 2011;35(6):807–15.
- 31 Dierlamm J, Baens M, Wlodarska I, et al. The apoptosis inhibitor gene API2 and a novel 18q gene, MLT, are recurrently rearranged in the t(11;18)(q21;q21) associated with mucosa-associated lymphoid tissue lymphomas. *Blood*. 1999;93(11):3601–9.
- 32 Liu H, Ye H, Ruskone-Fourmestraux A, et al. T(11;18) is a marker for all stage gastric MALT lymphomas that will not respond to *H. pylori* eradication. *Gastroenterology*. 2002;122(5):1286–94.
- 33 Murga Penas EM, Callet-Bauchu E, Ye H, et al. The t(14;18)(q32;q21)/IGH-MALT1 translocation in MALT lymphomas contains templated nucleotide insertions and a major breakpoint region similar to follicular and mantle cell lymphoma. *Blood*. 2010;115(11):2214–9.
- 34 Goatly A, Bacon CM, Nakamura S, et al. FOXP1 abnormalities in lymphoma: translocation breakpoint mapping reveals insights into deregulated transcriptional control. *Mod Pathol*. 2008;21(7):902–11.
- 35 Nakamura S, Ye H, Bacon CM, et al. Clinical impact of genetic aberrations in gastric MALT lymphoma: a comprehensive analysis using interphase fluorescence in situ hybridisation. *Gut*. 2007;56(10):1358–63.
- 36 Ferreri AJ, Govi S, Pasini E, et al. Chlamydia *psittaci* eradication with doxycycline as first-line targeted therapy for ocular adnexal lymphoma: final results of an international phase II trial. *J Clin Oncol*. 2012;30(24):2988–94.
- 37 Kiesewetter B, Raderer M. Antibiotic therapy in nongastrointestinal MALT lymphoma: a review of the literature. *Blood*. 2013;122(8):1350–7.
- 38 Park JB, Koo JS. *Helicobacter pylori* infection in gastric mucosa-associated lymphoid tissue lymphoma. *World J Gastroenterol*. 2014;20(11):2751–9.

## Correspondence:

Professor Dr. med.  
Christoph Renner,  
Onkozentrum Hirslanden,  
Witellikerstrasse 40,  
CH-8038 Zürich  
Christoph.Renner[at]  
hirslanden.ch



- 39 Koch P, Probst A, Berdel WE, et al. Treatment results in localized primary gastric lymphoma: data of patients registered within the German multicenter study (GIT NHL 02/96). *J Clin Oncol*. 2005;23(28):7050–9.
- 40 Nam TK, Ahn JS, Choi YD, et al. The role of radiotherapy in the treatment of gastric mucosa-associated lymphoid tissue lymphoma. *Cancer Res Treat*. 2014;46(1):33–40.
- 41 Fasola CE, Jones JC, Huang DD, et al. Low-dose radiation therapy (2 Gy x 2) in the treatment of orbital lymphoma. *Int J Radiat Oncol Biol Phys*. 2013;86(5):930–5.
- 42 Haas RL, Poortmans P, de JD, et al. High response rates and lasting remissions after low-dose involved field radiotherapy in indolent lymphomas. *J Clin Oncol*. 2003;21(13):2474–80.
- 43 Martinelli G, Laszlo D, Ferreri AJ, et al. Clinical activity of rituximab in gastric marginal zone non-Hodgkin's lymphoma resistant to or not eligible for anti-*Helicobacter pylori* therapy. *J Clin Oncol*. 2005;23(9):1979–83.
- 44 Zinzani PL. The many faces of marginal zone lymphoma. *Hematology Am Soc Hematol Educ Program*. 2012;2012426–432.
- 45 Zucca E, Conconi A, Laszlo D, et al. Addition of rituximab to chlorambucil produces superior event-free survival in the treatment of patients with extranodal marginal-zone B-cell lymphoma: 5-year analysis of the IELSG-19 Randomized Study. *J Clin Oncol*. 2013;31(5):565–72.
- 46 Gill H, Chim CS, Au WY, et al. Non-gastric marginal zone B cell lymphoma: clinicopathologic features and treatment results. *Ann Hematol*. 2011;90(12):1399–407.
- 47 Salar A, Domingo-Domenech E, Panizo C, et al. First-line response-adapted treatment with the combination of bendamustine and rituximab in patients with mucosa-associated lymphoid tissue lymphoma (MALT2008-01): a multicentre, single-arm, phase 2 trial. *Lancet Haematology*. 2015;1(2):e104–e111.
- 48 Berger F, Felman P, Thieblemont C, et al. Non-MALT marginal zone B-cell lymphomas: a description of clinical presentation and outcome in 124 patients. *Blood*. 2000;95(6):1950–6.
- 49 Nathwani BN, Anderson JR, Armitage JO, et al. Marginal zone B-cell lymphoma: A clinical comparison of nodal and mucosa-associated lymphoid tissue types. Non-Hodgkin's Lymphoma Classification Project. *J Clin Oncol*. 1999;17(8):2486–92.
- 50 Traverse-Glehen A, Bertoni F, Thieblemont C, et al. Nodal marginal zone B-cell lymphoma: a diagnostic and therapeutic dilemma. *Oncology (Williston Park)* 2012;26(1):92–4.
- 51 van den Brand M, van Krieken JH. Recognizing nodal marginal zone lymphoma: recent advances and pitfalls. A systematic review. *Haematologica*. 2013;98(7):1003–13.
- 52 Cogliatti SB, Lennert K, Hansmann ML, Zwingers TL. Monocytoid B cell lymphoma: clinical and prognostic features of 21 patients. *J Clin Pathol*. 1990;43(8):619–25.
- 53 Treon SP, Xu L, Yang G, et al. MYD88 L265P somatic mutation in Waldenström's macroglobulinemia. *N Engl J Med*. 2012;367(9):826–33.
- 54 Schmid U, Cogliatti SB, Diss TC, Isaacson PG. Monocytoid/marginal zone B-cell differentiation in follicle centre cell lymphoma. *Histopathology*. 1996;29(3):201–8.
- 55 Naresh KN. Nodal marginal zone B-cell lymphoma with prominent follicular colonization – difficulties in diagnosis: a study of 15 cases. *Histopathology*. 2008;52(3):331–9.
- 56 Metcalf RA, Monabati A, Vyas M, et al. Myeloid cell nuclear differentiation antigen is expressed in a subset of marginal zone lymphomas and is useful in the differential diagnosis with follicular lymphoma. *Hum Pathol*. 2014;45(8):1730–6.
- 57 Dreyling M, Thieblemont C, Gallamini A et al. ESMO Consensus conferences: guidelines on malignant lymphoma. part 2: marginal zone lymphoma, mantle cell lymphoma, peripheral T-cell lymphoma. *Ann Oncol*. 2013;24(4):857–77.
- 58 Hoffmann M, Kletter K, Becherer A, et al. 18F-fluorodeoxyglucose positron emission tomography (18F-FDG-PET) for staging and follow-up of marginal zone B-cell lymphoma. *Oncology*. 2003;64(4):336–40.
- 59 Weiler-Sagie M, Bushelev O, Epelbaum R, et al. (18)F-FDG avidity in lymphoma readdressed: a study of 766 patients. *J Nucl Med*. 2010;51(1):25–30.
- 60 Mazloom A, Medeiros LJ, McLaughlin PW, et al. Marginal zone lymphomas: factors that affect the final outcome. *Cancer*. 2010;116(18):4291–8.
- 61 Arcaini L, Paulli M, Boveri E, et al. Splenic and nodal marginal zone lymphomas are indolent disorders at high hepatitis C virus seroprevalence with distinct presenting features but similar morphologic and phenotypic profiles. *Cancer*. 2004;100(1):107–15.
- 62 Arcaini L, Paulli M, Burcheri S, et al. Primary nodal marginal zone B-cell lymphoma: clinical features and prognostic assessment of a rare disease. *Br J Haematol*. 2007;136(2):301–4.
- 63 Chuang SS, Liao YL, Chang ST, et al. Hepatitis C virus infection is significantly associated with malignant lymphoma in Taiwan, particularly with nodal and splenic marginal zone lymphomas. *J Clin Pathol*. 2010;63(7):595–8.
- 64 Camacho FI, Algara P, Mollejo M, et al. Nodal marginal zone lymphoma: a heterogeneous tumor: a comprehensive analysis of a series of 27 cases. *Am J Surg Pathol*. 2003;27(6):762–71.
- 65 Traverse-Glehen A, Davi F, Ben SE, et al. Analysis of VH genes in marginal zone lymphoma reveals marked heterogeneity between splenic and nodal tumors and suggests the existence of clonal selection. *Haematologica*. 2005;90(4):470–8.
- 66 Hoskin PJ, Diez P, Williams M, et al. Recommendations for the use of radiotherapy in nodal lymphoma. *Clin Oncol (R Coll Radiol)* 2013;25(1):49–58.
- 67 Illidge T, Specht L, Yahalom J, et al. Modern radiation therapy for nodal non-Hodgkin lymphoma-target definition and dose guidelines from the International Lymphoma Radiation Oncology Group. *Int J Radiat Oncol Biol Phys*. 2014;89(1):49–58.
- 68 Lowry L, Smith P, Qian W et al. Reduced dose radiotherapy for local control in non-Hodgkin lymphoma: a randomised phase III trial. *Radiother Oncol*. 2011;100(1):86–92.
- 69 Haas RL, Poortmans P, de JD, et al. Effective palliation by low dose local radiotherapy for recurrent and/or chemotherapy refractory non-follicular lymphoma patients. *Eur J Cancer*. 2005;41(12):1724–30.
- 70 Hoskin PJ, Kirkwood AA, Popova B, et al. 4 Gy versus 24 Gy radiotherapy for patients with indolent lymphoma (FORT): a randomised phase 3 non-inferiority trial. *Lancet Oncol*. 2014;15(4):457–63.
- 71 Rummel MJ, Niederle N, Maschmeyer G, et al. Bendamustine plus rituximab versus CHOP plus rituximab as first-line treatment for patients with indolent and mantle-cell lymphomas: an open-label, multicentre, randomised, phase 3 non-inferiority trial. *Lancet*. 2013;381(9873):1203–10.
- 72 Matutes E. Splenic marginal zone lymphoma: disease features and management. *Expert Rev Hematol*. 2013;6(6):735–45.
- 73 Iannitto E, Tripodo C. How I diagnose and treat splenic lymphomas. *Blood*. 2011;117(9):2585–95.
- 74 Matutes E, Oscier D, Montalban C, et al. Splenic marginal zone lymphoma proposals for a revision of diagnostic, staging and therapeutic criteria. *Leukemia*. 2008;22(3):487–95.
- 75 Sherman MJ, Hanson CA, Hoyer JD. An assessment of the usefulness of immunohistochemical stains in the diagnosis of hairy cell leukemia. *Am J Clin Pathol*. 2011;136(3):390–9.
- 76 Thieblemont C, Davi F, Noguera ME, et al. Splenic marginal zone lymphoma: current knowledge and future directions. *Oncology (Williston Park)* 2012;26(2):194–202.
- 77 Arcaini L, Lazzarino M, Colombo N, et al. Splenic marginal zone lymphoma: a prognostic model for clinical use. *Blood*. 2006;107(12):4643–9.
- 78 Montalban C, Abraira V, Arcaini L, et al. Risk stratification for Splenic Marginal Zone Lymphoma based on haemoglobin concentration, platelet count, high lactate dehydrogenase level and extrahilar lymphadenopathy: development and validation on 593 cases. *Br J Haematol*. 2012;159(2):164–71.
- 79 Bikos V, Darzentas N, Hadzidimitriou A, et al. Over 30% of patients with splenic marginal zone lymphoma express the same immunoglobulin heavy variable gene: ontogenetic implications. *Leukemia*. 2012;26(7):1638–46.
- 80 Ferreri AJ, Govi S, Ponzoni M. Marginal zone lymphomas and infectious agents. *Semin Cancer Biol*. 2013;23(6):431–40.
- 81 Hermine O, Lefrere F, Bronowicki JP, et al. Regression of splenic lymphoma with villous lymphocytes after treatment of hepatitis C virus infection. *N Engl J Med*. 2002;347(2):89–94.
- 82 Kelaidi C, Rollot F, Park S, et al. Response to antiviral treatment in hepatitis C virus-associated marginal zone lymphomas. *Leukemia*. 2004;18(10):1711–6.

- 83 Mele A, Pulsoni A, Bianco E, et al. Hepatitis C virus and B-cell non-Hodgkin lymphomas: an Italian multicenter case-control study. *Blood*. 2003;102(3):996–9.
- 84 Arcaini L, Paulli M, Boveri E, et al. Splenic and nodal marginal zone lymphomas are indolent disorders at high hepatitis C virus seroprevalence with distinct presenting features but similar morphologic and phenotypic profiles. *Cancer*. 2004;100(1):107–15.
- 85 Baliakas P, Strefford JC, Bikos V, et al. Splenic marginal-zone lymphoma: ontogeny and genetics. *Leuk Lymphoma*. 2014;191–10.
- 86 Salido M, Baro C, Oscier D, et al. Cytogenetic aberrations and their prognostic value in a series of 330 splenic marginal zone B-cell lymphomas: a multicenter study of the Splenic B-Cell Lymphoma Group. *Blood*. 2010;116(9):1479–88.
- 87 Kiel MJ, Velusamy T, Betz BL, et al. Whole-genome sequencing identifies recurrent somatic NOTCH2 mutations in splenic marginal zone lymphoma. *J Exp Med*. 2012;209(9):1553–65.
- 88 Piva R, Deaglio S, Fama R, et al. The Kruppel-like factor 2 transcription factor gene is recurrently mutated in splenic marginal zone lymphoma. *Leukemia*. 2015;29(2):503–7.
- 89 Rossi D, Trifonov V, Fangazio M, et al. The coding genome of splenic marginal zone lymphoma: activation of NOTCH2 and other pathways regulating marginal zone development. *J Exp Med*. 2012;209(9):1537–51.
- 90 Vannata B, Zucca E. Hepatitis C virus-associated B-cell non-Hodgkin lymphomas. *Hematology Am Soc Hematol Educ Program*. 2014;2014(1):590–8.
- 91 Kalpadakis C, Pangalis GA, Vassilakopoulos TP, et al. Treatment of splenic marginal zone lymphoma: should splenectomy be abandoned? *Leuk Lymphoma*. 2014;55(7):1463–70.
- 92 Thieblemont C, Felman P, Berger F, et al. Treatment of splenic marginal zone B-cell lymphoma: an analysis of 81 patients. *Clin Lymphoma*. 2002;3(1):41–7.
- 93 Lefrere F, Levy V, Francois S, et al. Fludarabine therapy in patients with splenic lymphoma with villous lymphocytes: an update. *Leukemia*. 2004;18(11):1924–5.
- 94 Yasukawa M, Yamauchi H, Azuma T, et al. Dramatic efficacy of fludarabine in the treatment of an aggressive case of splenic lymphoma with villous lymphocytes. *Eur J Haematol*. 2002;69(2):112–4.
- 95 Bertoni F, Zucca E. State-of-the-art therapeutics: marginal-zone lymphoma. *J Clin Oncol*. 2005;23(26):6415–20.
- 96 Copie-Bergman C, Wotherspoon AC, Capella C, et al. Gela histological scoring system for post-treatment biopsies of patients with gastric MALT lymphoma is feasible and reliable in routine practice. *Br J Haematol*. 2013;160(1):47–52.
- 97 Spina V, Khiabani H, Brusca A, et al. The Coding Genome of Nodal Marginal Zone Lymphoma Reveals Recurrent Molecular Alterations of PTPRD and Other Jak/Stat Signaling Genes. *Blood (ASH Annual Meeting Abstracts) 2015;124(21):Abstract #705*.