

# Treatment of congenital aortic valve stenosis: impact of the Ross operation

Antonio F Corno, Jean-Jacques Goy, Michel Hurni, Maurice Payot, Nicole Sekarski, Ludwig K von Segesser

Service de chirurgie cardio-vasculaire, Centre Hospitalier Universitaire Vaudois, Lausanne, Suisse

## Summary

**Goal:** To evaluate the impact of the Ross operation, recently (1997) introduced in our unit, for the treatment of patients with congenital aortic valve stenosis.

**Methods:** The period from January 1997 to December 2000 was compared with the previous 5 years (1992–96). Thirty-seven children (<16 yrs) and 49 young adults (16–50 yrs) with congenital aortic valve stenosis underwent one of these treatments: percutaneous balloon dilatation (PBD), aortic valve commissurotomy, aortic valve replacement and the Ross operation. The Ross operation was performed in 16 patients, mean age 24.5 yrs (range 9–46 yrs) with a bicuspid stenotic aortic valve, 7/10 adults with calcifications, 2/10 adults with previous aortic valve commissurotomy, 4/6 children with aortic regurgitation following PBD, and 1/6 children who had had a previous aortic valve replacement with a prosthetic valve and aortic root enlargement.

**Results:** PBD was followed by death in two neonates (fibroelastosis); all other children survived PBD. Although there were no deaths, PBD in adults was recently abandoned, owing to un-

favourable results. Aortic valve commissurotomy showed good results in children (no deaths). Aortic valve replacement, although associated with good results (no deaths), has been recently abandoned in children in favour of the Ross operation. Over a mean follow-up of 16 months (2–40 months) all patients are asymptomatic following Ross operation, with no echocardiographic evidence of aortic valve regurgitation in 10/16 patients and with trivial regurgitation in 6/16 patients.

**Conclusions:** The approach now for children and young adults with congenital aortic valve stenosis should be as follows: (1) PBD is the first choice in neonates and infants; (2) Aortic valve commissurotomy is the first choice for children, neonates and infants after failed PBD; (3) The Ross operation is increasingly used in children after failed PBD and in young adults, even with a calcified aortic valve.

**Keywords:** aortic valve stenosis; aortic valve commissurotomy; aortic valve replacement; congenital heart defect; heart surgery; Ross operation

## Introduction

The Ross operation (auto-transplantation of the pulmonary valve into the aortic position) [1, 2] has recently (1997) been introduced in our unit as one of the options for the treatment of children

and young adults with aortic valve stenosis. We therefore decided to perform a retrospective study in order to assess the impact of this evolution in surgical management.

## Materials and methods

All medical records of patients treated for congenital aortic valve stenosis were reviewed, with the only exclusion criteria being an age of over 50 years. The patients were divided into groups of children (<16 years) and young adults (16–50 years). They all underwent one (or more) of four types of treatment: percutaneous balloon dilatation (PBD), aortic valve commissurotomy, aortic valve replacement and the Ross operation. All patients were grouped according to the last treatment received. Since the Ross operation was introduced in our unit in 1997, we

arbitrarily decided to analyse the period from January 1997 to December 2000 and compare it with the preceding five year period (1992–1996).

Table 1 summarises the treatment received by 20 children and 30 young adults during the earlier period (1992–1996) and by 17 children and 19 young adults during the latter period (1997–2000). Among the 16 patients (6 children and 10 young adults – mean age 24.5 years, range 9–46 years) who underwent a Ross operation for a stenotic bicuspid aortic valve, 4 children presented with

aortic regurgitation post-PBD (after 1, 9, 9 and 10 years), one child with previous aortic valve replacement with prosthetic valve and aortic root enlargement (6 years before), 7/10 adults with calcifications of the aortic valve, and 2/10 adults with a previous aortic valve commissurotomy (after 7 and 23 years). In one young adult patient the pulmonary valve used for the autotransplantation into the aortic position was a bicuspid valve, first detected at the intraoperative transoesophageal echocardiography. In all these patients the Ross operation was performed as aortic root replacement (Fig. 1). The autotransplanted pulmonary valve was replaced in the first 6 patients of our se-

ries with a conventional pulmonary homograft, in the last 10 cases with a new biological valved conduit constituted from glutaraldehyde preserved bovine jugular vein (Contegra®).

The mean duration of cardiopulmonary bypass was 170 minutes (range 126–215 min), the mean duration of aortic X-clamping was 98 minutes (range 80–124 min). In all patients myocardial protection was accomplished with antegrade blood cardioplegia at the beginning, and continuous retrograde blood cardioplegia through the coronary sinus during the entire duration of the aortic X-clamping.

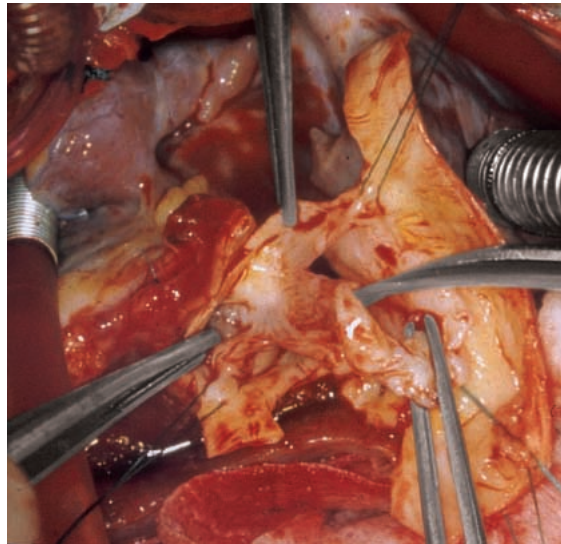
**Table 1**

Patient characteristics.

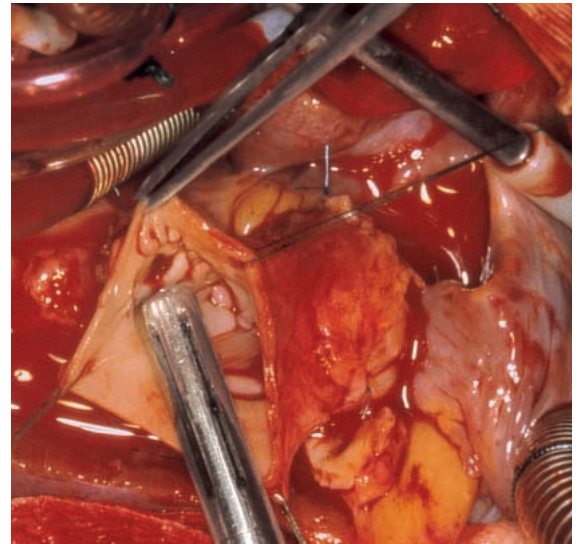
Period	age	percutaneous balloon dilatation	aortic valve commissurotomy	aortic valve replacement	Ross operation
1992–1996	<16 years	10	7	3	–
	16–50 years	5	0	25	–
1997–2000	<16 years	5	6	0	6
	16–50 years	0	0	9	10

**Figure 1**

A. Intraoperative photograph of the diseased native aortic valve in a child who underwent the Ross procedure at 9 years of age, after previous pulmonary balloon dilatation at 5 months of age. B. Intraoperative photograph of the same child during implantation of the pulmonary autograft (Ross operation) with the root replacement technique, with reimplantation of the coronary arteries.



A



B

## Results

### Percutaneous balloon dilatation

The first two neonates, in the initial period, undergoing PBD because of critical aortic stenosis, died. Autopsy showed a severe degree of left ventricular fibroelastosis in both. All the other children survived PBD, with 4/13 having undergone a Ross operation respectively after 1, 9, 9 and 10 years.

Although none died, PBD in adults was recently abandoned owing to unfavourable results: all 5 young adults who underwent PBD in the first period, required aortic valve replacement within the 2 years of follow-up.

### Aortic valve commissurotomy

Good results were obtained in all 13 children, with no deaths and no need for re-operation. Aortic valve commissurotomy has never been performed in adults in our department.

### Aortic valve replacement

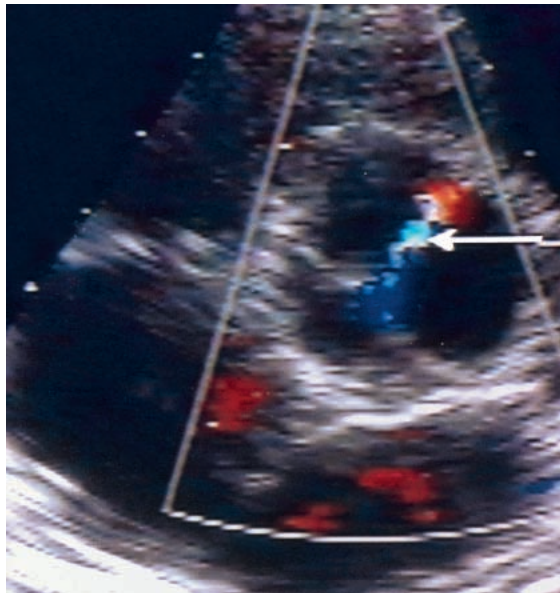
In children, despite good results (no deaths, one re-operation after 6 years because the child outgrew the prosthesis), the aortic valve replacement has recently been abandoned in favour of the Ross operation. In young adults with an indication for aortic valve replacement (despite good results with no deaths and no re-operation), the Ross operation has increasingly been taken into consideration as an alternative surgical option.

### Ross operation

In a mean follow-up of 16 months (2–40 months) all patients are alive, asymptomatic, without need for cardiac medication or anticoagulation, and have not required further interventions. Echocardiography prior to discharge showed absence of aortic valve regurgitation in 10/16 patients and a trivial or mild degree of aortic valve regurgitation in 6/16 patients (Fig. 2). At the last echocardiographic follow-up, those without re-

**Figure 2**

Postoperative echocardiography of the same patient (see Fig. 1), showing mild aortic valve regurgitation, one week after surgery.



gurgitation had not developed any, and there was no progression of aortic valve regurgitation amongst the others.

At the last echocardiographic control the following pressure gradients were measured across the newly constructed right ventricular outflow tract: peak gradient =  $21 \pm 3$  mm Hg, mean gradient  $11 \pm 2$  mm Hg. In none of the cases could more than a trivial degree of pulmonary valve regurgitation be detected.

No arrhythmias occurred during the perioperative period and all patients were in sinus rhythm at the last follow-up.

## Discussion

In 1967 [1] Ross described the use of the patient's own pulmonary valve to replace the diseased aortic and mitral valves. The new technique was considered too complex by the surgical community and was relegated to simple curiosity in the surgical armamentarium. In 1988, however, the reported long-term results of Ross's experience [2] with the pulmonary autograft in the aortic position encouraged an increasing number of surgeons around the world to initiate a series of this procedure. Since then more and more Ross operations have been performed, showing not only its feasibility, but more importantly, its advantages [3, 4]:

- superior haemodynamic performance compared to any other aortic valve replacement method, because of the ideal "effective orifice area" of the native pulmonary valve;
- very low thrombogenicity, with no requirement for anticoagulant therapy;
- demonstrable growth potential in the paediatric age-group;
- expected durability;
- active lifestyle.

The number of Ross operations performed worldwide has increased significantly in the last decade, as shown in the International Registry for the Ross procedure [5], with more than 500 procedures per year within the last 5 years.

The recent literature reviewed the anatomical basis allowing for the performance of the Ross operation [6], the use of different surgical techniques [7-9] and the results obtained by units with initial experience with this surgical procedure [10-12] as well as by more established centers evaluating the Ross operation as valve re-replacement [13].

### Indication for operation

A Ross operation with pulmonary autograft may be considered whenever replacement of the aortic valve is indicated. The expected durability, the very low thrombogenicity (no requirement for anticoagulant therapy) and the superior haemodynamic performance compared to any other aortic valve replacement method, would encourage the use of pulmonary autografts in young adults with an active lifestyle, women planning pregnancy and in patients with contraindications to treatment with warfarin [14, 15].

Rheumatic aortic valve disease, previously considered a contraindication for the Ross operation, has been treated with pulmonary autografts with good results in a large number of patients [16]. Some caution is required in young patients during the active phase of rheumatic disease and in the presence of severe concomitant mitral valve regurgitation.

Because of the demonstrable growth potential of pulmonary autografts implanted in the paediatric age-group [17-19], the indication for the Ross operation has been extended to early infancy for both simple and complex left ventricular outflow tract obstructions [20].

### Contraindications for the Ross operation

- *Primary abnormalities of the pulmonary valve.* When there is significant regurgitation of the pulmonary valve in preoperative surface or transoesophageal echocardiography its use as an aortic valve replacement should be discouraged. The use of a competent bicuspid pulmonary valve is controversial. In our experience we have on one occasion used a bicuspid pulmonary valve, detected at intraoperative transoesophageal echocardiography, demon-



strating good functioning at the first post-operative echocardiographic control.

- *Iatrogenic lesions of the pulmonary valve.* Pulmonary valves injured during excision from the right ventricular outflow tract should not be utilized.
- *Marfan syndrome.* It is considered a contraindication for using pulmonary autografts because of the abnormal structural morphology of the pulmonary valve.
- *Autoimmune tissue diseases.* Like other connective tissue disorders, systemic lupus erythematosus and rheumatoid arthritis are contraindications for the use of pulmonary autografts.

### Results

In large series [2–5, 11, 12, 16, 20] and in the International Registry for the Ross procedure [5] a relatively low early (3.5%) and late (<2%) mortality has been reported. These results compared with the conventional aortic valve replacement with mechanical or biological prostheses, favour the Ross operation, despite its technical complexity and its limited tolerance of errors. In our experience we had no early or late deaths in the initial group of 16 patients.

### Re-operation

Ross reported 33 re-operations in 399 patients followed for 24 years [21], with 19 patients re-operated for technical problems with valve insertion early in the experience, when the surgical technique used the sub-coronary valve replacement method. With the current technique of aortic root replacement, adopted since the beginning of our experience, the technical problems should be a less prominent cause for re-operation.

Dilatation of the neo-aortic annulus, with subsequent aortic valve regurgitation, was the most frequent cause for re-operation [3–5, 7–9, 21]. This problem occurred more frequently when the Ross operation was performed for aortic valve regurgitation than in aortic valve stenosis, and technical modifications have been introduced to achieve external fixation of the new aortic annulus thereby preventing this problem [4, 5, 7, 8, 22]. Nevertheless the International Registry reports absence of this problem for autograft reoperation in 97% of patients at 5 years [5].

The second commonest cause for re-operation is the pulmonary homograft replacement, particularly in the paediatric population, where a small homograft is inserted initially. In the large population reported in the International Registry for the Ross procedure [5] the need for pulmonary homograft replacement is currently 1.5% at 5 years. In the last 10 pulmonary valve replacement patients of our experience, we used a new biological valved conduit constituted by a gluteraldehyde preserved bovine jugular vein (Contegra®). The preliminary results of this type of conduit are encouraging and have also been reported after im-

plantation for complex congenital heart defects [23]. So far none of our patients have needed re-operation in a mean follow-up of 16 months.

### Potential complications

Potential complications of a Ross operation include the following:

- injury to the pulmonary autograft during preparation/implantation; in this case the surgeon has to be ready to switch to the conventional aortic valve replacement;
- injury to the left coronary artery, because of its anatomical position; very accurate dissection is required, possibly by a surgeon with experience in complex congenital heart surgery;
- poor myocardial protection, because of the long aortic X-clamping time; in our experience this complication has been avoided by the routine use of continuous retrograde blood cardioplegia through the coronary sinus, therefore avoiding myocardial ischaemia during the entire duration of the aortic X-clamping;
- bleeding, because of adhesions in the case of previous surgery, extensive dissection and long duration of cardiopulmonary bypass; in our experience, thanks to very accurate dissection and haemostasis immediately after every anastomosis, together with the routine use of tissue glue and aprotinine, chest re-opening because of bleeding was never required.

### Conclusions

The preliminary results of the recent introduction of the Ross operation in our unit, as a surgical option to treat patients with congenital aortic valve stenosis, have been encouraging, with no early or late mortality, no re-operation, and more than satisfactory aortic valve functioning.

As a result of this retrospective study, showing a positive impact of the Ross operation in the management of patients with aortic valve stenosis, the approach for treating children and young adults in our unit with congenital aortic valve stenosis is now as follows: (1) percutaneous balloon dilatation is the first choice in neonates and infants; (2) aortic valve commissurotomy is the first choice in children, and in neonates and infants after failed percutaneous balloon dilatation; (3) the Ross operation is increasingly used in children after failed percutaneous balloon dilatation, in young adults, even with calcified aortic valve, and particularly in patients with an active lifestyle or women anticipating pregnancy.

---

*Correspondence:*

Antonio F. Corno, MD, FRCS

Centre Hospitalier Universitaire Vaudois

46, rue du Bugnon

CH-1011 Lausanne

E-mail: antonio.corno@chuv.hospvd.ch

## References

- 1 Ross DN. Replacement of the aortic and mitral valves with a pulmonary autograft. *Lancet* 1967;II:956-8.
- 2 Ross DN. Pulmonary valve autotransplantation: the Ross operation. *J Card Surg* 1988;3:313-9.
- 3 Oury JH. Clinical aspects of the Ross procedure. *Semin Thorac Cardiovasc Surg* 1996;8:328-35.
- 4 Elkins RC. Aortic valve: The Ross operation – a 12-year experience. *Ann Thorac Surg* 1999;68:514-8.
- 5 Oury JH, Mackey SK, Duran CMG. Critical analysis of the Ross procedure: do its problems justify wider application? *Semin Thorac Cardiovasc Surg* 1999;11:55-61.
- 6 Merrick AF, Yacoub MH, Ho SY, Anderson RH. Anatomy of the muscular subpulmonary infundibulum with regard to the Ross procedure. *Ann Thorac Surg* 2000;69:556-61.
- 7 Skillington PD, Fuller JA, Grigg LE, Yapanis AG, Porter GF. Ross procedure. Inserting the autograft using a fully supported replacement method; techniques and results. *J Heart Valve Dis* 1999;8:593-600.
- 8 Klena JW, Shweiki E, Mahaffey HW, Woods EL, Benoit CH, Gilbert CL. Annuloplasty and aortoplasty as modifications of the Ross procedure for the correction of geometric mismatch. *J Heart Valve Dis* 2000;9:195-9.
- 9 Schmidtke C, Bechtel JF, Hueppe M, Noetzold A, Sievers HH. Size and distensibility of the aortic root and aortic valve function after different techniques of the Ross procedure. *J Thorac Cardiovasc Surg* 2000;119:990-7.
- 10 Sharoni E, Katz J, Dagan O, Lorber A, Hirsch R, Blieden LC, et al. The Ross operation: initial Israeli experience. *Isr Med Assoc J* 2000;2:115-7.
- 11 Moidl R, Simon P, Aschauer C, Chevchik O, Kupilik N, Rodler S, et al. Does the Ross operation fulfil the objective performance criteria established for new prosthetic heart valves? *J Heart Valve Dis* 2000;9:190-4.
- 12 Savoye C, Auffray JL, Hubert E, Godart F, Francart C, Goullard L, et al. Echocardiographic follow-up after Ross procedure in 100 patients. *Am J Cardiol* 2000;85:854-7.
- 13 Carr-White GS, Glennan S, Edwards S, Ferdinand FD, De-souza AC, Pepper JR, et al. Pulmonary autograft versus aortic homograft for re-replacement of the aortic valve: results from a subset of a prospective randomized trial. *Circulation* 1999;100(Suppl II):103-6.
- 14 Oury JH, Hardy BG, Luo HH, Maxwell M, Duran CM. Expanding indications for the Ross procedure. *Ann Thorac Surg* 1999;68:1403-6.
- 15 Gatzoulis MA. Ross procedure: the treatment of choice for aortic valve disease? *Int J Cardiol* 1999;71:205-6.
- 16 Pieters FA, Al-Halees Z, Hatle L, Shahid MS, Al-Amri M. Results of the Ross operation in rheumatic versus non-rheumatic aortic valve disease. *J Heart Valve Dis* 2000;9:38-44.
- 17 Puntel RA, Webber SA, Eteddgui JA, Tacy TA. Rapid enlargement of neo-aortic root after the Ross procedure in children. *Am J Cardiol* 1999;84:747-9.
- 18 Solymar L, Sudow G, Holmgren D. Increase in size of the pulmonary autograft after Ross operation in children: growth or dilatation? *J Thorac Cardiovasc Surg* 2000;119:4-9.
- 19 Solowiejczyk DE, Bourlon F, Apfel HD, Hordof AJ, Hsu DT, Crabtree G, et al. Serial echocardiographic measurements of the pulmonary autograft in the aortic valve position after the Ross operation in a pediatric population using normal pulmonary artery dimensions as the reference standard. *Am J Cardiol* 2000;85:1119-23.
- 20 Marino BS, Wernovsky G, Rychik J, Bockoven JR, Godinez RI, Spray TL. Early results of the Ross procedure in simple and complex left heart disease. *Circulation* 1999;100(Suppl II):162-6.
- 21 Ross DN, Jackson M, Davies J. Pulmonary autograft aortic valve replacement: long-term results. *J Cardiac Surg* 1991;6:529-33.
- 22 David TE, Omran A, Ivanov J, Armstrong S, de Sa MP, Sonnenberg B, et al. Dilatation of the pulmonary autograft after the Ross procedure. *J Thorac Cardiovasc Surg* 2000;119:210-20.
- 23 Hurni M, Corno AF, Tucker OP, Payot M, Sekarski N, Cotting J, et al. Venpro a new pulmonary valved conduit. *Thorac Cardiovasc Surg* 2000;48(Suppl I):120.

## The many reasons why you should choose SMW to publish your research

### What Swiss Medical Weekly has to offer:

- SMW's impact factor has been steadily rising, to the current 1.537
- Open access to the publication via the Internet, therefore wide audience and impact
- Rapid listing in Medline
- LinkOut-button from PubMed with link to the full text website <http://www.smw.ch> (direct link from each SMW record in PubMed)
- No-nonsense submission – you submit a single copy of your manuscript by e-mail attachment
- Peer review based on a broad spectrum of international academic referees
- Assistance of our professional statistician for every article with statistical analyses
- Fast peer review, by e-mail exchange with the referees
- Prompt decisions based on weekly conferences of the Editorial Board
- Prompt notification on the status of your manuscript by e-mail
- Professional English copy editing
- No page charges and attractive colour offprints at no extra cost

### Editorial Board

Prof. Jean-Michel Dayer, Geneva  
 Prof. Peter Gehr, Berne  
 Prof. André P. Perruchoud, Basel  
 Prof. Andreas Schaffner, Zurich  
 (Editor in chief)  
 Prof. Werner Straub, Berne  
 Prof. Ludwig von Segesser, Lausanne

### International Advisory Committee

Prof. K. E. Juhani Airaksinen, Turku, Finland  
 Prof. Anthony Bayes de Luna, Barcelona, Spain  
 Prof. Hubert E. Blum, Freiburg, Germany  
 Prof. Walter E. Haefeli, Heidelberg, Germany  
 Prof. Nino Kuenzli, Los Angeles, USA  
 Prof. René Lutter, Amsterdam, The Netherlands  
 Prof. Claude Martin, Marseille, France  
 Prof. Josef Patsch, Innsbruck, Austria  
 Prof. Luigi Tavazzi, Pavia, Italy

We evaluate manuscripts of broad clinical interest from all specialities, including experimental medicine and clinical investigation.

We look forward to receiving your paper!

Guidelines for authors:

[http://www.smw.ch/set\\_authors.html](http://www.smw.ch/set_authors.html)

### Impact factor Swiss Medical Weekly




**EMH** **FMH**  
**SCHWABE**  
 Editores Medicorum Helveticorum

All manuscripts should be sent in electronic form, to:

EMH Swiss Medical Publishers Ltd.  
 SMW Editorial Secretariat  
 Farnsburgerstrasse 8  
 CH-4132 Muttenz

Manuscripts: [submission@smw.ch](mailto:submission@smw.ch)  
 Letters to the editor: [letters@smw.ch](mailto:letters@smw.ch)  
 Editorial Board: [red@smw.ch](mailto:red@smw.ch)  
 Internet: <http://www.smw.ch>