

Prevention and therapy of leg ischaemia in extracorporeal life support and extracorporeal membrane oxygenation with peripheral cannulation

Ludwig K. von Segesser^a, Sotirios Marinakis^b, Denis Berdajs^c, Enrico Ferrari^d, Markus Wilhelm^e, Francesco Maisano^e

^a Department of Surgery and Anaesthesiology, CHUV, Lausanne, Switzerland

^b Department of Cardiothoracic Surgery, CHU Charleroi, Belgium

^c Herzchirurgie, Triemlispital, Zurich, Switzerland

^d CardioCentro, Lugano, Switzerland

^e Herz- und Gefässchirurgie, Universitätsspital, Zürich, Switzerland

Summary

Extracorporeal membrane oxygenation (ECMO) and extracorporeal life support (ECLS) have been around for a long time, but it is only in recent years, with the advent of acute respiratory distress syndrome consecutive to influenza A (H1N1) infection, that these life-saving technologies have seen a broader application. Although the results of ECLS and ECMO are perceived as generally encouraging, there are still disturbing complications related to peripheral cannulation in general and, more specifically, to cannulation in the groin. The present review was designed to assess the magnitude of this latter problem, i.e. leg ischaemia related to ECLS and ECMO, in the literature and to identify strategies for possible therapies and, more importantly, prevention.

The search strategy selected identified seven original articles with more than twenty patients, totalling 407 patients who underwent veno-arterial ECMO, and one large review dealing with all kinds of complications. For the original reports, the number of cases with veno-arterial support ranged from 21 to 143, with, as far as available, frequency of ischaemic complications between 11% and 52%, a reported range of surgical intervention between 9% and 22%, and a leg amputation rate from 2% to 10%. It appears that the number of reports dealing with lower extremity ischaemia during ECMO increases in parallel with the number of reports about ECMO. Strategies for early detection of peripheral ischaemia, interventions for efficient reperfusion, and measures for prevention including new concepts with smaller and eventually bidirectional arterial cannulas are discussed.

Key words: extra-corporeal life support; ECLS; extracorporeal membrane oxygenation; ECMO; lower extremity ischaemia; fasciotomy; amputation; cannulation; cannula

Introduction

Although the pump-oxygenator was initially conceived for supporting the failing lungs [1], its main application became temporary cardiorespiratory support enabling open surgery on the arrested heart. Problems thereafter naturally prompted its short-term use for supporting the failing heart and lungs. It is since the 1970s that extracorporeal membrane oxygenation (ECMO) and extracorporeal life support (ECLS) came along [2, 3] as stand-alone procedures, but it is only in recent years with the advent of acute respiratory distress syndrome consecutive to influenza A (H1N1) infection [4] that these life-saving technologies [5] have seen a broader application. As outlined above, there are basically three indications for extracorporeal life support with a pump-oxygenator: severe respiratory failure, severe cardiac failure, and cardiorespiratory failure. The preferred approach for essentially respiratory failure is veno-venous ECMO providing additional extrapulmonary gas transfer for both O₂ and CO₂. This approach has the advantage of requiring vascular access on the low pressure venous side only and can usually be realised with peripheral venous cannulation [6]. By definition, there is no circulatory support with veno-venous ECMO. For assisting the failing heart with a pump oxygenator, veno-arterial ECLS is preferred. Although a pump alone is sufficient to provide flow, access to either the isolated pulmonary circulation or the isolated systemic circulation is technically demanding, and therefore veno-arterial ECLS allowing for peripheral venous drainage and peripheral arterial return is usually applied outside of the operating theatre [6]. Overall, the results of ECLS and ECMO are perceived as generally encouraging [7], but there are still disturbing complications related to peripheral cannulation in general and, more specifically, to cannulation in the groin. The present review was designed to assess the magnitude of this latter problem – leg ischaemia related to ECLS and ECMO – in the literature and to identify strategies for possible therapies and more importantly, prevention.

Materials and methods

A PubMed search was realised on April 26, 2015 with the following search terms:

- ECLS limb ischemia
- ECLS amputation
- ECMO limb ischemia
- ECMO amputation

A list with the most pertinent reports, including more than 20 patients and related to the issues raised here, can be found in table 1.

Recommendations for treatment of limb ischaemia related to ECLS and ECMO were extracted from the papers mentioned in table 1, other pertinent reports in the literature and the clinical experience of the co-authors. The same approach was used to identify hints for prevention of limb ischaemia related to ECLS and ECMO.

Limb ischaemia and amputation related to ECLS and ECMO

ECLS and limb ischaemia

The PubMed search described above provided seven hits for the search term “ECLS limb ischemia”. The first publication appeared in February 1996 and the last one in July 2014. Typically, there was one publication every 3 years. However, there was no hit at all for the search term “ECLS amputation”.

ECMO and limb ischaemia

A somewhat different picture appeared for the search term “ECMO limb ischemia” with 67 hits, the first one in July 1995 and the last one in April 2015, or typically two publications per year (fig. 1). There were also more reports with the search term “ECMO amputation” than with the corresponding search for ECLS, with 28 hits, the first one being from November 2008 and the last one from April 2015. For recent years there were up to five publications per year about amputation in the context of ECMO.

The most pertinent reports on ECMO and limb ischaemia are shown in table 1. It turns out that limb ischaemia is essentially reported in studies reporting results for veno-arterial perfusion in ECLS or ECMO. There is also a more general review about ECLS and ECMO by Cheng and colleagues including all types of complications (see below). For the original reports listed here the number of cases with veno-arterial support ranged from 21 to 143, with, as far as available, a frequency of ischaemic complications between 11% and 52%, a reported rate of surgical intervention of between 9% and 22%, and a leg amputation rate ranging from 2% to 10%.

The review by Cheng et al. [15] mentioned above focused on complications of ECMO for cardiogenic shock and included 20 studies with more than 10 patients after the year 2000. The authors compiled a total of 1866 cases with a survival of 534/1529 patients or 35% (range 20.8–65.4%). The most frequent complications observed in this setting were acute kidney injury (55.6%), bleeding (40.8%), major infection (30.4%) and neurological deficits (13.3%). Lower extremity ischaemia occurred in 16.9% (range 12.5–22.6%), compartment syndrome and fasciotomy accounted for 10.3% (range 7.3–14.5%), and lower extremity amputation was required in 4.7% (range 2.3–9.3%). The latter finding is very much in line with the seven studies from the current searches listed in table 1, where the lower extremity amputation rate was 2% to 10%.

Although ranking only fourth in frequency of the most frequent complications observed, lower extremity ischaemia related to ECLS and ECMO is a very serious problem, resulting most of the time in compartment syndrome and fasciotomy with a high risk for a functional deficit or an amputation which is mutilating at best, and eventually carries a high risk for a lethal outcome.

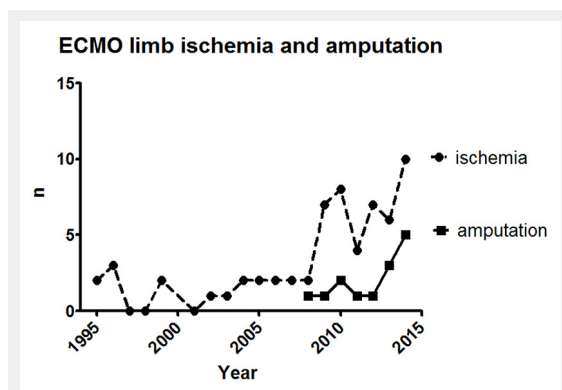


Figure 1
Number of reports on limb ischaemia and amputation in relation to extracorporeal membrane oxygenation (ECMO).

Table 1: Key references including more than twenty patients drawn from Pub Med for lower extremity ischaemia in veno-arterial extracorporeal membrane oxygenation (ECMO) with peripheral cannulation.

Ref. no.	Year	Author	v-a ECMO n	Ischaemia	Surgery	Amputation
[8]	2010	Foley, et al.	43	7	4	1 (2%)
[9]	2010	Gander, et al. (paediatric)	21	11 (52%)		2 (10%)
[10]	2011	Bisdas, et al.	143	15 (11%)		2 (1%)
[11]	2013	Guo, et al.	26	8 (31%)	6 (22%)	2 (8%)
[12]	2013	Deschka, et al. (central)	28			1 (4%)
[13]	2014	Mohite, et al.	45	9 (20%)	4 (9%)	1 (2%)
[14]	2014	Aziz F, et al.	101	18	16	1
[15]	2014	Cheng, et al. (review)	1866		(16.9%)	(4.7%)

v-a ECMO n = number of patients with veno-arterial ECMO
 Ischaemia = number of patients (%) with lower extremity ischaemia
 Surgery = number of patients (%) requiring surgery for lower extremity ischaemia
 Amputation = number of patients (%) requiring lower extremity amputation
 Note: n and (%) values given are cited from the references given.

Diagnosis of limb ischaemia related to ECLS and ECMO

It is good clinical practice to verify that there is sufficient distal perfusion after insertion of arterial and/or venous cannulas into the femoral vessels by making sure that adequate pulses are present at the level of the dorsalis pedis artery as well as the posterior tibial artery of the lower extremities involved on one side, and that no signs of venous stasis are present on the other. However, in the critically ill with centralised circulation, peripheral vasoconstriction, either natural and/or due to vasoconstricting medication, and complete absence of a pulse wave in cases fully dependant on veno-arterial ECMO with continuous flow, the assessment of the quality of peripheral perfusion can be a major challenge, despite Doppler-ultrasonography, pulse-oximetry, lactate levels and other adjuncts.

In conscious individuals, the information provided by the patients themselves (absence of pain, presence of mobility and sensitivity) are most helpful for decision making. However, in the deeply sedated subject, it is much more difficult to assess whether distal perfusion is adequate or not. It has to be remembered here, that for restoring end-organ perfusion, the window in time is quite narrow. For the lower extremity, every effort possible has to be made to avoid peripheral ischaemia for more than 6 hours, the traditionally accepted window for reversible ischaemia.

Therapies for limb ischaemia related to ECLS and ECMO

The 6-hour period allowed for sufficient reperfusion has been recently reconfirmed by Spurlock et al. [16], who demonstrated that additional retrograde reperfusion through the tibial artery within 6 hours avoided amputations completely, whereas the same procedure after 6 hours was burdened with a 20% amputation rate or permanent neurological deficit. Of course, retrograde limb perfusion through the tibial artery is not the only limb-salvaging approach in cannula-related ischaemia of the lower extremity. Alternative measures for re-establishing adequate antegrade arterial flow include insertion of an additional arterial cannula for distal perfusion, exchange of the occluding cannula for one with a smaller calibre that allows for antegrade flow, addition of a graft for maintenance of distal perfusion, etc. The problem with all these measures is, of course, that in the critically ill, and this is part of the most frequent indication for ECLS and ECMO, all additional interventions carry a significant risk. In contrast to other clinical situations with peripheral ischaemia, there is an additional problem in the ECLS and ECMO setting due to the fact that the patients are usually anticoagulated to some degree in order to prevent pump-oxygenator coagulation and/or occlusion. Furthermore, there are also logistic and practical reasons that discourage additional procedures in ECLS- and ECMO-dependant patients, including transportation to an operating theatre, a major challenge, whereas the environment for surgery in the intensive care unit is most of the time sub-optimal. Although wire skills for de-/re-cannulation are helpful for a percutaneous approach, this will also be a major challenge most of the time, because

of the complexity of the transfer of an unstable patient to a radiology suite. Very often, a C-arm for fluoroscopy at the bed side can be made available at best, compared with no imaging possibility at worst.

Venous stasis due to cannulas in the femoral vessels and venous compression due to haematomas at the cannulation sites (personal experience) are also an issue and should not be underestimated. Usually, the appearance of the latter is initially less dramatic, requires more time to develop, and, correspondingly, there seems also to be a larger time window for correction. As for other medical complications, and this holds true for both the venous and the arterial side [17], the prevention of their occurrence is superior to any cure.

How to prevent limb ischaemia related to ECLS and ECMO

Risk reduction with regard to lower extremity ischaemia related to ECLS and ECMO is a major challenge because, in the critically ill, it can occur without cannulation of the femoral vessels at all. One phenomenon is known as acral necrosis and it can be, among other reasons, a result of low cardiac output with or without vasoconstricting agents. Having stated this, it becomes clear that the stage for lower extremity ischaemia in ECLS and ECMO may have been set prior to cannulation, and the latter is only the trigger to worsen an already lost battle. As a matter of fact, lower extremity ischaemia has even been reported for patients undergoing ECMO with central cannulation [12].

However, we strongly believe that a systematic approach, taking into account the anamnesis of the patient, the anatomy, the pathology, the physiology, the available perfusion technology and the available surgical and interventional skills, as well as the overall ECLS and ECMO strategy, has the potential not only for risk reduction but also for improved recovery.

With regard to the anamnesis, it is key to know whether a candidate for ECLS and ECMO has any of the well-known risk factors including vascular diseases, Raynaud's disease, collagenoses, coagulation disorders and heparin-induced thrombocytopenia, to name a few. Although the risk factors mentioned may be considered only relative contraindications for ECLS and ECMO, their accumulation does certainly not improve the prognosis.

With regard to anatomy and pathology, it is the selection of the optimal cannulation site that can make the difference [18, 19]. In short, it is important to allow for collateral flow on both the arterial and the venous side, and therefore it is recommended not to compromise the deep femoral vessels. Hence the preferred level for cannula insertion into the common femoral vessels is cephalad to the origin of the deep femoral vessels. It goes without saying that pathological vessels segments with arteriosclerotic plaque should be avoided whenever possible and thus ultrasonic assessment of the access vessels should be routine prior to cannulation.

With regard to physiology, it is recommended to place venous femoral cannulas on the contralateral side with reference to arterial femoral cannulas (fig. 2). Of course, it is well known that the arterial cannula in the common femor-

al artery can be occlusive or subocclusive, and the perfusion of the ipsilateral lower extremity is mainly dependant on collateral in-flow through the deep femoral artery as outlined above. Likewise, venous drainage of a lower extremity with a large venous cannula within the common femoral vein is maintained in part by collateral out-flow through the deep femoral vein. However, venous drainage through a collateral network certainly implies some degree of stasis as compared with straightforward drainage through an intact femoro-iliaco-caval axis. This venous stasis favours oedema formation, increases the diffusion distance and, in combination with the distal hypoperfusion due to an ipsilateral occlusive arterial cannula, further reduces the arteriovenous pressure gradient. All these factors contribute to reduced end-organ perfusion of the lower extremity with proximal cannulas in place and may result in irreversible tissue damage. Hence, the recommendation is to avoid whenever possible ipsilateral femoral venous cannulation if there is already a femoral arterial cannula in place.

With regard to the cannulation in general, the percutaneous approach is given preference whenever possible over open and half-open techniques. The main reason for this recommendation is the fact that some degree of long-term anticoagulation is recommended/required for prevention of pump-oxygenator thrombosis and that bleeding is one of the most frequent complications during ECLS and ECMO, as reported by Cheng (40.8%) [15]. Hence, any stitch and/or incision can become the origin of a major problem during long-lasting perfusions, which can go for weeks and months. In contrast, the percutaneous approach derived from the original Seldinger technique can take advantage of the fact that any dilator or cannula inserted over the wire has a larger diameter than the previous one and therefore contributes to its own haemostasis by compression of the adjacent tissue/capillaries. Indeed, a very clever approach. Of course there are situations where the percutaneous approach is not possible or not successful, for example during

cardiopulmonary resuscitation or in patients with pathological vessels, or previously catheterised, operated or occluded vessels.

With regard to the perfusion strategy, systematic antegrade and retrograde perfusion of the cannulated access vessel is recommended. There are several techniques to achieve this, the most traditional one being the connection of an end-to-side graft to the femoral vessels in order to maintain both the proximal and the distal patent for continuous perfusion. Unfortunately, an end-to-side anastomosis to a vessel still requires a surgical approach and it is therefore not our preferred option. As outlined above, a fully percutaneous technique is strongly recommended, and thus the most frequent approach on the arterial side is dual cannulation, with a distal, ancillary cannula first, as long as distal pulsations are palpable, and a proximal main cannula second.

It is important to mention here that the selection of the cannula size can be a challenge for both the antegrade and the retrograde perfusion paths. This may seem evident for the main systemic cannula, which is initially selected as a function of the target flow. The latter is a function of the problems of the patient to be bridged, and his or her body surface area to be calculated from the height and the bodyweight. Basically, there are three scenarios to be considered:

- a) Respiratory support
- b) Circulatory support
- c) Combinations

Flow requirements may vary for patients requiring respiratory support with normal or compensatory supranormal heart function versus patients requiring circulatory support and combinations of the two. If the heart is arrested, full circulatory support is necessary and unloading of the left heart may be indicated. Likewise, for a severe white lung syndrome, relatively high blood flows are required in order to provide adequate gas transfer. In septic patients, even higher flows may be necessary. In most full size adult patients a 24F arterial cannula is sufficient to provide antegrade flows above the target value of 2.4 l/min/m² for normothermic perfusion at rest, even if arterial line pressures above 100 mm Hg may be required. Thinner arterial cannulas are mandatory for smaller patients and ultimately it is the luminal width of the access vessel which determines the maximal cannula size that can be inserted.

For perfusion of the inferior extremity dependant on the cannulated access artery, the selection of the second smaller cannula for caudal perfusion is often determined less by flow, and more by convenience. The option of using an introducer sheath with a side arm for this purpose, instead of a paediatric arterial cannula, has been introduced many years ago. We have used with good results a 10F introducer sheath for this purpose. It typically adds more than 100 ml/min additional flow to the flow provided by the collaterals. However, it has to be mentioned here that the flow ultimately achieved with an introducer sheet fed by a sidearm is not only size dependant, but also dependant on the arterial line pressure, which in turn is a function of the pump flow, the size of the main arterial cannula, the patient's blood pressure, vasoconstricting medication and other factors. In the event of doubt, use of a clamp-on flow probe is recommended, as is routine in paediatric perfusion

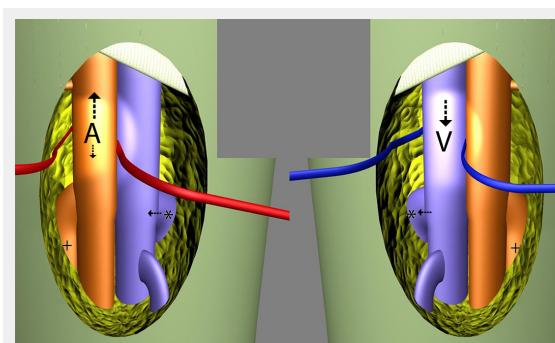


Figure 2

Schematic view of ipsilateral dual arterial cannulation and contralateral venous cannulation just caudal to the inguinal ligaments: systemic arterial cannulation (A) cephalad to the deep femoral artery (+), ipsilateral second arterial cannulation (D) for distal perfusion and contralateral venous cannulation (V) cephalad to the deep femoral vein (*). Collateral venous drainage is possible via the bilateral deep femoral veins (*) and the pelvic collaterals. The same holds true for the collateral flow via the bilateral deep femoral arteries (+). Although percutaneous cannulation on a routine basis is preferred, an open technique is displayed here for better identification of the femoral vessels and their branches.

where the arterial line also feeds a haemofilter. As a matter of fact, a no-flow situation may occur even in the presence of a second cannula, which may be stuck in a collateral. The proof that cannula size for lower extremity perfusion in ECLS and ECMO matters was provided by Mohite et al. [13, 20], who reported a 30.6% ischaemia rate and a 15.4% surgery or amputation rate for 6F to 8F introducer sheaths in 13 patients versus 15.6% ischaemia and 6.3% surgery or amputation rate for 10F to 12F cannulas. Hence, a 50% reduction of both ischaemia and surgery, respective amputation rates by using larger cannulas and thus higher flows.

Outlook

Recently, a trend to use smaller arterial cannulas that do not require the full lumen of the access vessel and permit parallel retrograde flow in order to maintain continuous lower extremity perfusion has emerged. This is an interesting concept because, in theory, it allows not only reduction in the number of access points with all their inherent complications, but also simplification of the perfusion circuit, the number of lines (in some cases pumps to be supervised) and, certainly, the overall complexity of the procedure. There can be no doubt that this is an elegant solution in patients requiring partial support by ECLS or ECMO. Naturally, this approach comes also at a cost. The latter is related to the higher driving pressures required for perfusion with arterial cannulas having a smaller luminal width, which in turn carries the risk of excessive haemolysis [21], resultant renal failure, etc. In patients requiring

full cardiopulmonary support, i.e. with target flows of 2.4 l/min/m² or even more as in toxic or septic shock and other life-threatening situations, a cannulation where the systemic flow is restricted can become a major limitation with severe drawbacks. It can, therefore, not be recommended as a general strategy for routine use.

Based on the positive results with long term use of self-expanding cannulas in the ECMO setting [22] and the experience in the literature showing that temporary caval filters can be removed easily for up to 3 months [23], we explored the potential for the development of virtually wall-less cannulas for the arterial side [24], allowing for bidirectional perfusion. As a matter of fact, the performance increase achieved with modern virtually wall-less cannula designs (fig. 3) can be attributed not only to more flow for a given cannula insertion diameter, but also a given target flow to a smaller cannula diameter for the cannula access section such that not only antegrade, but also sufficient retrograde, flow remains possible. Figure 4 displays the concept for an improved bidirectional cannula, with its sealed narrow segment within the access vessel allowing for retrograde flow in parallel, and a virtually wall-less stabilising section further downstream feeding in both directions antegrade and retrograde. In comparison with a straight cannula with the same access diameter, the flow limiting narrow segment of the bidirectional design requires only a fraction of the total cannula length and thus higher flows are possible for the same access diameter and the same pressure drop. Early experimental assessment confirms the concept proposed.




Figure 3

Thin wall percutaneous cannula (top), collapsed virtually wall-less cannula prior to insertion (centre), and virtually wall-less cannula expanded *in situ* (bottom).

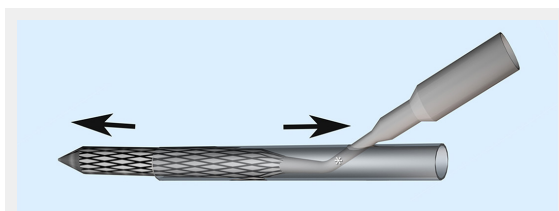


Figure 4

Schematic view of the concept for a new virtually wall-less cannula designed for bidirectional flow. The performance gain achieved with the virtually wall-less cannula design can be attributed to a short, narrower (*), somewhat less performant cannula segment at the point of insertion (centre), which allows not only for antegrade flow (left), but also for some back flow in parallel towards the limb (right).

Disclosure statement: L. K. von Segesser is founder of Smartcanula LLC.

Correspondence: Professor Ludwig K. von Segesser, Department of Surgery and Anaesthesiology, CHUV, BH 05-105, Rue du Bugnon 46, CH-1011 Lausanne, [LK\[at\]Segesser.com](mailto:LK[at]Segesser.com)

References

- Gibbon JH. Maintenance of cardiorespiratory functions by extracorporeal circulation. *Circulation*. 1959;19:646–56.
- Bartlett RH, Gazzaniga AP, Fong SW, Burns NE. Prolonged extracorporeal cardiopulmonary support in man. *J Thorac Cardiovasc Surg*. 1974;68:918–32.
- Kolobow T, Gattinoni L, Tomlinson T, Pierce JE. An alternative to breathing. *J Thorac Cardiovasc Surg*. 1978;75:261–8.
- Australia and New Zealand Extracorporeal Membrane Oxygenation (ANZECMO) Influenza Investigators. Extracorporeal membrane oxygenation for 2009 Influenza A(H1N1) acute respiratory distress syndrome. *JAMA*. 2009;302:1888–95.
- Beckmann A, Benk C, Beyersdorf F, Haimert G, Merkle F, Mestres C, Pepper J, Wahba A, and on behalf of the ECLS Working Group. Position Article for the use of extracorporeal life support in adult patients. *Eur J Cardio-Thorac Surg*. 2011;40:676–81.
- Berdajs D. Troubleshooting in extracorporeal life support. *Swiss Med Wkly*. 2015;145: w14117.
- Gray BW, Haft JW, Hirsch JC, Annich GM, Hirschl RB, Bartklett RH. Extracorporeal life support: experience with 2000 patients. *ASAIO J*. 2015;61:2–7.

- 8 Foley PJ, Morris RJ, Woo EY, Acker MA, Wang GJ, Fairman RM, Jackson BM. Limb ischemia during femoral cannulation for cardiopulmonary support. *J Vasc Surg.* 2010;52:850–3.
- 9 Gander JW, Fisher JC, Reichstein AR, Gross ER, Aspelund G, Middlesworth W, Stolar CJ. Limb ischemia after common femoral artery cannulation for venoarterial extracorporeal membrane oxygenation: an unresolved problem. *J Pediatr Surg.* 2010;45:2136–40.
- 10 Bisdas T, Beutel G, Warnecke G, Hoepfer MM, Kuehn C, Haverich A, Teebken OE. Vascular complications in patients undergoing femoral cannulation for extracorporeal membrane oxygenation support. *Ann Thorac Surg.* 2011;92:626–31.
- 11 Guo Z, Li X, Chang X. Cannulation related complications and prevention for extracorporeal membrane oxygenation: clinical report and reviews of experience of 34 cases. *Zhonghua Wai Za Zhi.* 2013;51:804–7. Chinese.
- 12 Deschka H, Machner M, El Dsoki S, Alken A, Wimmer-Greinecker G. Central closed chest implantation of extracorporeal membrane oxygenation to prevent limb ischemia. *Int J Artif Organs.* 2013;36:687–92.
- 13 Mohite PN, Fatullayev J, Mounz O, Kaul S, Sabashnikov A, Weymann A, et al. Distal limb perfusion: Achilles' heel in peripheral venoarterial extracorporeal membrane oxygenation. *Artif Organs.* 2014;38:940–4.
- 14 Aziz F, Brehm CE, El-Banyosy A, Han DC, Atnip RG, Reed AB. Arterial complications in patients undergoing extracorporeal membrane oxygenation via femoral cannulation. *Ann Vasc Surg.* 2014;28:178–83.
- 15 Cheng R, Hachamowitch R, Kittleson M, Patel J, Arabia F, Moriquichi J, et al. Complications of extracorporeal membrane oxygenation for treatment of cardiogenic shock and cardiac arrest: a meta-analysis of 1866 adult patients. *Ann Thorac Surg.* 2014;97:610–6.
- 16 Spurlock DJ, Toomasian JM, Romano MA, Cooley E, Bartlett RH, Haft JW. A simple technique to prevent limb ischemia during veno-arterial ECMO using the femoral artery: the posterior tibial approach. *Perfusion.* 2012;27:141–5.
- 17 Chung JH, Jung JS, Son HS, Lee SH. Transient limb ischemia during extracorporeal membrane oxygenation: inappropriate venous cannula location. *Interact CardioVasc Thorac Surg.* 2015;21:694–95.
- 18 Von Segesser LK. Peripheral cannulation for cardiopulmonary bypass. MMCTS doi: 10.1510/mmcts.2005.001610
- 19 Von Segesser LK. Perfusion techniques during surgery of the thoracic and thoraco-abdominal aorta: the veno-arterial bypass. MMCTS doi: 10.1510/mmcts.2006.002535
- 20 Lehle K, Philipp A, Müller T, Schettler F, Bein T, Schmid C, Lubnow M. Flow dynamics of different adult ECMO systems: a clinical evaluation. *Artif Organs.* 2014;38(5):391–8. doi: 10.1111/aor.12180.
- 21 Shyam Prasad K, Tönz M, von Segesser LK, Leskosek B, Pei P, Turina M. re the advantages of percutaneous catheterization technique gained by increased blood trauma. *Helv Chir Acta.* 1993;60:393–6.
- 22 Straub A, Schnur W, Rehn EC, Quinz H, Oertel F, Beyer M. Erfahrungen mit der Smart Canula® zur venösen Drainage im Langzeiteinsatz. *Kardiotechnik* 2011;4:111–4. German.
- 23 Von Segesser LK, Ferrari E, Tozzi P, Abdel-Sayed S, Berdajs D. Late removal of retrievable caval filters. *Swiss Med Wkly* 2014; 144: w14022. doi: 10.4414/smw.2014.14022.
- 24 Berdajs D, Ferrari E, Michalis A, Burki M, Pieterse CW, Horisberger J, von Segesser LK. New prototype of femoral arterial Smartcanula with antegrade and retrograde flow. *Perfusion.* 2011;26:271–5.

Figures (large format)

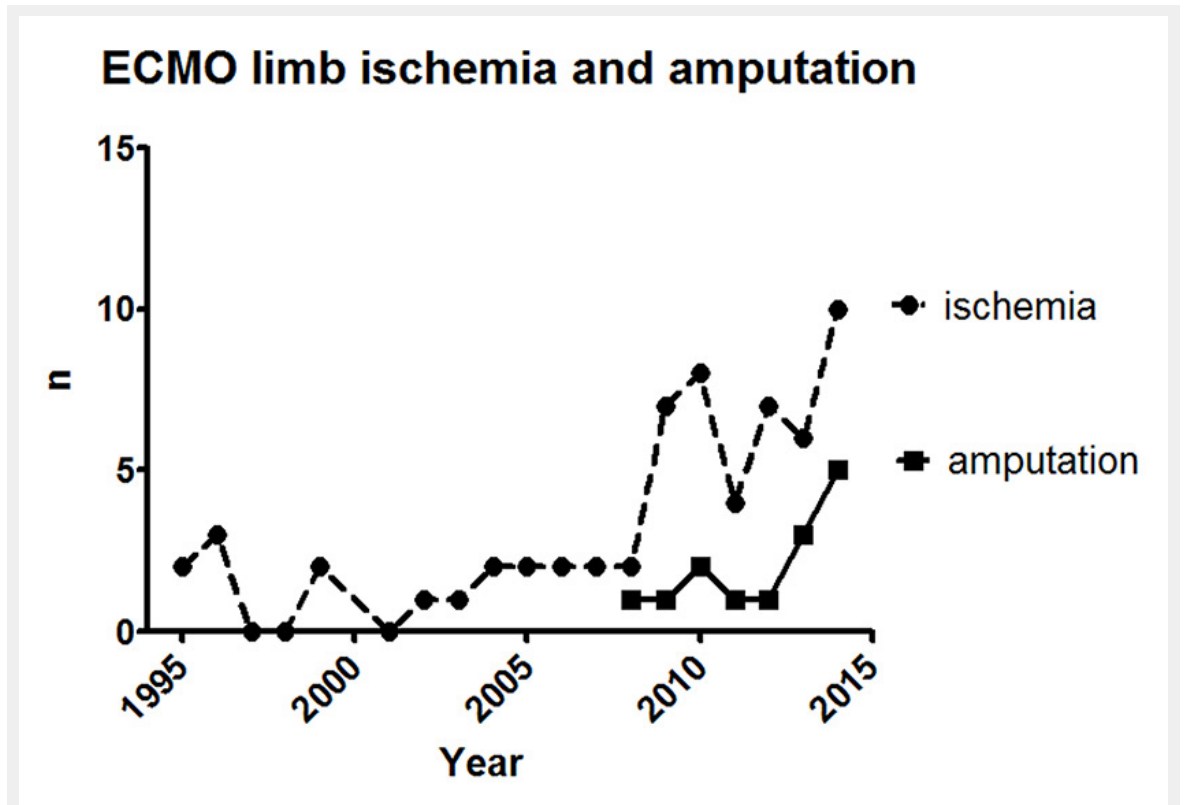


Figure 1

Number of reports on limb ischaemia and amputation in relation to extracorporeal membrane oxygenation (ECMO).

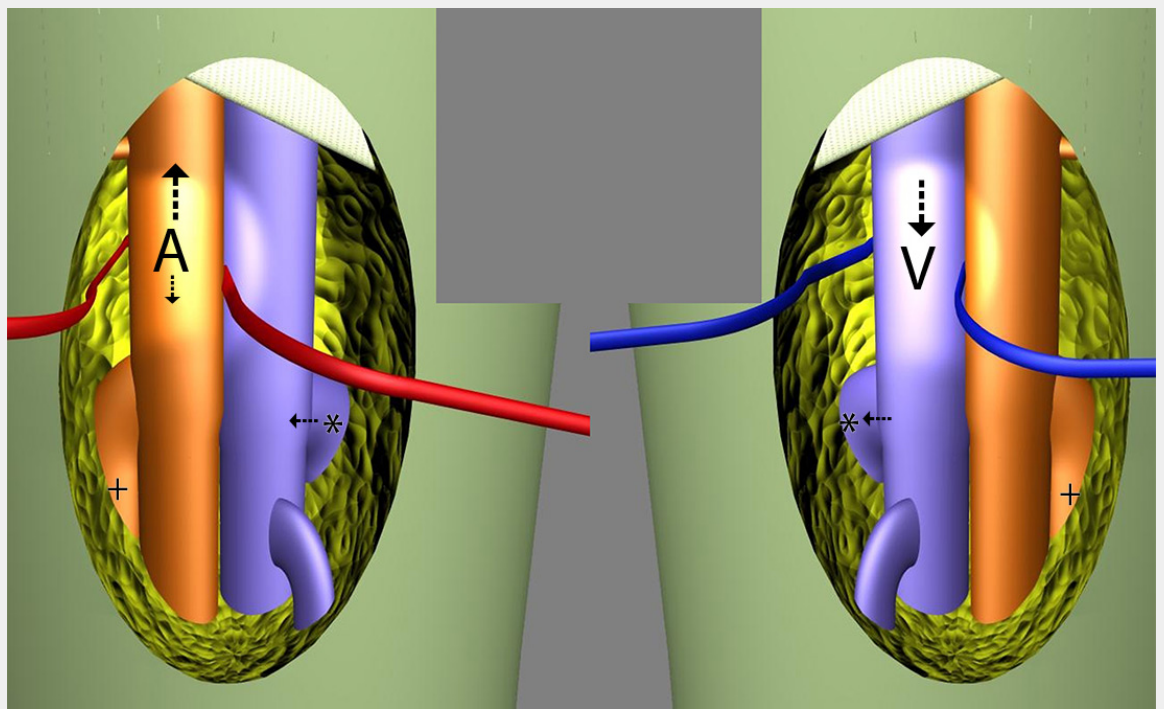


Figure 2

Schematic view of ipsilateral dual arterial cannulation and contralateral venous cannulation just caudal to the inguinal ligaments: systemic arterial cannulation (A) cephalad to the deep femoral artery (+), ipsilateral second arterial cannulation (D) for distal perfusion and contralateral venous cannulation (V) cephalad to the deep femoral vein (*). Collateral venous drainage is possible via the bilateral deep femoral veins (*) and the pelvic collaterals. The same holds true for the collateral flow via the bilateral deep femoral arteries (+). Although percutaneous cannulation on a routine basis is preferred, an open technique is displayed here for better identification of the femoral vessels and their branches.




Figure 3

Thin wall percutaneous cannula (top), collapsed virtually wall-less cannula prior to insertion (centre), and virtually wall-less cannula expanded *in situ* (bottom).

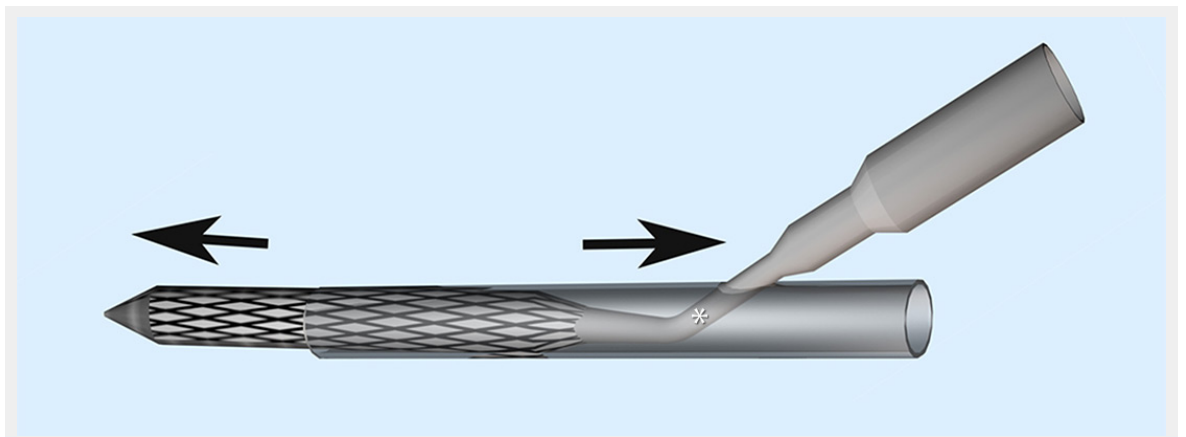


Figure 4

Schematic view of the concept for a new virtually wall-less cannula designed for bidirectional flow. The performance gain achieved with the virtually wall-less cannula design can be attributed to a short, narrower (*), somewhat less performant cannula segment at the point of insertion (centre), which allows not only for antegrade flow (left), but also for some back flow in parallel towards the limb (right).