

Transcatheter aortic valve implantation today and tomorrow

Peter Wenaweser^{a,b}, Fabien Praz^a, Stefan Stortecky^a

^a Department of Cardiology, Swiss Cardiovascular Centre, Bern University Hospital, Switzerland

^b Cardiovascular Centre Zurich, Klinik im Park, Zurich, Switzerland

Summary

Aortic stenosis is the most common valvular heart disease in Western industrial countries (including Switzerland) with a prevalence of about 5% in the population aged 75 and over. If left untreated, symptomatic patients have a rate of death of more than 50% within 2 years. As a result of age and elevated surgical risk, an important proportion of elderly patients are not referred to surgery. Thus, the introduction of transcatheter aortic valve implantation (TAVI) in 2002 has initiated a paradigm shift in the treatment of patients with symptomatic, severe aortic stenosis. The early technical and procedural success of this minimal invasive treatment in high-risk patients has promoted further innovation and development of transcatheter heart valve (THV) systems during the last 13 years. Downsizing of the delivery catheters along with technical improvements aiming to reduce postprocedural paravalvular regurgitation have resulted in a significant reduction in mortality. As a consequence, TAVI is nowadays established as safe and effective treatment for selected inoperable and high-risk patients. Ongoing studies are investigating the outcome of intermediate risk patients allocated to either surgical aortic valve replacement (SAVR) or TAVI. Despite these advancements, some specific areas of concern still require attention and need further investigations including conduction disturbances, valve degeneration and antithrombotic management.

Although the off-label use of TAVI devices in the mitral, tricuspid or pulmonary position has recently developed, important limitations still apply and careful patient selection remains crucial.

This review aims to summarise the available clinical evidence of transcatheter aortic valve treatment during the last 13 years and to provide a glimpse of future technologies.

Key words: TAVI (transcatheter aortic valve implantation); aortic stenosis; SAVR (surgical valve replacement); bioprosthesis

Aortic stenosis – prevalence, symptoms and prognosis

Aortic stenosis (AS) is the most common valvular heart disease in Western industrial countries (including Switzerland), with a prevalence of about 5% [1, 2] in the population aged 75 and over. Risk factors for the development of aortic stenosis include bicuspid anatomy (accounting for 60% of the patients <70 years of age who undergo valve replacement) and rheumatic heart disease (now rare in Western countries) along with the usual clinical factors linked to the development of atherosclerosis (positive family history, dyslipidaemia, hypertension, diabetes mellitus and smoking). In addition, patients who have undergone mediastinal radiation therapy as well as those presenting with chronic renal failure or other disorders of calcium/phosphate metabolism [3] are at increased risk of developing the disease.

Prognosis strongly depends on the presence of clinical symptoms being the most important parameter to guide decision-making. Symptomatic patients have a poor prognosis unless aortic valve replacement is performed timely [4]. Despite multiple randomised trials, no medical treatment has been found to treat symptoms effectively and to improve outcomes of affected patients [5–7]. As a consequence, risk evaluation and prompt valve replacement (either surgical or percutaneous) are the most important steps in the treatment of symptomatic patients.

Management of severe aortic stenosis – evidence for patient selection and risk stratification

Based on the initial experience and results from large observational registries and randomised trials, the European Society of Cardiology (ESC) and the American Heart Association in collaboration with the American College of Cardiology (AHA and ACC) provided practice guidelines for the treatment of symptomatic, severe aortic stenosis and the selected use of TAVI [8, 9]. Table 1 summarises the most important American and European recommendations and highlights their differences. Both guidelines recommend a collaborative decision-making process for patients

with symptomatic aortic stenosis. The input and experience from a heart team, consisting of interventional cardiologists, cardiac surgeons and other specialists help to determine the most effective treatment approach. Careful imaging of the anatomy, mostly done by echocardiography and multislice computed tomography (CT) scan, not only provides important information on the access route but also on the individual valvular anatomy, such as degree and distribution of calcification, leaflet anatomy and dimensions of the aortic valvular complex [10]. Furthermore, as the majority of patients referred for a TAVI procedure are beyond 80 years of age, a geriatric assessment to evaluate frailty and to judge upon quality-of-life improvement can be helpful [11, 12]. Although not yet validated in TAVI patients, surgical risk score algorithms (EuroScore II, STS PROM) are used for patient selection and estimation of short-term clinical outcome. A specific TAVI risk score implementing geriatric and anatomical variables is unfortunately still lacking. As a consequence, clinical experience in this new field is crucial for appropriate patient selection. Using the first generation balloon-expandable Edwards Sapien THV prosthesis, TAVI has been proven superior to

standard medical therapy (PARTNER IB) in an inoperable patient cohort (all-cause mortality at 5 years, TAVI 71.8% vs standard medical therapy 93.6%, hazard ratio [HR] 0.50, 95% confidence interval [CI] 0.39–0.65; $p < 0.0001$) [13]. Only six patients in the standard medical therapy group were alive at 5 years of follow-up, five of whom had undergone either surgical or percutaneous aortic valve replacement in the meantime. The number needed to treat amounted to five patients only in comparison to medical therapy, reflecting the efficacy of the TAVI treatment.

More importantly, TAVI has been proven to be noninferior when compared with standard SAVR. In selected high-risk patients, the risk of death was comparable between TAVI and SAVR patients (HR 1.04, 95% CI 0.86–1.24; $p = 0.76$) at 5 years [14]. More recently, the US CoreValve Pivotal trial investigated clinical outcomes in high-risk patients using the self-expanding Medtronic CoreValve system in comparison with SAVR. This trial even demonstrated superiority of TAVI for the endpoint all-cause mortality at 12 months (all-cause death 14.2% vs 19.1%, $p = 0.04$) [15] and 2 years follow-up (all-cause death 22.2% vs 28.6%, $p = 0.04$) [16]. As a consequence, high-risk patients are nowadays treated with TAVI in the event of favourable anatomical conditions. The benefit of TAVI was confirmed not only in registries [17], but also in prospective randomised trials (fig. 1). The PARTNER II trial, which investigated the performance of a new-generation device, the Edwards Sapien 3 bioprosthesis (S3i patient cohort $n = 1076$, mean STS PROM 5.3%, mean age 81.9 years), provided the lowest periprocedural mortality after TAVI (all-cause mortality 1.1%, cardiovascular mortality 0.9%) [18]. Moreover, data from real-world TAVI registries point towards an even more pronounced benefit of TAVI in a low-risk patient population (STS PROM $< 3\%$) with a cardiovascular mortality rate of 0% at 30 days after transfemoral TAVI [19]. While PARTNER II has already provided some insights into the clinical outcomes of intermediate risk patients, the SURTAVI randomised trial is still recruiting patients with comparable risk who are allocated to either TAVI with the Medtronic CoreValve or SAVR (ClinicalTrials.gov identifier: NCT01586910). Depending on the study results, an adaptation of guideline recommendations is likely.

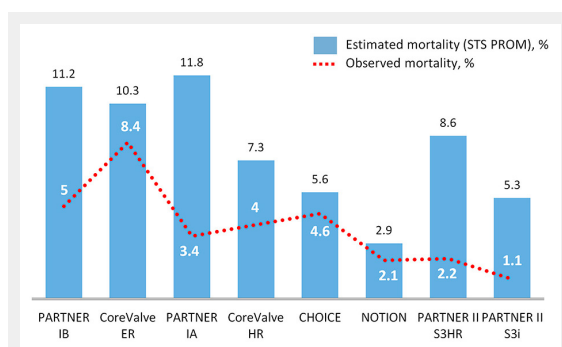


Figure 1

Estimated and observed all-cause 30-day mortality after TAVI in randomised trials and FDA approval studies. Bar graph with the estimated risk of mortality according to the STS PROM risk score and the observed risk of mortality after transcatheter aortic valve implantation at 30-day follow-up in randomised trials and large-scale FDA approval studies (ordered according to the date of publication). HR = high risk; ER = extreme risk; I = intermediate risk.

Guidelines	Class	Level	Comments
ESC/ EACTS (2012)	I	B	In the European guidelines, the indication for TAVI is entirely based on the evaluation of the heart team.
	Ila	B	
AHA/ACC (2014)	I	B	In the American guidelines the surgical risk is defined according to a new risk assessment algorithm combining STS PROM, frailty, major organ system dysfunction, and procedure-specific impediments.

ACC = American College of Cardiology; AHA = American Heart Association; EACTS = European Association for Cardio-Thoracic Surgery; ESC = European College of Cardiology; TAVI = transcatheter aortic valve implantation; TAVR = transcatheter aortic valve replacement

TAVI in 2016 – 14 years of development and experience

The success of TAVI and the ongoing decrease in periprocedural complications are based on growing operator experience and ongoing technical refinement and innovation. The procedure itself has been simplified from a complicated and demanding antegrade femoral approach via the femoral vein and transseptal puncture, to a retrograde ac-

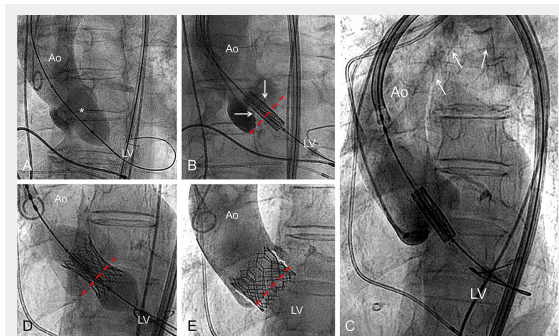


Figure 2
 Example of the different procedural steps of a standard TAVI intervention using a balloon-expandable valve. Procedural steps of a standard TAVI using a balloon-expandable transcatheter heart valve. **A:** aortic valve valvuloplasty (*) in order to facilitate valve crossing with the delivery system; **B:** positioning of the loaded bioprosthesis into the aortic annulus (red interrupted line). The arrows indicate the semi-opened valve leaflets **C:** overview of the delivery catheter introduced via the right femoral artery and crossing the aortic arch (arrows). **D:** implantation of the valve through progressive balloon inflation (the aortic annulus plane is represented by the interrupted red line); **E:** final contrast medium injection after removal of the delivery catheter excluding relevant aortic regurgitation. Schematic representation of the native valve leaflets (white lines) maintained opened by the valve stent. Ao = aorta; LV = left ventricle.

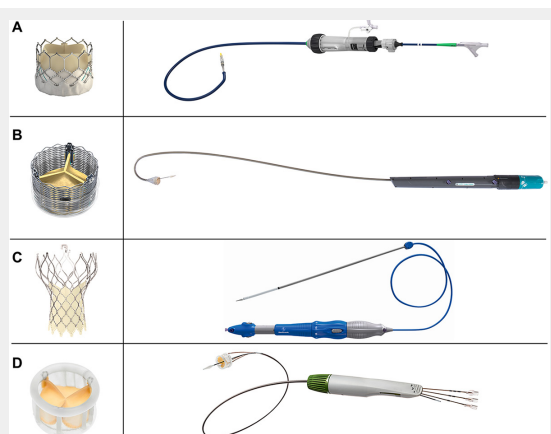


Figure 3
 Routinely used second generation devices and delivery catheters. Commonly used second-generation transcatheter aortic valve implantation devices and delivery catheters. **A:** the Edwards Sapien 3 bioprosthesis – Commander delivery catheter. The sealing skirt is designed to minimize paravalvular leakage (images courtesy of Edwards Lifesciences); **B:** the fully repositionable premounted Boston Scientific Lotus valve and its preshaped delivery catheter (images courtesy of Boston Scientific); **C:** the resheathable Evolut R valve with the EnVeo R delivery catheter and the integrated InLine Sheath (images courtesy of Medtronic); **D:** The Direct Flow valve and delivery system (images courtesy of Direct Flow Medical).

cess using the common femoral artery. In addition, alternative access routes via the left ventricular apex (transapical), the subclavian or brachial artery (transsubclavian), the carotid artery (transcarotid) or a direct aortic access (via the ascending aorta) have been introduced into clinical practice [20]. The transfemoral route is considered least invasive as the procedure can be performed using local anaesthesia and mild conscious sedation only. Currently, a transfemoral first strategy has been adopted in the vast majority of heart valve centres [21]. In more than 80% of patients the transfemoral approach is used [22] and only in the event of relevant peripheral artery disease with significant vascular calcification or tortuosity, alternative access routes are considered and evaluated. Figure 2 demonstrates the different steps of a standard TAVI procedure using a balloon-expandable transcatheter heart valve.

Since the early experience, TAVI prostheses and delivery catheters have been modified and adapted in order to reduce the risk of complications. Whereas initial TAVI procedures were performed with large-bore delivery catheters requiring peripheral vascular dimensions of 8 mm, new generation TAVI devices have been minimised and utilise a 14 and 16 French delivery sheath requiring a vessel lumen of 5–6 mm. The reduction in delivery catheter dimensions has translated into a relevant decrease of vascular access and bleeding complications, and resulted in improved clinical outcomes [23]. Changes in prosthesis design over time focused on minimising paravalvular aortic regurgitation and conduction disturbances while maintaining favourable haemodynamic properties considered superior to surgical valves. The four most frequently used CE-approved TAVI devices in Switzerland are presented in figure 3.

Medtronic CoreValve Evolut R

The Medtronic Evolut R represents the updated generation of the Medtronic CoreValve. The Evolut R prosthesis kept the key features of its predecessor with the self-expanding Nitinol stent frame and the porcine pericardial tissue valve in supra-annular position. The frame is tailored with a 10% reduction of the outflow part, while keeping the initial height of the sealing skirt to minimise paravalvular regurgitation. The bioprosthesis is integrated into a delivery sheath (14 F inner and a true 18 F outer diameter) enabling direct implantation of the valve without an additional sheath. The Evolut R is resheathable and partially repositionable if malposition occurs [24].

Edwards Sapien 3

The third generation of the Edwards Sapien bioprosthesis includes a novel and restructured cobalt chromium stent frame designed to further minimize the profile of the crimped prosthesis during valve delivery. The lower part of the stent frame is covered, like the previous Sapien XT prosthesis, but includes an additional outer sealing skirt made from polyethylene terephthalate (PET) to reduce the risk of paravalvular leakage. The Sapien 3 uses bovine pericardial tissue valve and is delivered through a 14 or 16 F expandable sheath [25]. In comparison with the previous generation a significant reduction of paravalvular leakage (more than mild aortic regurgitation 1.3% vs 5.3%, p

= 0.04) and vascular access site complications (5.3% vs 16.9%, $p < 0.01$) was observed when using the novel Sapien 3 prosthesis; however, a slightly higher rate of permanent pacemaker implantation has been noted (17.0% vs 11.0%, $p = 0.01$) [23].

Boston Scientific Lotus valve

The fully repositionable Lotus TAVI system consists of a bovine pericardial tissue valve attached to a braided nitinol frame. The Lotus system requires an 18 or 20 F delivery sheath for the 23 mm or 25 mm and 27 mm prosthesis sizes, respectively. During mechanical valve deployment, the prosthesis shortens and radially expands to accommodate fully the aortic annulus. A dedicated sealing skirt is attached to the lower part of the stent frame for minimising paravalvular aortic regurgitation. Favourable clinical and haemodynamic results have been published, so far in smaller studies. As a matter of concern, permanent pacemaker implantation was needed in up to 30% of patients [26].

Direct Flow Medical

The Direct Flow Medical (DFM) TAVI system includes a bovine pericardial valve mounted within a nonmetallic and inflatable cuff frame. The DFM prosthesis is fully repositionable and retrievable until its final delivery and is deployed in a stepwise fashion. After inflating the ventricular ring and pulling the valve into an optimal intra-annular position, the aortic ring is inflated and fixed by means of polymer filling of the rings. Safety and feasibility of this prosthesis, with less than moderate paravalvular leak in 99% of patients, was demonstrated in a small patient cohort [27]. Other TAVI systems like the "Symetris Acurate" valve, the "Portico" (SJM) valve and the "JenaValve" are regularly used.

The role of TAVI in the future

Glimpsing into the future, if innovation and progress in transcatheter heart valve techniques continue as in the last few years, TAVI will be established as primary option for the treatment of severe aortic stenosis irrespective of surgical risk scores. Maybe only patients with anatomy unsuitable for TAVI will be treated conventionally with open-heart surgery. One might remember the days of the advent of coronary stenting which was initially considered for very selected patients only, but nowadays is the primary treatment option for coronary revascularisation. Needless to say, further technical improvements in the field of TAVI are warranted and dedicated operator training is mandatory to achieve the goal of even more widespread use. TAVI can not only be performed within 30–45 minutes using local anaesthesia and conscious sedation, but also offers rapid recovery and improvement of quality of life.

The concern of residual paravalvular aortic leakage has been almost eliminated with the arrival of the Edwards Sapien 3, the Boston Scientific Lotus valve and the Medtronic Evolut R TAVI prostheses [26, 28]. More than mild paravalvular aortic regurgitation has become a rare phenomenon after TAVI, and favourable results from clinical trials can be reproduced in everyday practice and a real-world patient population with new-generation TAVI

devices [23]. The high rate of conduction disturbances requiring permanent pacemaker implantation, more frequently observed with self-expanding devices, remains a matter of concern. It is important to note that aortic valve disease, even without treatment, is associated with the risk of conduction disorders because of the anatomical proximity of the atrioventricular conduction system to the aortic annulus. Notably, observational studies did not find an association between permanent pacemaker implantation and worse clinical outcomes [29, 30].

Some other specific areas of concern have been identified and need attention for improvement of procedural and long-term clinical outcome after TAVI or SAVR

Cerebrovascular events

During the early experience with TAVI, high rates of silent ischaemic strokes were described in magnetic resonance imaging studies [31] with clinically apparent neurologic symptoms in 2.7 to 4.2% of patients [32]. The risk factors of periprocedural cerebrovascular events have been identified, were categorised into an acute, subacute and late risk period after TAVI [33], and addressed by using smaller and more flexible delivery catheters for new generation TAVI devices, cerebral protection devices [34] and a specific minimal aortic touch technique to avoid cerebral embolism. A direct comparison of TAVI with the Edwards Sapien THV and SAVR showed a comparable rate of stroke for TAVI and SAVR (11.3% vs 10.4%, HR 1.14, 95% CI 0.68–1.93, $p = 0.61$) during 5 years of follow-up [14]. In contrast however, when using the Medtronic CoreValve, a significant difference was observed during 2 years of follow-up (TAVI 10.9% vs SAVR 16.6%, $p = 0.05$) [16]. The higher rate of stroke after SAVR was explained by the higher rate of new-onset or worsening atrial fibrillation after SAVR (at 30 days 11.7% vs 30.5%), and the direct association of new-onset atrial fibrillation with worse clinical outcomes (atrial fibrillation vs no atrial fibrillation HR 1.48, 95%CI 1.12–1.96) [35].

Patient-prosthesis mismatch

The appropriate selection of the heart valve size is of particular importance, especially in the light of symptomatic improvement and also for an optimal durability of the valve. Patient-prosthesis mismatch (PPM) is diagnosed when the effective orifice area of a normally functioning prosthetic valve is too small in relation to the patient's body surface area ($\leq 0.85 \text{ cm}^2/\text{m}^2$ BSA) and represents an often-encountered problem in little old lady hearts. Persistent or recurrent symptoms and an increased risk of mortality are possible consequences. Several studies have reported on this phenomenon after SAVR (any PPM HR 1.34, 95% CI 1.18–1.51; severe PPM HR 1.84, 95% CI 1.38–2.45) [36]. In another study, PPM after SAVR affected almost two thirds of patients (incidence of 60.0%; severe PPM 28.1%), while 46.4% suffered from PPM in the TAVI group (severe PPM 19.7%, $p < 0.001$) [37]. Because of the lack of a ring, patients undergoing TAVI receive nominally larger prostheses [38], have lower mean transvalvular gradients and larger effective orifice areas after the procedure compared with patients undergoing SAVR [16]. This might positively impact on survival, especially in women [39].

Valve degeneration and endocarditis

Early valve degeneration has been rarely reported in large-scale registries during long-term follow-up after TAVI (up to 6 years), ranging between 1.4 to 4.1% [40–42]. In both PARTNER randomised trials no valve deterioration has been observed during follow-up of up to 5 years among more than 500 patients who have received a transcatheter bioprosthesis [43, 44]. The mechanisms precipitating bioprosthesis degeneration are not elucidated yet. In surgical valves, calcification due to mechanical stress, glutaraldehyde fixation, immunological reactions and generalised atherosclerosis have been identified as contributing factors [45]. Although similar mechanisms may act in transcatheter heart valve failure, specific pathophysiological factors including valve stent underexpansion or interaction with the immobilised native aortic valve leaflets may also play an important role [46], along with valve endocarditis, late embolisation, and valve thrombosis [47]. In a recent study including 7944 patients, endocarditis was rare and reported in only 0.5% of the patients 1.1 ± 1.2 years after the intervention. However, it was associated with an in-hospital mortality of nearly 50% [42]. In order to prevent haematogenous bacterial spread, standard endocarditis prophylaxis is required in TAVI patients before every dental intervention associated with manipulation of the gingival or periapical region of the teeth or perforation of the oral mucosa [48].

Subclinical leaflet thrombosis

Recently, the phenomenon of reduced aortic valve leaflet motion has been observed in different device types (including surgical bioprostheses) using four-dimensional, volume-rendered CT scans [49]. In all cases, resolution occurred either spontaneously or after initiation of oral anticoagulation. Cases of patients presenting with a clinically symptomatic valve thrombosis are rare. Currently, dual antiplatelet therapy during 6 months followed by aspirin alone indefinitely is recommended after TAVI. Against this background, it remains to be determined whether for some patients an initial treatment with a (new) oral anticoagulant is indicated in the first phase after TAVI.

Low-flow, low-gradient and paradoxical low-flow, low-gradient aortic stenosis

Many patients presenting with severe AS diagnosed on the basis of a valve area ≤ 1.0 cm², have a mean gradient < 40 mm Hg. This may be due to either left ventricular systolic dysfunction (low-flow, low-gradient; LEF-LG) [50] or a small left ventricle with preserved systolic left ventricular function resulting in diastolic dysfunction (paradoxical low-flow, low-gradient; PLF-LG) [51, 52]. In both cases, low cardiac output (stroke volume index ≤ 35 ml/m²) is present. As a consequence, many patients with PLF-LG and particularly LEF-LG have increased surgical risk. Thus, TAVI is considered an attractive alternative to SAVR for these patients. This is reflected in the most recent AHA/ACC guidelines published in 2014, which gave a class IIa recommendation for aortic valve replacement (either SAVR or TAVI) in patients with symptomatic severe (paradoxical) low-flow, low-gradient aortic stenosis [9].

Both entities present important diagnostic challenges [53]. Distinguishing between true severe and pseudo-severe AS is critical. Low dose dobutamine stress echocardiography identifies patients with increasing transvalvular flow velocity > 4 m/s under pharmacological stress and is not only useful for diagnostic purposes but also provides prognostic information by determining contractile reserve ($\geq 20\%$ increase in stroke volume) [54, 55]. In the case of discrepancy between peak stress gradient and valve area, projected effective orifice area < 1 cm² [56], as well as aortic valve calcification > 1650 AU by multislice CT [57] indicate severe AS. The presence of contractile reserve represents the most important factor influencing clinical outcome after SAVR, among LEF-LG patients [57, 58]. However, the impact of contractile reserve in LEF-LG on outcomes after TAVI as well as the post-interventional prognosis of patients presenting with paradoxical low-flow remains largely unknown.

Heart failure symptoms

The recovery period after TAVI is faster compared with SAVR in terms of symptom resolution and of restoration of health-related quality of life. Specifically, during the first year after the intervention, patients undergoing TAVI report fewer symptoms on exertion compared with patients undergoing SAVR [15, 39]. However, this beneficial effect was found after transfemoral TAVI only, and no significant differences were reported after SAVR and transapical TAVI [59].

Health resource utilisation

TAVI appears attractive from an economical point of view, as procedure duration is only half to one third that of conventional surgery [15, 38]. On the other hand, prices for TAVI bioprostheses are much higher than for surgical valves. The improvements in catheter design and size directly translate into fewer bleeding complications (life-threatening bleeding 13.6% vs 35.0%), fewer packed red blood cell transfusions (13.8% vs 61.2%), and less acute kidney injury with transient haemodialysis in TAVI patients (6.0% vs 15.1%) [15]. All these advantages impact directly on hospital length of stay and overall costs [38].

Off-label use of TAVI devices

In selected high-risk patients, transcatheter aortic valve devices are currently used for off-label indications including the treatment of aortic regurgitation, but also mitral-, tricuspid-, and pulmonary valve pathologies. Figure 4 provides an illustrated collection of off-label indications for TAVI devices.

1. The use of conventional TAVI devices for the treatment of pure aortic valve regurgitation is impaired by the lack of annular calcification and the subsequent risk of insufficient anchoring of the implanted bioprosthesis. As a consequence, SAVR remains the standard treatment for operable patients. In patients at prohibitive risk, TAVI can be considered a possible alternative after careful anatomical assessment. Owing to additional abutment against the wall of the ascending aorta, the Medtronic CoreValve bioprosthesis has been mainly

used for this indication in the past. Compared with conventional TAVI, transcatheter treatment of pure aortic regurgitation is associated with lower device success (74.4%; mainly due to device embolisation), higher rate of moderate to severe postinterventional aortic regurgitation (21%) and an increased all-cause mortality (21.4%) at 12 months [60]. These results support the development of dedicated devices.

- Mitral valve-in-valve (fig. 4A) and valve-in-ring (fig. 4B) interventions using either the transapical or the less invasive transfemoral/transseptal access have been proven to be effective in reducing mitral regurgitation or treating mitral stenosis and is associated with low rates of complications [61, 62]. However, multimodal evaluation of the prosthesis/ring type and size using transoesophageal echocardiography and CT scan is mandatory as not all valve/ring models are amenable to transcatheter therapy. Furthermore, the risk of left ventricular outflow tract obstruction due to displacement of the mitral valve leaflets needs to be carefully evaluated. Appropriate medical therapy including oral anticoagulation for at least 3 months is recommended for the prevention of valve thrombosis.

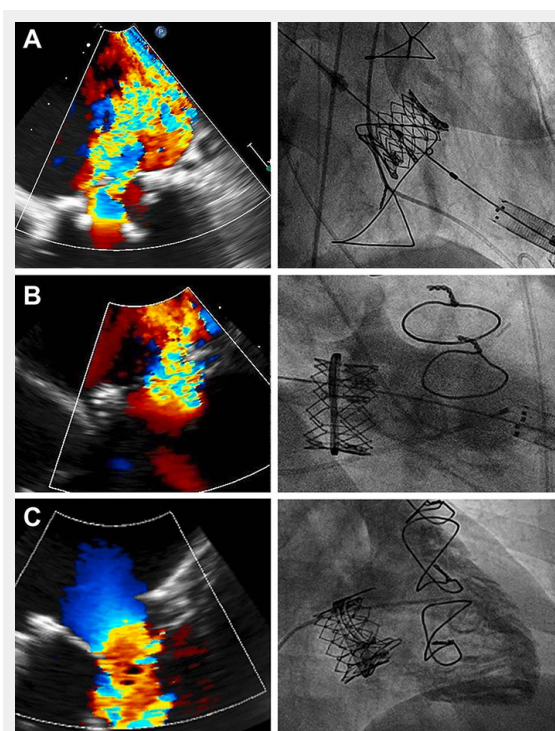


Figure 4

Examples of off-label use of TAVI devices.

Selected examples of off-label use of transcatheter aortic valve implantation devices. **A:** valve-in-valve implantation (29 mm Edwards Sapien XT) for treatment of severe mitral regurgitation in a 88-year-old male 12 years after surgical mitral valve replacement (Medtronic Mosaic 33 mm); **B:** valve-in-ring implantation (26 mm Edwards Sapien XT) for treatment of recurrent severe mitral regurgitation in a 83-year-old female patient 3 years after mitral valve repair with a semi-rigid 30 mm Edwards Physio II ring; **C:** transfemoral tricuspid valve-in-valve implantation in a young women (41 years old) known for Ebstein anomaly and presenting with severe symptomatic tricuspid stenosis due to leaflet fusion 6 years after surgical tricuspid valve replacement (Edwards Perimount Magna 33 mm).

- Although rarely performed, tricuspid valve-in-valve procedures (fig. 4C) may emerge as an attractive treatment option in inoperable patients as well as bridge therapy in young Ebstein patients who have previously undergone open-heart surgery [63]. In contrast, tricuspid valve-in-ring interventions are limited by the rigid design of tricuspid rings associated with high risk of persisting paravalvular regurgitation after valve implantation [64].
- Even if the Melody valve is still the preferred transcatheter bioprosthesis for percutaneous pulmonary valve implantation, the Edwards Sapien valve has been successfully used in the pulmonary position, especially in patients with large anatomy or for valve-in-valve interventions [65].

In summary, TAVI is established as an effective and safe treatment option for elderly patients with severe symptomatic aortic stenosis. Technological progress will most probably allow the use of TAVI in a broader patient population. Further technological developments, a dedicated TAVI risk score and high levels of operator experience are mandatory to further improve clinical outcomes.

Funding / potential competing interests: PW: Proctoring, lecture fees from Medtronic, Edwards, Boston Scientific Institutional grant from Medtronic.

Correspondence: Peter Wenaweser, MD, Department of Cardiology, Bern University Hospital, CH-3010 Bern, [peter.wenaweser\[at\]insel.ch](mailto:peter.wenaweser[at]insel.ch)

References

- Lindroos M, Kupari M, Heikkilä J, Tilvis R. Prevalence of aortic valve abnormalities in the elderly: an echocardiographic study of a random population sample. *J Am Coll Cardiol.* 1993;21:1220–5.
- Nkomo VT, Gardin JM, Skelton TN, Gottdiener JS, Scott CG, Enriquez-Sarano M. Burden of valvular heart diseases: a population-based study. *Lancet.* 2006;368:1005–11.
- Linefsky JP, O'Brien KD, Katz R, et al. Association of serum phosphate levels with aortic valve sclerosis and annular calcification: the cardiovascular health study. *J Am Coll Cardiol.* 2011;58:291–7.
- Ross J, Jr., Braunwald E. Aortic stenosis. *Circulation.* 1968;38:61–7.
- Teo KK, Corsi DJ, Tam JW, Dumesnil JG, Chan KL. Lipid lowering on progression of mild to moderate aortic stenosis: meta-analysis of the randomized placebo-controlled clinical trials on 2344 patients. *Can J Cardiol.* 2011;27:800–8.
- Chan KL, Teo K, Dumesnil JG, Ni A, Tam J, Investigators A. Effect of lipid lowering with rosuvastatin on progression of aortic stenosis: results of the aortic stenosis progression observation: measuring effects of rosuvastatin (ASTRONOMER) trial. *Circulation.* 2010;121:306–14.
- Rossebo AB, Pedersen TR, Boman K, et al. Intensive lipid lowering with simvastatin and ezetimibe in aortic stenosis. *N Engl J Med.* 2008;359:1343–56.
- Joint Task Force on the Management of Valvular Heart Disease of the European Society of C, European Association for Cardio-Thoracic S, Vahanian A et al. Guidelines on the management of valvular heart disease (version 2012). *Eur Heart J.* 2012;33:2451–96.
- Nishimura RA, Otto CM, Bonow RO, et al. 2014 AHA/ACC guideline for the management of patients with valvular heart disease: executive summary: a report of the American College of Cardiology/American Heart Association Task Force on Practice Guidelines. *J Am Coll Cardiol.* 2014;63:2438–88.

- 10 O'Sullivan CJ, Stortecky S, Buellesfeld L, Wenaweser P, Windecker S. Preinterventional screening of the TAVI patient: how to choose the suitable patient and the best procedure. *Clinical research in cardiology: official journal of the German Cardiac Society*. 2014;103:259–74.
- 11 Stortecky S, Schoenenberger AW, Moser A, et al. Evaluation of multidimensional geriatric assessment as a predictor of mortality and cardiovascular events after transcatheter aortic valve implantation. *JACC Cardiovasc Interv*. 2012;5:489–96.
- 12 Schoenenberger AW, Stortecky S, Neumann S, et al. Predictors of functional decline in elderly patients undergoing transcatheter aortic valve implantation (TAVI). *Eur Heart J*. 2013;34:684–92.
- 13 Kapadia SR, Leon MB, Makkar RR, et al. 5-year outcomes of transcatheter aortic valve replacement compared with standard treatment for patients with inoperable aortic stenosis (PARTNER 1): a randomised controlled trial. *Lancet*. 2015;385:2485–91.
- 14 Mack MJ, Leon MB, Smith CR, et al. 5-year outcomes of transcatheter aortic valve replacement or surgical aortic valve replacement for high surgical risk patients with aortic stenosis (PARTNER 1): a randomised controlled trial. *Lancet*. 2015;385:2477–84.
- 15 Adams DH, Popma JJ, Reardon MJ, et al. Transcatheter aortic-valve replacement with a self-expanding prosthesis. *N Engl J Med*. 2014;370:1790–8.
- 16 Reardon MJ, Adams DH, Kleiman NS, et al. 2-Year Outcomes in Patients Undergoing Surgical or Self-Expanding Transcatheter Aortic Valve Replacement. *J Am Coll Cardiol*. 2015;66:113–21.
- 17 Pilgrim T, Englberger L, Rothenbuhler M, et al. Long-term outcome of elderly patients with severe aortic stenosis as a function of treatment modality. *Heart*. 2015;101:30–6.
- 18 Investigators KSoboTPT. Clinical and Echocardiographic Outcomes at 30 Days with the Sapien 3 TAVR System in inoperable, high-risk and intermediate risk AS patients. Presented at ACC 2015 in San Diego 2015.
- 19 Wenaweser P, Stortecky S, Schwander S, et al. Clinical outcomes of patients with estimated low or intermediate surgical risk undergoing transcatheter aortic valve implantation. *Eur Heart J*. 2013;34:1894–905.
- 20 Stortecky S, Buellesfeld L, Wenaweser P, Windecker S. Transcatheter aortic valve implantation: prevention and management of complications. *Heart*. 2012;98(Suppl 4):iv52–64.
- 21 Wenaweser P, Stortecky S, Heg D, et al. Short-term clinical outcomes among patients undergoing transcatheter aortic valve implantation in Switzerland: the Swiss TAVI registry. *EuroIntervention: journal of EuroPCR in collaboration with the Working Group on Interventional Cardiology of the European Society of Cardiology*. 2014;10:982–9.
- 22 Gilard M, Eltchaninoff H, Jung B, et al. Registry of transcatheter aortic-valve implantation in high-risk patients. *N Engl J Med*. 2012;366:1705–15.
- 23 Binder RK, Stortecky S, Heg D, Tueller D, Jeger R, Toggweiler S, et al. Procedural Results and Clinical Outcomes of Transcatheter Aortic Valve Implantation in Switzerland: An Observational Cohort Study of Sapien 3 Versus Sapien XT Transcatheter Heart Valves. *Circ Cardiovasc Interv*. 2015;8. pii: e002653.
- 24 Piazza N, Martucci G, Lachapelle K, et al. First-in-human experience with the Medtronic CoreValve Evolut R. *EuroIntervention*. 2014;9:1260–3.
- 25 Binder RK, Rodes-Cabau J, Wood DA, Webb JG. Edwards SAPIEN 3 valve. *EuroIntervention*. 2012;8(Suppl Q):Q83–7.
- 26 Meredith AM IT, Walters DL, Dumonteil N, et al. Transcatheter aortic valve replacement for severe symptomatic aortic stenosis using a repositionable valve system: 30-day primary endpoint results from the REPRIZE II study. *J Am Coll Cardiol*. 2014;64:1339–48.
- 27 Schofer J, Colombo A, Klugmann S, et al. Prospective multicenter evaluation of the direct flow medical transcatheter aortic valve. *J Am Coll Cardiol*. 2014;63:763–8.
- 28 Webb J, Gerosa G, Lefevre T, et al. Multicenter evaluation of a next-generation balloon-expandable transcatheter aortic valve. *J Am Coll Cardiol*. 2014;64:2235–43.
- 29 Buellesfeld L, Stortecky S, Heg D, et al. Impact of permanent pacemaker implantation on clinical outcome among patients undergoing transcatheter aortic valve implantation. *J Am Coll Cardiol*. 2012;60:493–501.
- 30 Linke A, Wenaweser P, Gerckens U, et al. Treatment of aortic stenosis with a self-expanding transcatheter valve: the International Multi-centre ADVANCE Study. *Eur Heart J*. 2014;35:2672–84.
- 31 Kahlert P, Al-Rashid F, Dotterger P, et al. Cerebral embolization during transcatheter aortic valve implantation: a transcranial Doppler study. *Circulation*. 2012;126:1245–55.
- 32 Eggebrecht H, Schmermund A, Voigtlander T, Kahlert P, Erbel R, Mehta RH. Risk of stroke after transcatheter aortic valve implantation (TAVI): a meta-analysis of 10,037 published patients. *EuroIntervention*. 2012;8:129–38.
- 33 Stortecky S, Windecker S. Stroke: an infrequent but devastating complication in cardiovascular interventions. *Circulation*. 2012;126:2921–4.
- 34 Praz F, Nietlispach F. Cerebral protection devices for transcatheter aortic valve implantation: is better the enemy of good? *EuroIntervention*. 2013;9(Suppl):S124–8.
- 35 Filardo G, Hamilton C, Hamman B, Hebel RF, Jr., Adams J, Grayburn P. New-onset postoperative atrial fibrillation and long-term survival after aortic valve replacement surgery. *Ann Thoracic Surg*. 2010;90:474–9.
- 36 Head SJ, Mokhles MM, Osnabrugge RL, et al. The impact of prosthesis-patient mismatch on long-term survival after aortic valve replacement: a systematic review and meta-analysis of 34 observational studies comprising 27 186 patients with 133 141 patient-years. *Eur Heart J*. 2012;33:1518–29.
- 37 Pibarot P, Weissman NJ, Stewart WJ, et al. Incidence and sequelae of prosthesis-patient mismatch in transcatheter versus surgical valve replacement in high-risk patients with severe aortic stenosis: a PARTNER trial cohort – a analysis. *J Am Coll Cardiol*. 2014;64:1323–34.
- 38 Eggebrecht H, Mehta RH. Transcatheter aortic valve implantation (TAVI) in Germany 2008–2014: on its way to standard therapy for aortic valve stenosis in the elderly? *EuroIntervention*. 2015;11.
- 39 Smith CR, Leon MB, Mack MJ, et al. Transcatheter versus surgical aortic-valve replacement in high-risk patients. *N Engl J Med*. 2011;364:2187–98.
- 40 Toggweiler S, Humphries KH, Lee M, et al. 5-year outcome after transcatheter aortic valve implantation. *J Am Coll Cardiol*. 2013;61:413–9.
- 41 Bouleti C, Himbert D, Jung B, et al. Long-term outcome after transcatheter aortic valve implantation. *Heart*. 2015;101:936–42.
- 42 Amat-Santos IJ, Messika-Zeitoun D, Eltchaninoff H, et al. Infective endocarditis after transcatheter aortic valve implantation: results from a large multicenter registry. *Circulation*. 2015;131:1566–74.
- 43 Kapadia SR, Leon MB, Makkar RR, et al. 5-year outcomes of transcatheter aortic valve replacement compared with standard treatment for patients with inoperable aortic stenosis (PARTNER 1): a randomised controlled trial. *Lancet*. 2015.
- 44 Mack MJ, Leon MB, Smith CR, et al. 5-year outcomes of transcatheter aortic valve replacement or surgical aortic valve replacement for high surgical risk patients with aortic stenosis (PARTNER 1): a randomised controlled trial. *Lancet*. 2015.
- 45 Pibarot P, Dumesnil JG. Prosthetic heart valves: selection of the optimal prosthesis and long-term management. *Circulation*. 2009;119:1034–48.
- 46 Deutsch MA, Mayr NP, Assmann G, et al. Structural valve deterioration 4 years after transcatheter aortic valve replacement: imaging and pathological findings. *Circulation*. 2015;131:682–5.
- 47 Mylotte D, Andalib A, Theriault-Lauzier P, et al. Transcatheter heart valve failure: a systematic review. *Eur Heart J*. 2015;36:1306–27.
- 48 Authors/Task Force M, Habib G, Lancellotti P, et al. 2015 ESC Guidelines for the management of infective endocarditis: The Task Force for the Management of Infective Endocarditis of the European Society of Cardiology (ESC) Endorsed by: European Association of Cardio-Thoracic Surgery (EACTS), the European Association of Nuclear Medicine (EANM). *Eur Heart J*. 2015;36:3075–128.
- 49 Makkar RR, Fontana G, Jiliahawi H, et al. Possible Subclinical Leaflet Thrombosis in Bioprosthetic Aortic Valves. *N Engl J Med*. 2015.
- 50 Chambers J. Low “gradient”, low flow aortic stenosis. *Heart*. 2006;92:554–8.

- 51 Hachicha Z, Dumesnil JG, Bogaty P, Pibarot P. Paradoxical low-flow, low-gradient severe aortic stenosis despite preserved ejection fraction is associated with higher afterload and reduced survival. *Circulation*. 2007;115:2856–64.
- 52 Dumesnil JG, Pibarot P, Carabello B. Paradoxical low flow and/or low gradient severe aortic stenosis despite preserved left ventricular ejection fraction: implications for diagnosis and treatment. *Eur Heart J*. 2010;31:281–9.
- 53 O'Sullivan CJ, Praz F, Stortecky S, Windecker S, Wenaweser P. Assessment of low-flow, low-gradient, severe aortic stenosis: an invasive evaluation is required for decision making. *EuroIntervention*. 2014;10(Suppl U):U61–8.
- 54 Monin JL, Quere JP, Monchi M, et al. Low-gradient aortic stenosis: operative risk stratification and predictors for long-term outcome: a multicenter study using dobutamine stress hemodynamics. *Circulation*. 2003;108:319–24.
- 55 Clavel MA, Ennezat PV, Marechaux S, et al. Stress echocardiography to assess stenosis severity and predict outcome in patients with paradoxical low-flow, low-gradient aortic stenosis and preserved LVEF. *JACC Cardiovas Imaging*. 2013;6:175–83.
- 56 Clavel MA, Burwash IG, Mundigler G, et al. Validation of conventional and simplified methods to calculate projected valve area at normal flow rate in patients with low flow, low gradient aortic stenosis: the multicenter TOPAS (True or Pseudo Severe Aortic Stenosis) study. *J Am Soc Echocardiogr*. 2010;23:380–6.
- 57 Cuffe C, Serfaty JM, Cimadevilla C, et al. Measurement of aortic valve calcification using multislice computed tomography: correlation with haemodynamic severity of aortic stenosis and clinical implication for patients with low ejection fraction. *Heart*. 2011;97:721–6.
- 58 Quere JP, Monin JL, Levy F, et al. Influence of preoperative left ventricular contractile reserve on postoperative ejection fraction in low-gradient aortic stenosis. *Circulation*. 2006;113:1738–44.
- 59 Reynolds MR, Magnuson EA, Lei Y, et al. Cost-effectiveness of transcatheter aortic valve replacement compared with surgical aortic valve replacement in high-risk patients with severe aortic stenosis: results of the PARTNER (Placement of Aortic Transcatheter Valves) trial (Cohort A). *J Am Coll Cardiol*. 2012;60:2683–92.
- 60 Mylotte D, Lefevre T, Sondergaard L, et al. Transcatheter aortic valve replacement in bicuspid aortic valve disease. *J Am Coll Cardiol*. 2014;64:2330–9.
- 61 Cheung A, Webb JG, Barbanti M, et al. 5-year experience with transcatheter transapical mitral valve-in-valve implantation for bioprosthetic valve dysfunction. *J Am Coll Cardiol*. 2013;61:1759–66.
- 62 Bouleti C, Fassa AA, Himbert D, et al. Transfemoral implantation of transcatheter heart valves after deterioration of mitral bioprosthesis or previous ring annuloplasty. *JACC Cardiovasc Interv*. 2015;8:83–91.
- 63 Schwitz F WP, Kadner A, Wustmann K, Windecker S, Schwerzmann M. A valve-in-valve approach for Ebstein's anomaly. *Cardiovasc Med*. 2014;18:139–41.
- 64 Bouleti C, Himbert D, Brochet E et al. Transfemoral tricuspid valve-in-ring implantation using the Edwards Sapien XT valve: one-year follow-up. *Circ Cardiovasc Interv*. 2015;8.
- 65 Kenny D, Hijazi ZM, Kar S, et al. Percutaneous implantation of the Edwards SAPIEN transcatheter heart valve for conduit failure in the pulmonary position: early phase 1 results from an international multicenter clinical trial. *J Am Coll Cardiol*. 2011;58:2248–56.

Figures (large format)

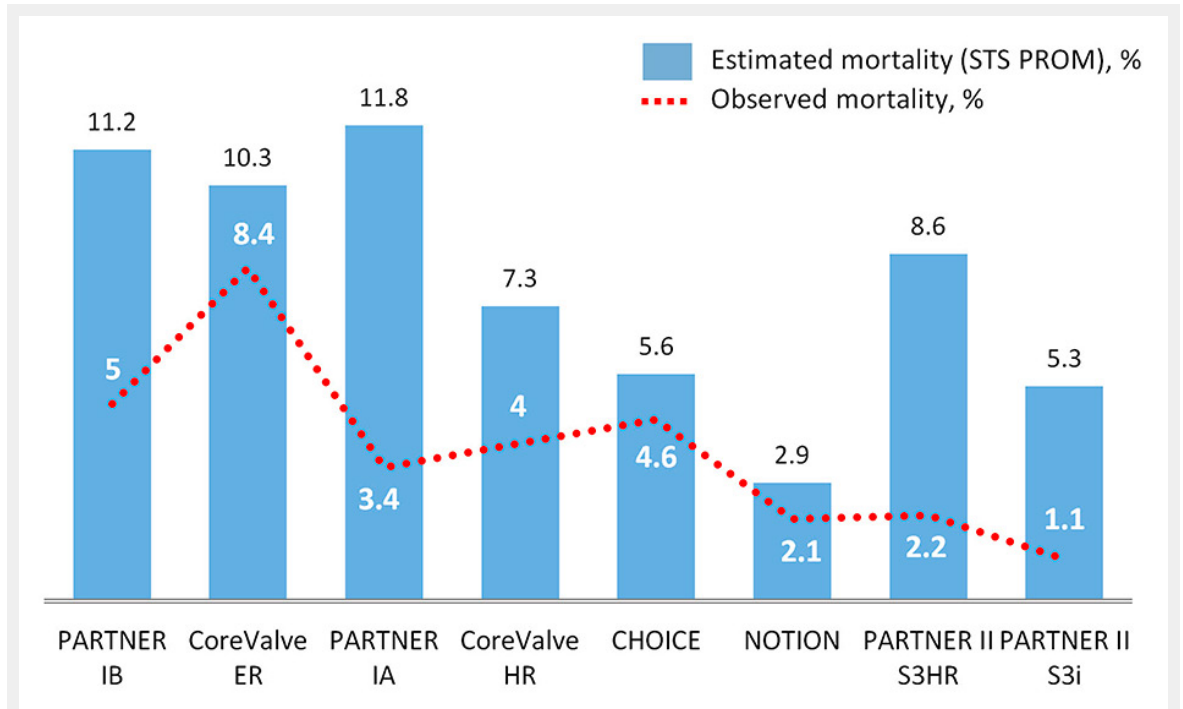


Figure 1

Estimated and observed all-cause 30-day mortality after TAVI in randomised trials and FDA approval studies (ordered according to the date of publication).

Bar graph with the estimated risk of mortality according to the STS PROM risk score and the observed risk of mortality after transcatheter aortic valve implantation at 30-day follow-up in randomised trials and large-scale FDA approval studies.

HR = high risk; ER = extreme risk; I = intermediate risk.

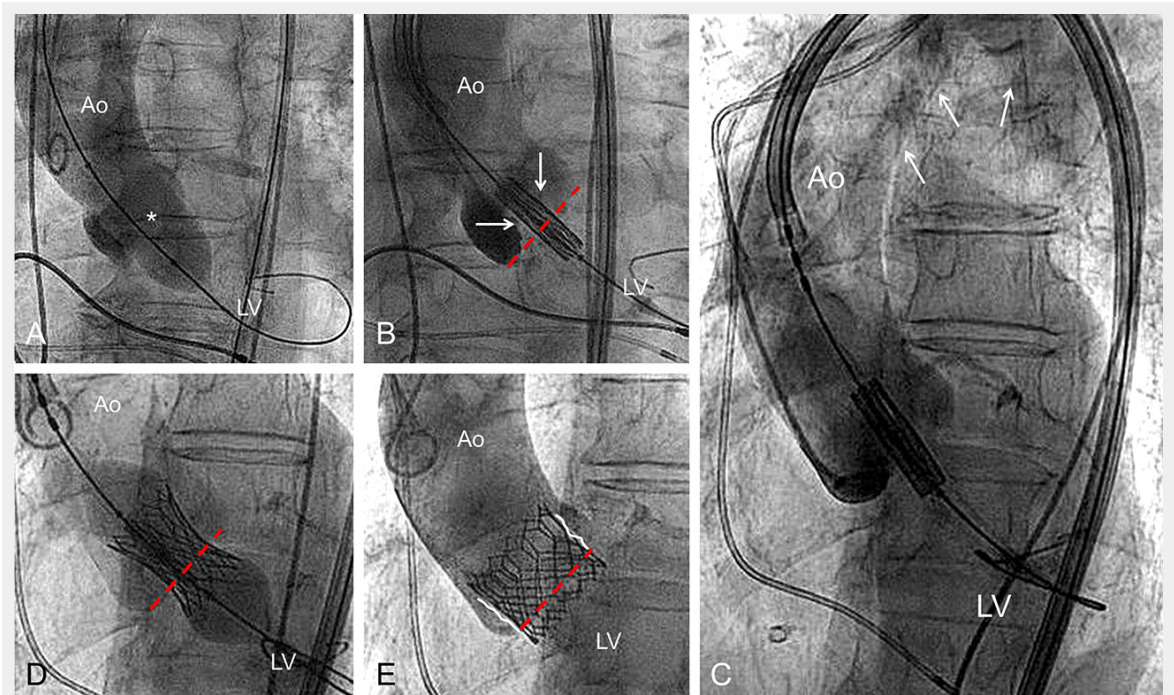


Figure 2

Example of the different procedural steps of a standard TAVI intervention using a balloon-expandable valve.

Procedural steps of a standard TAVI using a balloon-expandable transcatheter heart valve. **A:** aortic valve valvuloplasty (*) in order to facilitate valve crossing with the delivery system; **B:** positioning of the loaded bioprosthesis into the aortic annulus (red interrupted line). The arrows indicate the semi-opened valve leaflets **C:** overview of the delivery catheter introduced via the right femoral artery and crossing the aortic arch (arrows); **D:** implantation of the valve through progressive balloon inflation (the aortic annulus plane is represented by the interrupted red line); **E:** final contrast medium injection after removal of the delivery catheter excluding relevant aortic regurgitation. Schematic representation of the native valve leaflets (white lines) maintained opened by the valve stent. Ao = aorta; LV = left ventricle.

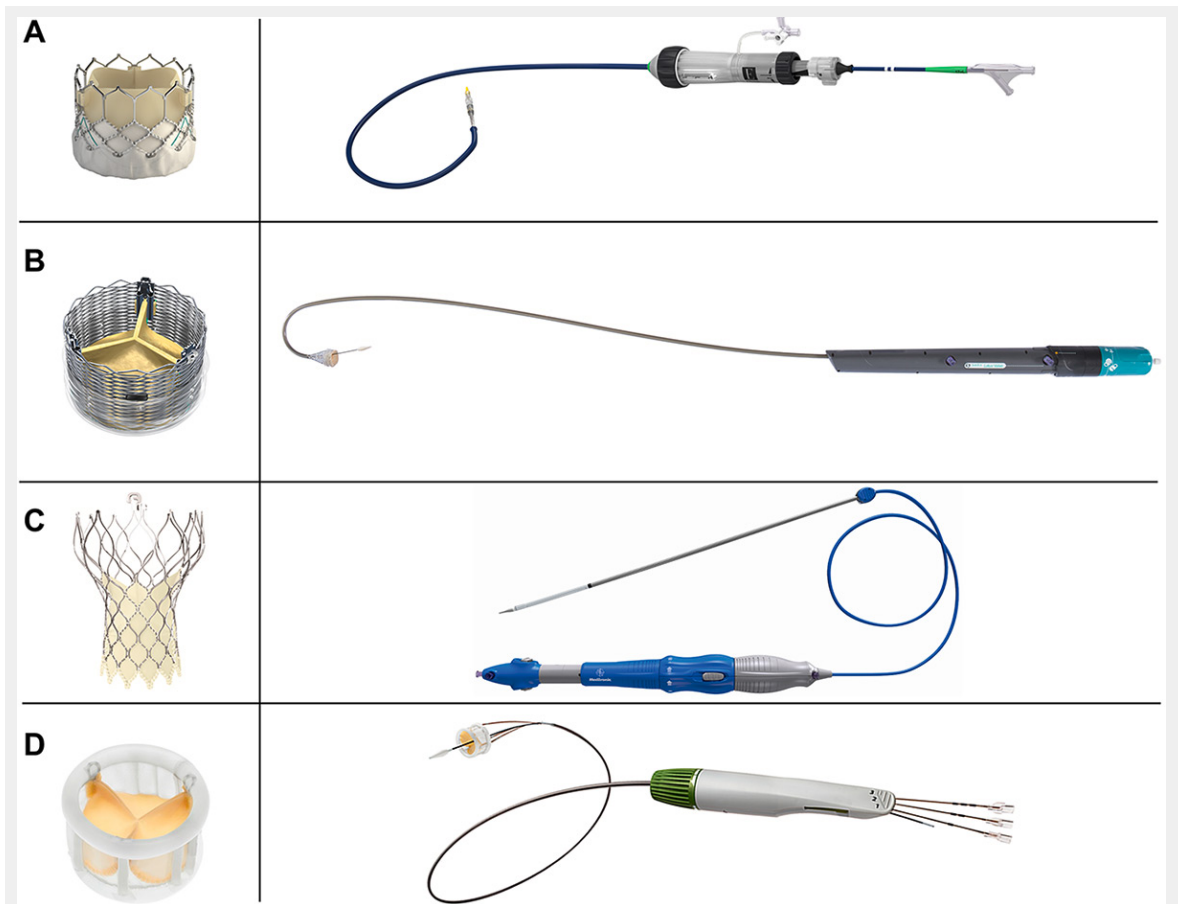


Figure 3

Routinely used second generation devices and delivery catheters.

Commonly used second-generation transcatheter aortic valve implantation devices and delivery catheters. **A:** the Edwards Sapien 3 bioprosthesis – Commander delivery catheter. The sealing skirt is designed to minimise paravalvular leakage (images courtesy of Edwards Lifesciences); **B:** the fully repositionable premounted Boston Scientific Lotus valve and its preshaped delivery catheter (images courtesy of Boston Scientific); **C:** the resheathable Evolut R valve with the EnVeo R delivery catheter and the integrated InLine Sheath (images courtesy of Medtronic); **D:** The Direct Flow valve and delivery system (images courtesy of Direct Flow Medical).

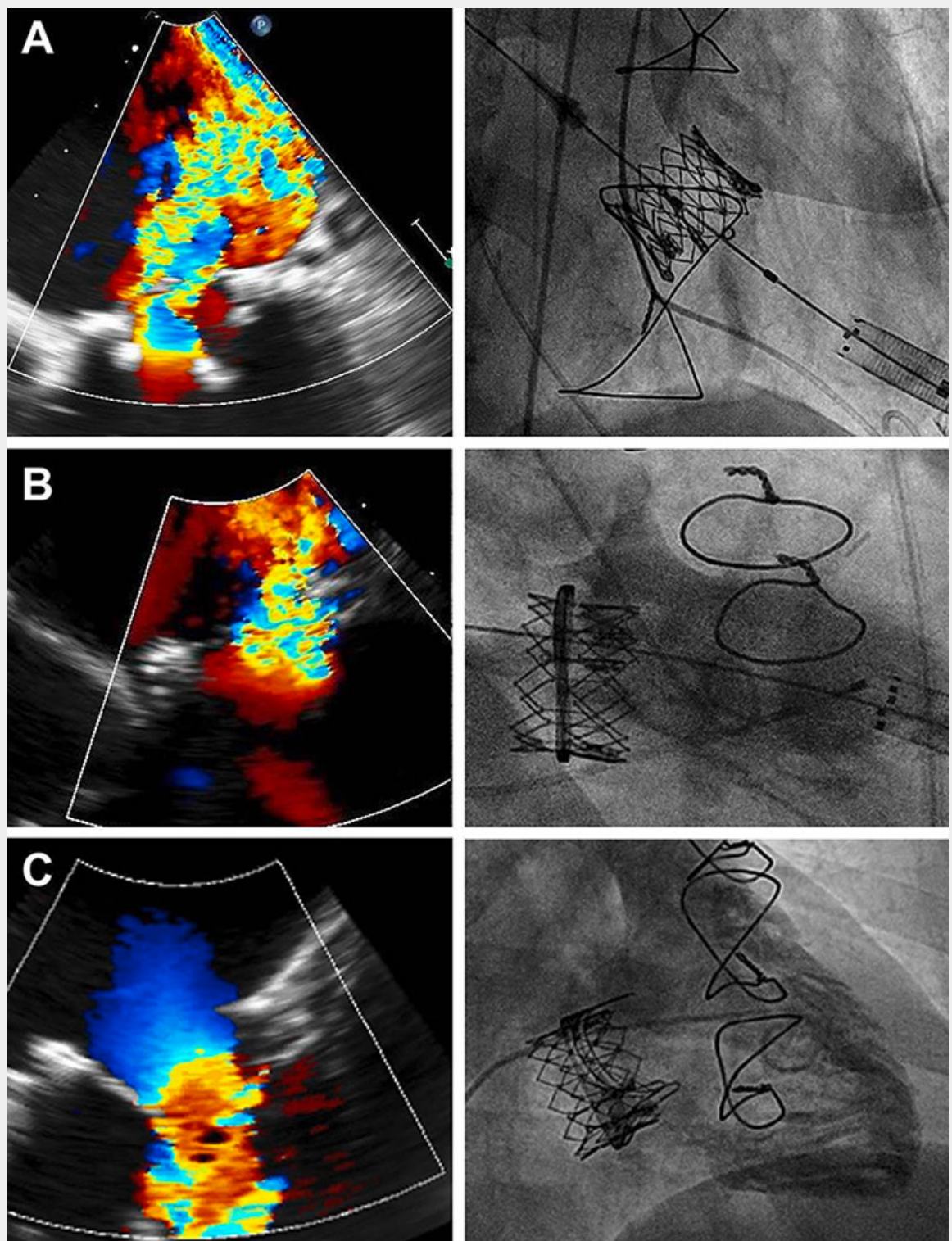


Figure 4

Examples of off-label use of TAVI devices.

Selected examples of off-label use of transcatheter aortic valve implantation devices. **A:** valve-in-valve implantation (29 mm Edwards Sapien XT) for treatment of severe mitral regurgitation in a 88-year-old male 12 years after surgical mitral valve replacement (Medtronic Mosaic 33 mm); **B:** valve-in-ring implantation (26 mm Edwards Sapien XT) for treatment of recurrent severe mitral regurgitation in a 83-year-old female patient 3 years after mitral valve repair with a semi-rigid 30 mm Edwards Physio II ring; **C:** transfemoral tricuspid valve-in-valve implantation in a young women (41 years old) known for Ebstein anomaly and presenting with severe symptomatic tricuspid stenosis due to leaflet fusion 6 years after surgical tricuspid valve replacement (Edwards Perimount Magna 33 mm).