

# Non-alcoholic fatty liver disease: treatment options based on pathogenic considerations

Carl M. Oneto, Jean-François Dufour

Division of Gastroenterology, University Hospital of Bern (Inselspital) and Department of Clinical Pharmacology, University of Bern, Bern, Switzerland

## Summary

NASH is a frequent liver disease that develops in close association with IR and may progress to cirrhosis. Exclusion of excessive alcohol consumption as well as of other liver diseases and liver histology are required for diagnosis. Progress in the understanding of the pathophysiology of NASH allows interesting therapeutic considerations. It is

logical to treat the associated metabolic conditions to influence the disease activity and progression. In view of promising preliminary data, several drugs are currently used in clinical trials.

*Key words:* fatty liver; NASH; non-alcoholic steatohepatitis; pathogenesis; review; treatment

## Introduction

The term “non-alcoholic fatty liver disease” (NAFLD) is used to describe a wide spectrum of fatty liver changes ranging from steatosis on one side and non-alcoholic steatohepatitis (NASH) on the other. Liver steatosis is a benign, non-progressive condition, in contrast to NASH, which can progress to liver fibrosis and cirrhosis. These two entities are clinically and radiologically indistinguishable and, at present, there is no sensitive non-invasive test to differentiate between them. A liver biopsy is therefore necessary to reach the exact diagnosis and to obtain hereby prognostic information [1–3]. NASH was described twenty two

years ago by a pathologist, J. Ludwig [4]. He found lesions of alcoholic steatohepatitis (ASH) in patients who had no history of regular alcohol consumption and did not suffer from other liver diseases. NASH is becoming a frequent liver disease and probably carries a similar risk of progression to cirrhosis as chronic hepatitis C. No treatment has yet proven its efficacy. Pathogenic mechanisms are the mainstay for therapeutic considerations. This review has two purposes, firstly to draw attention to this still under-recognized disease and secondly to focus on therapeutic options based on present knowledge of pathogenesis.

## Historical perspectives and prevalence

In the 1970s, “fatty liver hepatitis” (Ludwig et al. coined the name of non-alcoholic steatohepatitis (NASH) in 1980 [4]), was thought to affect

mostly morbidly obese patients who had had a jejunioileal bypass [5–7]. One third of these patients developed fibrosis [8] and several needed liver

### Abbreviations

CTGF	Connective tissue growth factor
CYP2E1	Cytochrome P450 2E1
FFAs	Free fatty acids
HSC	Hepatic stellate cell
IR	Insulin resistance
IL-6	Interleukin-6
KC	Kupffer cell

NAFLD	Non-alcoholic fatty liver disease
NASH	Non-alcoholic steatohepatitis
PPAR $\gamma$	Peroxisome-proliferator-activated receptor gamma
TZDs	Thiazolidinediones
TGF1 $\beta$	Transforming growth factor beta-1
TNF $\alpha$	Tumour necrosis factor alpha
UDCA	Ursodeoxycholic acid
VLDV	Very low density lipoproteins

transplantation after correction of the digestive anatomy [9–11]. Concerning the pathomechanism of liver fibrosis in these patients, it can be hypothesised that their fatty livers were simultaneously exposed to two important pathogenic factors; to free fatty acids (from the adipose tissue) on the one hand, and to lipopolysaccharides (from the excluded bowel) on the other. Later, histopathological features of NASH were described in patients taking drugs like 4,4'-diethylaminoethoxyhexestrol (DEAEH) [12], perhexiline-maleate [13], steroids [14], amiodarone [15] and isoniazid [16]. Another drug associated with NASH is tamoxifen [17]. About one third of 105 breast cancer patients developed radiological signs suggestive of hepatic steatosis within the first two years of treatment. In

7 out of 21 patients with increased transaminase levels liver biopsies were performed. 6 biopsies revealed NASH. In the 1990s, the entity was expanded by the recognition of the differential diagnostic importance of NASH in patients with abnormal liver enzymes [18]. Since then, NASH has emerged as one of the most frequent liver diseases in the Western world [19]. Although its exact prevalence in the general population has not yet been defined, it is estimated to be about 3% to 4% [20]. Autopsy data indicate that NASH is at least six times more prevalent in obese compared with lean individuals [21]. Most cases occur in persons with ponderal excess, hyperlipidaemia and hyperglycaemia [4, 22–26], insulin resistance (IR) probably being a central pathogenic factor [27–32].

## Clinical description, natural history, and diagnostic approach

Most patients with NASH are asymptomatic and abnormal liver tests are often discovered fortuitously. The disturbance of liver tests is chronic with serum aminotransferase activities usually less than fourfold above the upper limit of normal. Higher aspartate aminotransferase (AST) than alanine aminotransferase (ALT) concentrations – in the absence of alcohol consumption – may indicate the presence of liver cirrhosis. Frequently, IR-related diseases (obesity, type 2 diabetes mellitus and hyperlipidaemia) coexist, but must not be present [18, 33].

NASH is, in a way, a diagnosis of exclusion. There is no biological test to reach the diagnosis positively. The chlorzoxazone test, used in alcoholics to measure the cytochrome P450E1 (CYP2E1) induction [34], has failed as a non-invasive test to identify patients with NASH [35].

The diagnostic approach is summarised in table 1. Chronic alcohol consumption must be excluded. An AST/ALT ratio less than 1 [36] and the determination of the carbohydrate deficient trans-

ferrin [37] may be helpful. Chronic ethanol intake of 20 g/day is considered the hepatotoxic threshold for women and 40 g/day for men [38]. In some studies, a daily alcohol intake of 20 g/day has been accepted as non-hepatotoxic [18, 33, 39, 40]. Associated metabolic conditions like obesity, diabetes, hyperlipidaemia and hypertension should be searched for and other liver disease excluded. A liver ultrasound shows the typical hyperechogenic parenchyma in most cases. Finally, a liver biopsy is necessary to reach the diagnosis. This should be evaluated by a pathologist familiar with the staging and grading of NASH [39, 41]. Liver histology has prognostic implications since liver steatosis without inflammation is a benign, non progressive condition [42] and the presence of ballooning degeneration, Mallory hyaline or fibrosis is associated with a liver-related mortality that is 10 times higher than in patients with a pure steatosis [39]. Sonography provides no insight into the presence of inflammation [43]. About 12% of patients with NASH may progress to cirrhosis within 7 years

**Table 1**

Diagnostic approach to a patient suspected to be suffering from NASH.

1. Personal history:	quantification of alcohol consumption (<40 g per week): rigorous exclusion of alcoholic liver disease
	metabolic manifestations: obesity, diabetes, hyperlipidaemia, hypertension
	risk factors for viral hepatitis
	drugs taken during the last 6 months: exclusion of drug-induced liver injury
	family history of liver disease: haemochromatosis, Wilson's disease, $\alpha_1$ -antitrypsin deficiency
2. Exclusion of other common liver diseases by laboratory tests:	serology for hepatitis B and C (HBs Ag, anti-HBc; anti-HCV)
	haemochromatosis (transferrin saturation, ferritin, genetic testing [C282Y, H63D])
	autoimmune hepatopathies (AIH, PBC, PSC): ANA, ASM, LKM1, AMA, ASLA, ANCA, IgG, IgM
	Wilson's disease (coeruloplasmine, quantitation of copper excretion in 24 h-urine sample), $\alpha_1$ -antitrypsin deficiency ( $\alpha_1$ -AT)
3. Liver ultrasound	compatible with hepatic steatosis
	exclusion of focal lesions
4. Liver biopsy: necessary to reach the diagnosis	

**Table 2**

Evidence justifying a liver biopsy in patients with suspected NASH.

*Why biopsy?*

- \_\_\_\_\_  
To reach the diagnosis of NASH a liver histology is required
- \_\_\_\_\_  
To obtain prognostic information (benign steatosis or potentially progressive NASH)
- \_\_\_\_\_  
To obtain information about the stage of the disease (degree of fibrosis)
- \_\_\_\_\_  
To estimate iron deposition

*Whom to biopsy?*

- \_\_\_\_\_  
Patients older than 45 years of age with elevated liver tests of unknown origin
- \_\_\_\_\_  
Patients of all ages with elevated liver tests of unknown origin and at least two manifestations of the metabolic syndrome

[44], which is a progression comparable with that of hepatitis C.

A substantial fraction of those patients with a cryptogenic cirrhosis probably suffered from NASH, as both diabetes mellitus and obesity were significantly more common in patients with cryptogenic cirrhosis and NASH compared to those with cirrhosis caused by hepatitis C or primary biliary cirrhosis [45, 46]. Other evidence for the notion that some cases of cryptogenic cirrhosis may represent burned-out NASH comes from a study showing a relatively high incidence of fatty liver disease and NASH in patients after orthotopic liver transplantation for cryptogenic cirrhosis [47]. Cirrhosis secondary to NASH may also be complicated by the development of hepatocellular carcinoma [48, 49]. One study by Ratziu et al. even suggests a comparable carcinogenic potential of

obesity-related cryptogenic cirrhosis (probably due to NASH) as in cirrhosis due to chronic hepatitis C [50]. Lastly, the histological assessment of hepatic iron stores is of importance, since hepatic iron overload may be pathogenic in hepatic steatosis and fibrosis [18, 33, 51–53].

Two studies define the indication for liver biopsy. Of 144 patients with NASH, none of those younger than 45 years old showed fibrosis on liver biopsy if their body mass index (BMI) was less than 31 kg/m<sup>2</sup> and diabetes mellitus was absent [54]. In the second study by Ratziu et al. an age above 50 years, a BMI >28 kg/m<sup>2</sup>, triglycerides >1.7 mmol/L, and ALT levels higher than twice the normal upper limit were independently associated with septal fibrosis [55]. Table 2 summarises the evidence justifying a liver biopsy in patients suspected to be suffering from NASH.

## Histology and differential diagnosis

Histological findings in NAFLD are very similar to those found in alcoholic liver disease: steatosis, hepatocyte ballooning, mild lobular inflammation and perisinusoidal collagen deposition. Histological features may range from simple steatosis with or without mild inflammation to advanced liver disease with fibrosis and cirrhosis [41]. At the cirrhotic stage the steatosis is often absent [23]. Histopathological grading and staging of NASH has been proposed by Brunt [41, 56]. It evaluates the degree of steatosis, the presence of hepatocellular ballooning and the lobular and portal inflammation in order to determine the grade and stages of the disease according to the extent of the fibrosis.

A few entities may pose diagnostic difficulties, for example when NASH affects obese teenagers [57]. In these patients, copper studies and genetic testing should be performed to exclude Wilson's disease. Frequently, an iron overload is observed in NASH patients [18, 33, 48, 58] and an increased

prevalence of mutations in the HFE gene has been reported [40]. Hereditary haemochromatosis has to be excluded by genetic testing when transferrin saturation is increased. The association of increased serum and liver iron concentrations as well as raised serum ferritin levels with a normal transferrin saturation in the absence of genetic haemochromatosis has been proposed as a new syndrome of primary liver iron overload (see below) [59]. Finally, variant phenotypes of  $\alpha_1$ -antitrypsin can occur in patients with NASH [60]. Actually, NASH being so prevalent, the coincidental presence of a second liver disease should not be surprising. Indeed, coexistence of steatosis or steatohepatitis has been described in the livers of patients with chronic hepatitis C and steatosis was associated with a higher degree of fibrosis [61–65]. Furthermore, there is evidence that the degree of steatosis may negatively influence treatment response to interferon in chronic hepatitis C [66].

## Pathogenesis of non-alcoholic fatty liver disease

### Pathogenesis of fatty liver

#### *Insulin resistance (IR)*

IR leads to an increased hepatic production of free fatty acids (FFAs) from glucose due to hyperinsulinism, and to increased circulating levels of FFAs due to an enhanced peripheral lipolysis [67, 68]. The increased uptake of FFAs by the liver exceeds its capacity to metabolise them by mitochondrial oxidation and to remove them by secretion into the blood as very low-density lipoproteins (VLDL) [69]. As a consequence, hepatic steatosis develops, generally considered as a "benign" prerequisite of NASH. In most cases, IR is seen in the context of obesity and non-insulin dependent diabetes mellitus [26, 29]. Marchesini et al. have shown that IR is associated with the presence of NASH, irrespective of BMI, fat distribution or glucose tolerance [70] and IR in NASH can occur in the absence of ponderal excess and diabetes [30, 31].

#### *The molecular basis of insulin resistance and the role of adipose tissue*

Adipose tissue is an important source of tumour necrosis factor alpha (TNF $\alpha$ ) [71, 72], which regulates insulin sensitivity [71, 73, 74]. TNF $\alpha$  suppresses the expression of proteins regulating fatty acid uptake and lipogenesis leading to elevated FFA levels [75, 76]. TNF $\alpha$  down regulates proteins mediating the effects of insulin, such as the adipocyte fatty acid binding protein aP2, adipin and insulin-responsive-glucose-transporter-4 (GLUT4) [76–81]. TNF $\alpha$  also promotes IR by down regulating peroxisome-proliferator-activated-receptor gamma (PPAR $\gamma$ ) [76], a nuclear receptor important in maintaining normal insulin sensitivity [82]. Serum TNF $\alpha$  concentrations correlate with the degree of obesity and hyperinsulinaemia [83–85]. Abdominal obesity is associated with higher circulating TNF $\alpha$  levels than peripheral obesity [86] and abdominal fat distribution reflected in a higher "waist to hip ratio" is a predictor of hepatic steatosis [87]. Crespo et al. demonstrated an overexpression of TNF $\alpha$  mRNA in NASH patients in adipose tissue as well as in the liver [88]. A polymorphism in the TNF $\alpha$  promoter (TNFA allele) associated with IR [89–91] is more prevalent in patients with NASH than in controls [92].

The role of other adipose tissue-derived cytokines such as interleukin-6 (IL-6) as mediators of IR is less clear [93]. Like TNF $\alpha$ , IL-6 is known to inhibit lipoprotein lipase (LPL) but, unlike TNF $\alpha$ , it does not stimulate lipolysis [94, 95]. Nevertheless, a significant relationship between plasma IL-6 and IR has been found in obese subjects [96].

Resistin has been linked to obesity and diabetes [97], but several studies have questioned the

role of this adipocyte-derived hormone in the aetiology of IR [98–100]. In contrast to resistin, leptin is clearly known to inhibit insulin action by attenuating tyrosine phosphorylation of the insulin-receptor substrate-1 (IRS-1) [101]. Both IR as well as lipid metabolism are worsened when leptin serum levels are increased [1, 2, 102]. Furthermore, recent data underline a pivotal role of leptin in the development of liver fibrosis [103]. Finally, a third adipocyte-derived hormone named adiponectin has been shown to protect against IR [104]. Additional data in humans are needed to further define its role.

### Pathogenesis of non-alcoholic steatohepatitis (inflammation and necrosis)

A second mechanism has been postulated to explain the progression of fatty liver into NASH [105]. An overview of mechanisms leading to NASH, liver fibrosis and cirrhosis is given in figure 1.

#### *Oxidative stress*

Free oxygen radicals exert their toxicity by lipid peroxidation, which finds a favourable environment for its perpetuation in a steatotic liver. As a consequence, the signalling molecules, malondialdehyde (MDA) and 4-hydroxynonenal (4-HN), are produced [106]. Hepatic stellate cells (HSCs) are activated by CYP2E1-derived reactive oxygen species and lipid peroxides [107]. 4-HN, for example, acts as a stimulator of HSCs [108, 109] leading to the production of collagen I [110]. Oxidative stress in hepatocytes has been linked to the expression of cytokines like interleukin-8 (IL-8) [111], providing another damaging pathway for the already exquisitely sensitive fatty liver.

*Antioxidant defence system:* Several endogenous antioxidant defence systems have been elaborated like superoxide dismutase, catalase and glutathione peroxidase. Exogenous antioxidants are  $\beta$ -carotene (vitamin A), lycopene, ascorbic acid (vitamin C) and  $\alpha$ -tocopherol (vitamin E). The latter is believed to be the "last antioxidant defence" in lipid membranes [112]. A relative deficiency in antioxidants can be important in situations promoting oxidative stress and lipid peroxidation. Obesity or IR could be such situations; decreased  $\alpha$ -tocopherol and  $\beta$ -carotene serum levels have been documented in obese children [113]. Serum antioxidant levels do not necessarily represent tissue levels [114]; hepatic antioxidant levels could be even lower in these situations.

*Oxidants:* The liver of patients with NASH provides many ingredients to trigger and promote oxidative stress. Hepatocellular steatosis can per se promote and aggravate lipid peroxidation. The mere presence of oxidizable fat in the liver triggers lipid peroxidation [115]. Hyperglycaemia can induce lipid peroxidation through the tricarboxylic

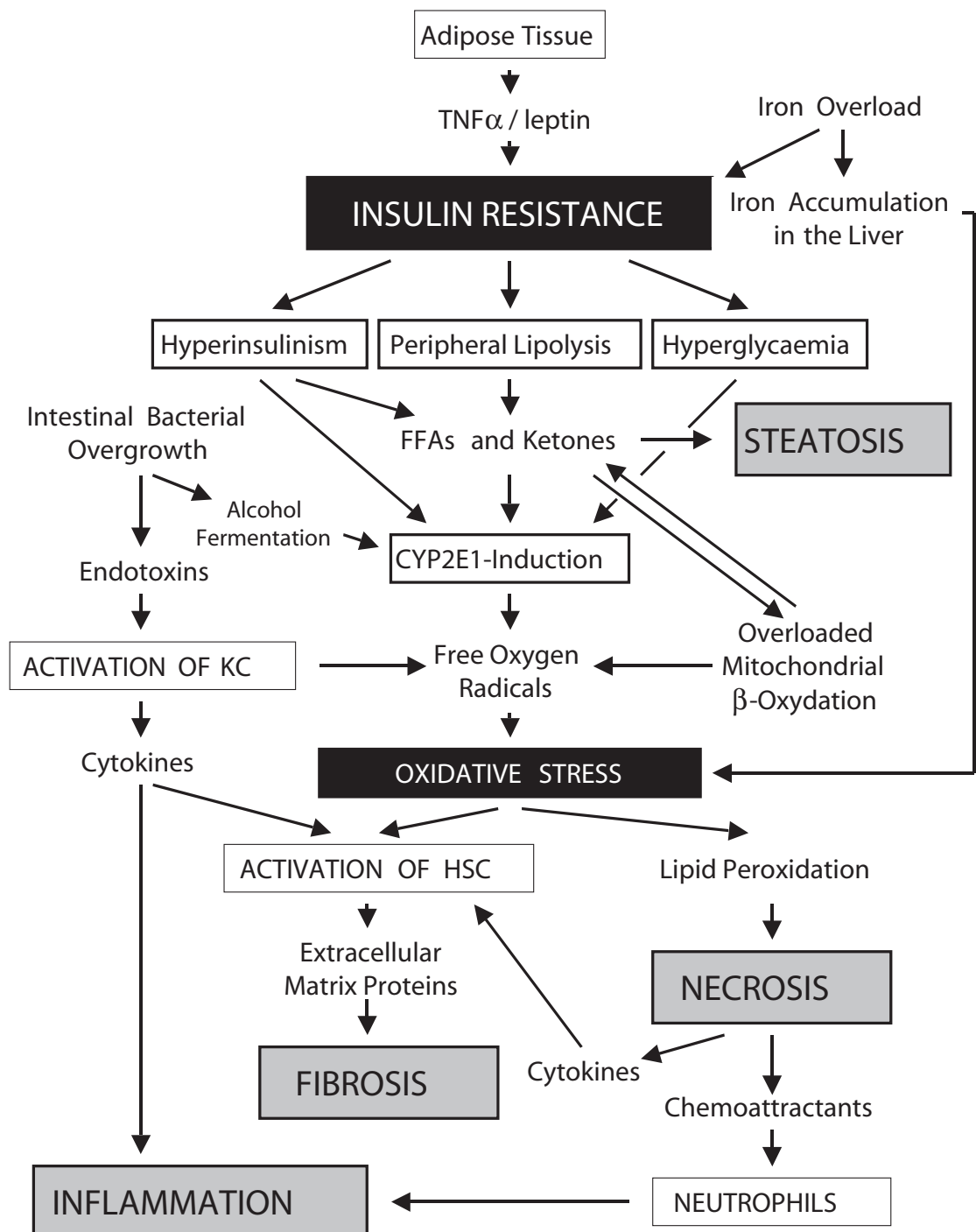
acid cycle pathway [116]. The cytochrome P450 2E1 (CYP2E1) plays a pivotal role in the pathogenesis of alcoholic liver disease since it generates superoxide anion, hydroxyl and hydroxyethyl radicals [117, 118] and is responsible for the microsomal ω-1 and ω-2 oxidation of FFAs leading to the formation of cytotoxic dicarboxylic acids [1]. The regulation of CYP2E1 expression is complex and partially under the negative control of insulin [119–121]. CYP2E1 is overexpressed in patients with NASH [122]. One can speculate that CYP2E1 induction in NASH results from a decreased sensitivity of hepatocytes to insulin due to insulin resistance. Other sources of oxidants are hepatic iron and activation of Kupffer cells (KCs).

*Iron overload*

Mild hepatic iron overload is found in up to 40% of patients with NASH [18, 33]. Mutations of the HFE gene may be one reason. C282Y heterozygosity and C282Y/H63D compound heterozygosity in NASH patients were associated with higher transaminase levels as well as more severe hepatic histopathological alterations [40]. In 1997, Moirand described a new syndrome with hepatic iron overload, elevated liver tests, hyperferritinemia, and normal transferrin saturation [59]. It is closely associated with insulin resistance and histologically to steatohepatitis [51]. It is still a matter of speculation as to how to explain the association of iron overload, liver injury or both with the

**Figure 1**

Pathogenic mechanisms leading to non-alcoholic steatohepatitis (NASH) and liver fibrosis. Increased production of TNFα from adipose tissue leads to insulin resistance. Enhanced concentrations of FFAs and ketones are the main stimulus for CYP2E1-induction in HC. Oxidative stress occurs as a central mechanism in NASH with the consequence of hepatocyte necrosis and activation of HSC, which are responsible for liver fibrosis. KC activation as a result of gut-derived endotoxins produces liver inflammation [HC = hepatocytes, HSC = hepatic stellate cells, KC = Kupffer cells].



IR syndrome [123]. Based on data from isolated fat cells [124], it has been hypothesized that insulin may lead to a redistribution of transferrin receptors to the cell surface where they mediate uptake of extracellular iron [125].

Two studies revealed that NASH patients with increased hepatic iron stores are at risk of developing hepatic fibrosis [18, 40]. Iron overload induces oxidative stress and lipid peroxidation by catalysing the production of free radicals such as hydroxyl radicals [126–128] and activating KC [129]. Elevated intracellular iron levels may promote NF- $\kappa$ B activation and TNF $\alpha$  expression in hepatic macrophages [130].

*Endotoxins, endogenous alcohol formation, Kupffer cell activation and cytokine release*

Since NASH can be reversed by antibiotics under experimental conditions [131–133], intestinal bacterial overgrowth may play a role in the pathogenesis of NASH. Further evidence for this pathogenic mechanism was obtained by Wigg et al., who demonstrated a higher prevalence of small intestinal bacterial overgrowth in NASH patients [134]. Diabetes predisposes to bacterial overgrowth by inducing an intestinal dysmotility and stasis. However, no significant differences were found between NASH patients with and without small intestinal bacterial overgrowth concerning intestinal permeability, blood endotoxin levels and TNF $\alpha$  serum concentrations [135]. Alcohol production by the intestinal microflora could contribute to this effect. In an animal model for NASH (ob/ob mice) an increased endogenous gastrointestinal production of ethanol was found, which was reversed after antibiotic treatment [135]. Once KCs are activated they produce mediators such as prostaglandins, reactive oxygen species, cytokines, nitric oxide and different proteases initiating a cascade of events similar to those in alcoholic liver disease [136].

**Pathogenesis of liver fibrosis (Hepatic stellate cell activation)**

HSCs are situated in the space of Dissé between endothelial cells and hepatocytes with which they communicate by producing cytokines and growth factors and by expressing cytokine re-

ceptors. They are key cells in the process of liver fibrosis by producing extracellular matrix proteins and collagens when activated [137–139]. Several factors can activate HSCs such as, for example, oxidative stress, transforming growth factor beta-1 (TGF $\beta$ 1) and connective tissue growth factor (CTGF).

HSC activation occurs in NASH, and the degree of HSC activation correlates with the degree of fibrosis [140]. HSCs are preferentially activated in zone 3 of the liver lobule [141], the perivenular region where CYP2E1 [120, 142] and other cytochromes such as CYP2A and CYP3A [141] are predominantly expressed. These observations and the report of an association between steatosis and lipid peroxidation in zone 3 [143] support the view that cytochrome P450 enzymes are involved in the pathophysiology of NASH. Nieto et al. were able to demonstrate *in vitro* a complete prevention of HSC activation by the application of CYP2E1 inhibitors [107].

TGF $\beta$ 1 mediates the transformation of quiescent HSCs into myofibroblast-like cells with an increased production of extracellular matrix proteins including type I collagen [144–146]. TGF $\beta$ 1 is secreted by activated KCs and by HSCs. Its plasma concentration is elevated in NASH patients compared to patients with steatosis and healthy subjects [147], suggesting that this cytokine is involved in the fibrogenesis in NASH.

CTGF is overexpressed in liver cirrhosis and produced in HSCs [148–150]. The expression of the CTGF gene is induced by TGF $\beta$ 1 [149] and CTGF may mediate many activities of TGF $\beta$ 1 including collagen production [151]. Overexpression of CTGF was also observed in the liver of patients with NASH and correlated with fibrosis [152]. Incubation of HSCs with glucose or insulin up-regulated CTGF mRNA and protein levels indicating that insulin may directly influence the development of fibrosis. Another *in vitro* study suggests that TNF $\alpha$  also induces CTGF expression in HSCs [153].

Finally, Ikejima et al. found in an animal model that leptin, produced in transactivated HSCs, promotes hepatic fibrogenesis [103]. It may contribute, at least in part, to the progression from benign hepatic steatosis to NASH and cirrhosis [154].

## Treatment options

There is no treatment with an efficacy proven in randomised controlled trials. Promising treatment options and their rationale are summarised in table 3.

**Weight loss**

IR is improved by weight loss [155, 156]. Weight loss is associated with reduced lipid oxidation and increases glucose utilisation [157, 158].

Moderate long-term changes in weight of obese subjects may be associated with better insulin sensitivity and glucose tolerance [159–161], which translates in normalisation of liver tests [162, 163]. Gastric bariatric surgery reduces IR [164–166] and may improve NASH [167, 168]. Weight loss should not be as abrupt as after jejunoileal bypass, since this could lead to “acute” NASH and liver failure [169, 170]. In addition to weight loss,

**Table 3**  
Therapeutic options.

Treatment of the IR (metabolic) syndrome	weight loss
	increasing insulin sensitivity
	metformin
	thiazolidinedione
	decreasing hypertriglyceridaemia
Treatment of iron overload	venesection
Treatment of oxidative stress	vitamin E
	betain
	silymarin
	SAMe
	N-acetylcystein
Treatment with UDCA	
Liver transplantation	

physical activity may further improve IR [171, 172].

### Enhancing insulin sensitivity (metformin, thiazolidinediones)

Metformin has been shown to be an effective treatment of fasting hyperglycaemia in patients with non insulin-dependent diabetes mellitus (NIDDM). It works by decreasing hepatic glucose output mostly due to an inhibition of the gluconeogenesis [173]. Improvement of liver tests and histology in three patients with NASH was first described by Coyle [174]. Further evidence for beneficial effects of metformin was provided by Marchesini et al. who treated 20 non-diabetic patients with non-biopsy proven hepatic steatosis and elevated liver transaminases over a period of 4 months [175]. A significant decrease in transaminase levels and liver volume was found as well as a significant improvement in insulin sensitivity. However, as discussed in correspondence to their article, metformin should be used with caution in patients with advanced liver disease because of the risk of lactic acidosis [176–179]. Idiosyncratic hepatotoxicity of metformin itself has been described [180, 181]. Metformin cannot yet be recommended for the treatment of NASH until the results of randomised controlled studies become available.

Thiazolidinediones (TZDs) – troglitazone, rosiglitazone and pioglitazone – improve insulin sensitivity enhancing glucose disposal and influencing lipid metabolism [182, 183]. TZDs activate PPAR $\gamma$ , a nuclear receptor expressed in adipose tissue to maintain normal insulin sensitivity. PPAR $\gamma$  activation reduces release of FFAs and TNF $\alpha$  by adipocytes [184–186]. Troglitazone is no longer available because of cases of severe hepatotoxicity [187–192]. In contrast to rosiglitazone and pioglitazone, troglitazone has been found to induce cytochrome P4503A4 (CYP3A4) predisposing it to drug interactions [193]. Nevertheless, there are also some reports of possible rosiglitazone-related hepatotoxicity [194, 195] and pioglitazone-related hepatotoxicity [196, 197]. In one pilot study, 10 female patients with histologically proven NASH have been treated with troglitazone for up to 6

months at a dose of 400 mg qd [198]. Normalisation of ALT levels was observed in 7 of these patients, but this biochemical response was not paralleled by a significant histological improvement. Although rosiglitazone and pioglitazone do not share the hepatotoxic profile of troglitazone [193, 199], their use in NASH patients can be only recommended within protocols.

### Treatment of hypertriglyceridaemia (gemfibrozil, clofibrate, bezafibrate)

Since lowering plasma lipids by bilio-pancreatic bypass surgery significantly improves insulin sensitivity before the surgery has effects on body weight [200] and intracellular lipids may be cytotoxic [201], lipid-lowering agents may be beneficial in NASH. Only limited clinical data from pilot studies are available. In a prospective, randomised and placebo-controlled study with 46 patients using oral gemfibrozil for 4 weeks [202], a significant improvement in liver tests and triglyceride levels was observed independent of weight loss. There is further positive report with bezafibrate in three patients with tamoxifen and in one patient with toremifene-induced NASH [203]. This PPAR $\gamma$  receptor activator may compensate for drug-induced insufficient mitochondrial  $\beta$ -oxidation via the activation of peroxisomal  $\beta$ -oxidation. On the other hand, clofibrate was shown to be ineffective [24]. All these lipid lowering substances seem to be safe, although rare cases of fibrates-induced hepatitis have been reported [204–207]. In view of the little clinical information on fibrates in the treatment of NASH no definite conclusions can be made.

### Iron depletion

One study tried to elucidate the effect of iron depletion on the development of NASH [53]. Repetitive phlebotomie was performed to decrease iron stores to a level of near iron deficiency. No supranormal levels of body iron could be detected in these patients. Iron depletion improved both fasting and glucose-stimulated plasma insulin concentrations suggesting a positive effect on insulin resistance and led to a normalisation of the serum aminotransferase activities. Unfortunately, no

liver biopsies were performed to assure the diagnosis of NASH and to quantify the hepatic iron. It has been shown that phlebotomies can be performed safely in these patients [52]. These observations as well as the growing evidence from studies investigating iron as co-morbid factor in other chronic liver diseases [208, 209] suggest, that iron stores should be depleted in NASH patients with abnormal iron parameters.

#### Treatment of oxidative stress

$\alpha$ -Tocopherol or vitamin E is a powerful scavenger of free radicals in biological membranes [112] and has an excellent safety profile [210] with possible cardiovascular protective properties [211]. In an open-labelled pilot study, 11 children with a mean body mass index of 32 kg/m<sup>2</sup> were treated with vitamin E, 400 IU to 1200 IU per day for 4 to 10 months. The diagnosis of NASH was based on chronically elevated serum aminotransferase levels, a diffusely hyperechogenic liver on ultrasonography and on the exclusion of other common causes of liver disease [212]. A significant decrease in liver enzyme tests was noted. Unfortunately this study was performed without liver histology. In another trial [213], 8 patients with NASH and 8 patients with fatty liver, as diagnosed by histology, were first subjected to a diet, leading to an improvement of serum alanine aminotransferase levels only in the patients with fatty liver. Then, they were all treated with  $\alpha$ -tocopherol. This improved alanine aminotransferase levels in NASH patients and was paralleled by a decrease of TGF $\beta$ 1 serum concentration, which was elevated at baseline in patients with NASH. This observation supports a link between free oxygen radical production and the activation of fibrogenic cytokines. In Switzerland, there is an ongoing double-blind, randomised and placebo-controlled study comparing ursodeoxycholic acid (UDCA) and vitamin E with UDCA monotherapy and placebo.

Betaines are trimethyl amino acids derived either from choline or from the diet. They function as methyl donors and, therefore, reduce lipid accumulation in the liver [214]. Betaines are important to form phosphatidyl choline (PC), a component of VLDL, which is the key molecule to export lipids from hepatocytes [215]. Supplementation with betaine improves the export of lipids from hepatocytes. In a trial with 10 NASH patients, seven patients took 20 g (!) betaine per day for one year [216]. A significant improvement in serum transaminase levels was noted, and in six patients, where a second liver biopsy could be obtained, a marked improvement in the degree of steatosis, necroinflammation and fibrosis occurred. Thus, betaine is a promising compound and may play a role in the future treatment of NASH.

Silymarin acts as a scavenger of free oxygen radicals decreasing lipid peroxidation [217]. Although promising results have been obtained with

silymarin in patients with alcoholic liver disease [218–221], the results of a randomised, controlled, double-blind multicentre study on 200 alcoholics with cirrhosis were disappointing, showing neither an effect on the course of the disease nor a survival benefit in patients receiving silymarin compared to the placebo group [222]. There are no studies with silymarin in patients with NASH, but according to the data of Velussi et al., who found that silymarin treatment in patients affected by alcoholic cirrhosis and diabetes was associated with a reduction of IR and a significant decrease in fasting insulin levels suggesting an improvement of the activity of endogenous and exogenous insulin, this substance could be interesting for the treatment of NASH [220, 221].

S-adenosylmethionine (SAME), which is the activated form of methionine, has potential in alcoholic as well as in non-alcoholic liver disease [223]. N-acetylcysteine, which is a glutathione prodrug and known to decrease oxidative stress in the liver, may theoretically also be helpful in NASH, but clinical data are lacking.

#### Treatment with ursodeoxycholic acid (UDCA)

UDCA (13–15 mg/kg/d) for one year improved biological abnormalities including steatosis [241]. This has been confirmed by other studies, where an improvement of transaminases was observed [224, 225] but not by all [226]. The mode of action of UDCA is a matter of speculation, but it has cytoprotective, chemoprotective, antioxidant and immunomodulatory properties [227]. The long-term treatment of NASH patients with UDCA in monotherapy or in combination with vitamin E is currently under investigation.

#### Liver transplantation

In a large transplantation programme in the United States about 3% of liver transplantations were performed for NASH-induced end-stage liver disease [228]. This study also indicates that post-transplantation steatosis occurred in two thirds of recipients compared to only 5 to 15% in those transplanted for other liver diseases. In one third NASH recurred and significant fibrosis developed within one year post transplantation. Progression to cirrhosis was found in about 12.5% of patients with former NASH. These findings were corroborated in two other studies [229, 230]. Early treatment of recurrent NASH with antioxidants or UDCA has been advocated [231].

---

*Correspondence:*

*J.-F. Dufour, MD*

*Department of Clinical Pharmacology*

*University of Bern*

*35 Murtenstrasse*

*CH-3010 Bern*

*E-Mail: jf.dufour@ikp.unibe.ch*



## References

- 1 Angulo P. Non-alcoholic fatty liver disease. *N Engl J Med* 2002; 346:1221-31.
- 2 Younossi ZM, Diehl AM, Ong JP. Non-alcoholic fatty liver disease: an agenda for clinical research. *Hepatology* 2002;35: 746-52.
- 3 Clark JM, Brancati FL, Diehl AM. Non-alcoholic fatty liver disease. *Gastroenterology* 2002;122:1649-57.
- 4 Ludwig J, Viggiano RT, McGill DB. Non-alcoholic steatohepatitis: Mayo Clinic experience with a hitherto unnamed disease. *Mayo Clin Proc* 1980;55:342-8.
- 5 Peters RL, Gay T, Reynolds TB. Post-jejunoileal-bypass hepatic disease. Its similarity to alcoholic hepatic disease. *Am J Clin Pathol* 1975;63:318-31.
- 6 Adler M, Schaffner F. Fatty liver hepatitis and cirrhosis in obese patients. *Am J Med* 1979;67:811-6.
- 7 Nasrallah SM, Wills CE Jr, Galambos JT. Liver injury following jejunoileal bypass. Are there markers? *Ann Surg* 1980; 192:726-9.
- 8 Hocking MP, Davis GL, Franzini DA, Woodward ER. Long-term consequences after jejunoileal bypass for morbid obesity. *Dig Dis Sci* 1998;43:2493-9.
- 9 Markowitz JS, Seu P, Goss JA, Yersiz H, Markmann JF, Farmer DG, et al. Liver transplantation for decompensated cirrhosis after jejunoileal bypass: a strategy for management. *Transplantation* 1998;65:570-2.
- 10 Lowell JA, Shenoy S, Ghalib R, Caldwell C, White FV, Peters M, et al. Liver transplantation after jejunoileal bypass for morbid obesity. *J Am Coll Surg* 1997;185:123-7.
- 11 Kim WR, Poterucha JJ, Porayko MK, Dickson ER, Steers JL, Wiesner RH. Recurrence of non-alcoholic steatohepatitis following liver transplantation. *Transplantation* 1996;62:1802-5.
- 12 Zimmerman H. Drug-induced liver disease. *Drugs* 1978;16: 25-45.
- 13 Pessayre D, Bichara M, Degott C, Potet F, Benhamou J, Feldmann G. Perhexilene maleate-induced cirrhosis. *Gastroenterology* 1979;76:170-7.
- 14 Seki K, Minami Y, Nishikawa M, Kawata S, Miyoshi S, Imai Y. "Non-alcoholic steatohepatitis" induced by massive doses of synthetic estrogen. *Gastroenterol Jpn* 1983;18:197-203.
- 15 Simon J, Manley P, Brien J, Armstrong P. Amiodarone hepatotoxicity simulating alcoholic liver disease. *N Engl J Med* 1984; 311:167-72.
- 16 Novaro G. Isoniazid and non-alcoholic steatohepatitis (letter). *J Clin Gastroenterol* 1999;28:180.
- 17 Murata Y, Ogawa Y, Saibara T, Nishioka A, Fujiwara Y, Fukumoto M, et al. Unrecognised hepatic steatosis and non-alcoholic steatohepatitis in adjuvant tamoxifen for breast cancer patients. *Oncol Rep* 2000;7:1299-1304.
- 18 Bacon BR, Farahvash MJ, Janney CG, Neuschwander-Tetri BA. Non-alcoholic steatohepatitis: an expanded clinical entity. *Gastroenterology* 1994;107:1103-9.
- 19 James O, Day C. Non-alcoholic steatohepatitis: another disease of affluence. *Lancet* 1999;353:1634-6.
- 20 Contos MJ, Synal AJ. The clinicopathologic spectrum and management of non-alcoholic fatty liver disease. *Adv Anat Pathol* 2002;9:37-51.
- 21 Wanless IR, Lentz JS. Fatty liver hepatitis (steatohepatitis) and obesity: an autopsy study with analysis of risk factors. *Hepatology* 1990;11:74-80.
- 22 Lee RG. Non-alcoholic steatohepatitis: a study of 49 patients. *Hum Pathol* 1989;20:594-8.
- 23 Powell EE, Cooksley WG, Hanson R, Searle J, Halliday JW, Powell LW. The natural history of non-alcoholic steatohepatitis: a follow-up study of forty-two patients for up to 21 years. *Hepatology* 1990;11:74-80.
- 24 Laurin J, Lindor KD, Crippin JS, Gossard A, Gores GJ, Ludwig J, et al. Ursodeoxycholic acid or clofibrate in the treatment of non-alcohol-induced steatohepatitis: a pilot study. *Hepatology* 1996;23:1464-7.
- 25 Pinto HC, Baptista A, Camilo ME, Valente A, Saragoca A, de Moura MC. Non-alcoholic steatohepatitis. Clinicopathological comparison with alcoholic hepatitis in ambulatory and hospitalized patients. *Dig Dis Sci* 1996;41:172-9.
- 26 Reid AE. Non-alcoholic steatohepatitis. *Gastroenterology* 2001; 121:710-23.
- 27 Sanyal AJ, Campbell-Sargent C, Mirshahi F, Rizzo WB, Contos MJ, Sterling RK, et al. Non-alcoholic steatohepatitis: association of insulin resistance and mitochondrial abnormalities. *Gastroenterology* 2001;120:1183-92.
- 28 Dixon JB, Bhathal PS, O'Brien PE. Nonalcoholic fatty liver disease: Predictors of non-alcoholic steatohepatitis and liver fibrosis in the severely obese. *Gastroenterology* 2001;121: 91-100.
- 29 Marchesini G, Brizi M, Bianchi G, Tomassetti S, Bugianesi E, Lenzi M, et al. Non-alcoholic fatty liver disease: A feature of the metabolic syndrome. *Diabetes* 2001;50:1844-50.
- 30 Pagano G, Pacini G, Musso G, Gambino R, Mecca F, Depetris N, et al. Non-alcoholic steatohepatitis, insulin resistance, and metabolic syndrome: Further evidence for an etiologic association. *Hepatology* 2002;35:367-72.
- 31 Chitturi S, Abeygunasekera S, Farrell GC, Holmes-Walker J, Hui JM, Fung C, et al. NASH and insulin resistance: Insulin hypersecretion and specific association with the insulin resistance syndrome. *Hepatology* 2002;35:373-9.
- 32 Marchesini G, Forlani G. NASH: From liver diseases to metabolic disorders and back to clinical hepatology. *Hepatology* 2002;35:497-8.
- 33 George D, Goldwurm S, MacDonald G, Cowley LL, Walker NI, Ward PJ, et al. Increased hepatic iron concentration in non-alcoholic steatohepatitis is associated with increased fibrosis. *Gastroenterology* 1998;114:311-8.
- 34 Oneta CM, Lieber CS, Li J, Ruttimann S, Schmid B, Lattmann J, Rosman AS, et al. Dynamics of cytochrome P4502E1 activity in man: induction by ethanol and disappearance during withdrawal phase. *J Hepatol* 2002;36:47-52.
- 35 Semela D, Ledermann M, Zimmermann A, Dufour J-F. Activity of CYP2E1 by the chlorzoxazone test in patients with non-alcoholic steatohepatitis and activation of stellate cells. *J Hepatol* 2002;36(Suppl.1):146 [Abstract].
- 36 Sorbi D, Boynton J, Lindor KD. The ratio of aspartate aminotransferase to alanine aminotransferase: potential value in differentiating non-alcoholic steatohepatitis from alcoholic liver disease. *Am J Gastroenterol* 1999;94:1018-22.
- 37 Fletcher LM, Kwok-Gain I, Powell EE, Powell LW, Halliday JW. Markers of chronic alcohol ingestion in patients with non-alcoholic steatohepatitis: an aid to diagnosis. *Hepatology* 1991; 13:455-9.
- 38 McCullough AJ, O'Connor JF. Alcoholic liver disease: proposed recommendations for the American College of Gastroenterology. *Am J Gastroenterol* 1998;93:2022-36.
- 39 Matteoni CA, Younossi ZM, Gramlich T, Boparai N, Liu YC, McCullough AJ. Non-alcoholic fatty liver disease: a spectrum of clinical and pathological severity. *Gastroenterology* 1999; 116:1413-9.
- 40 Bonkovsky HL, Jawaid Q, Tortorelli K, LeClair P, Cobb J, Lambrecht RW, et al. Non-alcoholic steatohepatitis and iron: increased prevalence of mutations of the HFE gene in non-alcoholic steatohepatitis. *J Hepatol* 1999;31:421-9.
- 41 Brunt EM. Non-alcoholic steatohepatitis: definition and pathology. *Sem Liv Dis* 2001;21:3-16.
- 42 Teli MR, James OF, Burt AD, Bennett MK, Day CP. The natural history of non-alcoholic fatty liver: a follow-up study. *Hepatology* 1995;22:1714-9.
- 43 Saverymuttu SH, Joseph AE, Maxwell JD. Ultrasound scanning in the detection of hepatic fibrosis and steatosis. *Br Med J (Clin Res Ed)* 1986;292:13-5.
- 44 Sheth SG, Gordon FD, Chopra S. Non-alcoholic steatohepatitis. *Ann Intern Med* 1997;126:137-45.
- 45 Caldwell SH, Oelsner DH, Iezzoni JC, Hespenheide EE, Battle EH, Driscoll CJ. Cryptogenic cirrhosis: clinical characterization and risk factors for underlying disease. *Hepatology* 1999; 29:664-9.
- 46 Poonawala A, Nair SP, Thuluvath PJ. Prevalence of obesity and diabetes in patients with cryptogenic cirrhosis: a case-control study. *Hepatology* 2000;32:689-92.
- 47 Ong J, Younossi ZM, Reddy V, Price LL, Gramlich T, Mayes J, et al. Cryptogenic cirrhosis and post transplantation nonalcoholic fatty liver disease. *Liver Transpl* 2001;7:797-801.
- 48 Zen Y, Katayanagi K, Tsuneyama K, Harada K, Araki I, Nakanuma Y. Hepatocellular carcinoma arising in non-alcoholic steatohepatitis. *Pathol Int* 2001;51:127-31.
- 49 Bugianesi E, Leone N, Vanni E, Marchesini G, Brunello F, Carucci P, et al. Expanding the natural history of non-alcoholic steatohepatitis: from cryptogenic cirrhosis to hepatocellular carcinoma. *Gastroenterology* 2002;123:134-40.
- 50 Ratziu V, Bonyhay L, DiMartino V, Charlotte F, Cavallaro L, Sayegh-Taïnturier MH, et al. Survival, liver failure, and hepatocellular carcinoma in obesity-related cryptogenic cirrhosis. *Hepatology* 2002;35:1485-1493.

- 51 Mendler MH, Turlin B, Moirand R, Jouanolle AM, Sapey T, Guyader D, et al. Insulin resistance-associated hepatic iron overload. *Gastroenterology* 1999;117:1155-63.
- 52 Guillygomarc'h A, Mendler MH, Moirand R, Laine F, Quentin V, David V, et al. Venesection therapy of insulin resistance-associated hepatic iron overload. *J Hepatol* 2001;35:344-9.
- 53 Facchini FS, Hua NW, Stoohs RA. Effect of iron depletion in carbohydrate-intolerant patients with clinical evidence of non-alcoholic fatty liver disease. *Gastroenterology* 2002;122:931-9.
- 54 Angulo P, Keach JC, Batts KP, Lindor KD. Independent predictors of liver fibrosis in patients with non-alcoholic steatohepatitis. *Hepatology* 1999;30:1356-62.
- 55 Ratziu V, Giral P, Charlotte F, Bruckert E, Thibault V, Theodorou I, et al. Liver fibrosis in overweight patients. *Gastroenterology* 2000;118:1117-23.
- 56 Brunt EM, Janney CG, Di Bisceglie AM, Neuschwander-Tetri BA, Bacon BR. Non-alcoholic steatohepatitis: a proposal for grading and staging the histological lesions. *Am J Gastroenterol* 1999;94:2467-74.
- 57 Baldrige AD, Perez-Atayde AR, Graeme-Cook F, Higgins L, Lavine JE. Idiopathic steatohepatitis in childhood: a multicenter retrospective study. *J Pediatr* 1995;127:700-4.
- 58 Guillygomarc'h A, Mendler MH, Moirand R, Jouanolle AM, David V, Deugnier Y. HFE mutations in insulin resistance-associated hepatic iron overload. *J Hepatol* 2000;33:515-6.
- 59 Moirand R, Mortaji AM, Loreal O, Paillard F, Brissot P, Deugnier Y. A new syndrome of liver iron overload with normal transferrin saturation. *Lancet* 1997;349:95-7.
- 60 Czaja AJ. Frequency and significance of phenotypes for alpha1-antitrypsin deficiency in type 1 autoimmune hepatitis. *Dig Dis Sci* 1998;43:1725-31.
- 61 Hourigan LF, Macdonald GA, Purdie D, Whitehall VH, Shorthouse C, Clouston A, et al. Fibrosis in chronic hepatitis C correlates significantly with body mass index and steatosis. *Hepatology* 1999;29:1725-31.
- 62 Giannini E, Ceppa P, Botta F, Fasoli A, Romagnoli P, Cresta E, et al. Steatosis and bile duct damage in chronic hepatitis C: distribution and relationships in a group of Northern Italian patients. *Liver* 1999;19:432-7.
- 63 Ong JP, Younossi ZM, Speer C, Olano A, Gramlich T, Boparai N. Chronic hepatitis C and superimposed non-alcoholic fatty liver disease. *Liver* 2001;21:266-71.
- 64 Adinolfi LE, Utili R, Andreana A, Tripodi MF, Marracino M, Gambardella M, et al. Serum HCV RNA levels correlate with histological liver damage and concur with steatosis in progression of chronic hepatitis C. *Dig Dis Sci* 2001;46:1677-83.
- 65 Clouston AD, Jonsson JR, Purdie DM, Macdonald GA, Pandeya N, Shorthouse C, et al. Steatosis and chronic hepatitis C: analysis of fibrosis and stellate cell activation. *J Hepatol* 2001;34:314-20.
- 66 Wedemeyer H, et al. Liver steatosis and response to interferon alpha in patients with chronic hepatitis C. *Hepatology* 1998; 28:569A [Abstract].
- 67 Lombardi B. Considerations on the pathogenesis of fatty liver. *Lab Invest* 1966;15:1-20.
- 68 D'Anzani MU. Biochemical aspects of fatty liver. In: *Hepatotoxicology*. Ed. Meeks RG, Harrison SD, Bull RJ. Boca Raton, FL, CRC Press 1991, pp. 327-98.
- 69 Chitturi S, Farrell GC. Etiopathogenesis of non-alcoholic steatohepatitis. *Sem Liv Dis* 2001;21:27-41.
- 70 Marchesini G, Brizi M, Morselli-Labate AM, Bianchi G, Bugianesi E, McCullough AJ, et al. Association of non-alcoholic fatty liver disease with insulin resistance. *Am J Med* 1999;107: 450-5.
- 71 Hotamisligil GS, Shargill NS, Spiegelman BM. Adipose expression of tumor necrosis factor-alpha: direct role in obesity-linked insulin resistance. *Science* 1993;259:107:87-91.
- 72 Montague CT, Prins JB, Sanders L, Zhang J, Sewter CP, Digby J, et al. Depot-related gene expression in human subcutaneous and omental adipocytes. *Diabetes* 1998;47:1384-91.
- 73 Morin CL, Eckel RH, Marcel T, Pagliassotti MJ. High fat diets elevate adipose tissue-derived tumor necrosis factor-alpha activity. *Endocrinology* 1997;138:4665-71.
- 74 Beutler B, Cerami A. Cachectin and tumour necrosis factor as two sides of the same biological coin. *Nature* 1986;320:584-8.
- 75 Torti FM, Dieckmann B, Beutler B, Cerami A, Ringold GM. A macrophage factor inhibits adipocyte gene expression: an in vitro model of cachexia. *Science* 1985;229:867-9.
- 76 Zhang B, Berger J, Hu E, Szalkowski D, White-Carrington S, Spiegelman BM, et al. Negative regulation of peroxisome proliferator-activated receptor-gamma gene expression contributes to the antiadipogenic effects of tumor necrosis factor-alpha. *Mol Endocrinol* 1996;10:1457-66.
- 77 Hotamisligil GS, Johnson RS, Distel RJ, Ellis R, Papaioannou VE, Spiegelman BM. Uncoupling of obesity from insulin resistance through a targeted mutation in aP2, the adipocyte fatty acid binding protein. *Science* 1996;274:1377-9.
- 78 Hotamisligil GS, Peraldi P, Budavari A, Ellis R, White MF, Spiegelman BM. IRS-1-mediated inhibition of insulin receptor tyrosine kinase activity in TNF-alpha- and obesity-induced insulin resistance. *Science* 1996;271:665-8.
- 79 Szalkowski D, White-Carrington S, Berger J, Zhang B. Anti-diabetic thiazolidinediones block the inhibitory effect of tumor necrosis factor-alpha on differentiation, insulin-stimulated glucose uptake, and gene expression in 3T3-L1 cells. *Endocrinology* 1995;136:1474-81.
- 80 Stephens JM, Pekala PH. Transcriptional repression of the GLUT4 and C/EBP genes in 3T3-L1 adipocytes by tumor necrosis factor-alpha. *J Biol Chem* 1991;266:21839-45.
- 81 Stephens JM, Lee J, Pilch PF. Tumor necrosis factor-alpha-induced insulin resistance in 3T3-L1 adipocytes is accompanied by a loss of insulin receptor substrate-1 and GLUT4 expression without a loss of insulin receptor-mediated signal transduction. *J Biol Chem* 1997;272:971-6.
- 82 Barroso I, Gurnell M, Crowley VE, Agostini M, Schwabe JW, Soos MA, et al. Dominant negative mutations in human PPARgamma associated with severe insulin resistance, diabetes mellitus and hypertension. *Nature* 1999;402:880-3.
- 83 Zimman B, Hanley AJ, Harris SB, Kwan J, Fantus IG. Circulating tumor necrosis factor-alpha concentrations in a native Canadian population with high rates of type 2 diabetes mellitus. *J Clin Endocrinol Metab* 1999;84:272-8.
- 84 Gonzalez F, Thusu K, Abdel-Rahman E, Prabhala A, Tomani M, Dandona P. Elevated serum levels of tumor necrosis factor alpha in normal-weight women with polycystic ovary syndrome. *Metabolism* 1999;48:437-41.
- 85 Mishima Y, Kuyama A, Tada A, Takahashi K, Ishioka T, Kibata M. Relationship between serum tumor necrosis factor-alpha and insulin resistance in obese men with type 2 diabetes mellitus. *Diabetes Res Clin Pract* 2001;52:119-23.
- 86 Tsigos C, Kyrou I, Chala E, Tsapogas P, Stavrdis JC, Raptis SA, et al. Circulating tumor necrosis factor alpha concentrations are higher in abdominal versus peripheral obesity. *Metabolism* 1999;48:1332-5.
- 87 Kral JG, Schaffner F, Pierson RN Jr, Wang J. Body fat topography as an independent predictor of fatty liver. *Metabolism* 1993;42:548-51.
- 88 Crespo J, Cayon A, Fernandez-Gil P, Hernandez-Guerra M, Mayorga M, Dominguez-Diez A, et al. Gene expression of tumor necrosis factor alpha and TNF-receptors, p55 and p75, in non-alcoholic steatohepatitis patients. *Hepatology* 2001;34: 1158-63.
- 89 Skoog T, Eriksson P, Hoffstedt J, Ryden M, Hamsten A, Armer P. Tumour necrosis factor-alpha (TNF-alpha) polymorphisms -857C/A and -863C/A are associated with TNF-alpha secretion from human adipose tissue. *Diabetologia* 2001;44:654-5.
- 90 Fernández-Real JM, Gutiérrez C, Ricart W, Casamitjana R, Fernandez-Castaner M, Vendrell J, et al. The TNF-alpha gene Nco I polymorphism influences the relationship among insulin resistance, percent body fat, and increased serum leptin levels. *Diabetes* 1997;46:1468-72.
- 91 Fernández-Real JM, Broch M, Vendrell J, Ricart W, Skoog T, et al. (2001) Tumour necrosis factor-alpha (TNF-alpha) polymorphisms -857C/A and -863C/A are associated with TNF-alpha secretion from human adipose tissue. *Diabetologia* 44:654-655. *Diabetologia* 2002;45:149-50.
- 92 Valenti L, Fracanzani AL, Dongiovanni P, Santorelli G, Branchi A, Taioli E, et al. Tumor necrosis factor alpha promoter polymorphisms and insulin resistance in non-alcoholic fatty liver disease. *Gastroenterology* 2002;122:274-80.
- 93 Coppack SW. Pro-inflammatory cytokines and adipose tissue. *Proc Nutr Soc* 2001;60:349-56.
- 94 Feingold KR, Grunfeld C. Role of cytokines in inducing hyperlipidemia. *Diabetes* 1992;41(Suppl.2):97-101.
- 95 Greenberg AS, Nordan RP, McIntosh J, Calvo JC, Scow RO, Jablons D. Interleukin-6 reduces lipoprotein lipase activity in adipose tissue of mice in vivo and in 3T3-L1 adipocytes: a possible role for interleukin-6 in cancer cachexia. *Cancer Res* 1992;52:4113-6.
- 96 Kern PA, Ranganathan S, Li C, Wood L, Ranganathan G. Adipose tissue tumor necrosis factor and interleukin-6 expression in human obesity and insulin resistance. *Am J Physiol Endocrinol Metab* 2001;280:E745-51.
- 97 Stepan CM, Bailey ST, Bhat S, Brown EJ, Banerjee RR, Wright CM, et al. The hormone resistin links obesity to diabetes. *Nature* 2001;409:307-12.

- 98 Nagaev I, Smith U. Insulin resistance and type 2 diabetes are not related to resistin expression in human fat cells or skeletal muscle. *Biochem Biophys Res Commun* 2001;285:561-4.
- 99 Way JM, Gorgun CZ, Tong Q, Uysal KT, Brown KK, Harrington WW, et al. Adipose tissue resistin expression is severely suppressed in obesity and stimulated by peroxisome proliferator-activated receptor gamma agonists. *J Biol Chem* 2001;276:25651-3.
- 100 Janke J, Engeli S, Gorzelniak K, Luft FC, Sharma AM. Resistin gene expression in human adipocytes is not related to insulin resistance. *Obes Res* 2002;10:1-5.
- 101 Cohen B, Novick D, Rubinstein M. Modulation of insulin activities by leptin. *Science* 1996;274:1185-8.
- 102 Halle M, Berg A, Northoff H, Keul J. Importance of TNF- $\alpha$  and leptin in obesity and insulin resistance: a hypothesis on the impact of physical exercise. *Ex Immunol Rev* 1998;4:77-94.
- 103 Ikejima K, Takei Y, Honda H, Hirose M, Yoshikawa M, Zhang YJ, et al. Leptin receptor-mediated signalling regulates hepatic fibrogenesis and remodelling of extracellular matrix in the rat. *Gastroenterology* 2002;122:1399-410.
- 104 Kubota N, Terauchi Y, Yamauchi T, Kubota T, Moroi M, Matsui J, et al. Disruption of adiponectin causes insulin resistance and neointimal formation. *J Biol Chem* 2002;May 24.
- 105 Day CP, James OFW. Steatohepatitis: a tale of two "hits"? *Gastroenterology* 1998;114:842-5.
- 106 McCullough AJ. Update on nonalcoholic fatty liver disease. *J Clin Gastroenterol* 2002;34:255-62.
- 107 Nieto N, Friedman SL, Cederbaum AI. Stimulation and proliferation of primary rat hepatic stellate cells by cytochrome P450 2E1-derived reactive oxygen species. *Hepatology* 2002;35:62-73.
- 108 Lee, K.S., M. Buck, K. Houghlum, M. Chojkier. Activation of hepatic stellate cells by TGF $\alpha$  and collagen type I is mediated by oxidative stress through c-myc expression. *J Clin Invest* 1995;96:2461-8.
- 109 Bedossa P, Houghlum K, Trautwein C, Holstege A, Chojkier M. Stimulation of collagen alpha 1(I) gene expression is associated with lipid peroxidation in hepatocellular injury: a link to tissue fibrosis? *Hepatology* 1994;19:1262-71.
- 110 Parola M, Pinzani M, Casini A, Albano E, Poli G, Gentilini A, et al. Stimulation of lipid peroxidation or 4-hydroxynonenal treatment increases procollagen alpha 1(I) gene expression in human liver fat-storing cells. *Biochem Biophys Res Com* 1993;194:1044-50.
- 111 Dong W, Simeonova PP, Gallucci R, Matheson J, Fannin R, Montuschi P, et al. Cytokine expression in hepatocytes: role of oxidant stress. *J Interferon Cytokine Res* 1998;18:629-38.
- 112 Burton GW, Ingold KU. Vitamin E application of the principles of physical organic chemistry to the exploration of its structure and function. *Accounts Chem Res* 1986;19:194-201.
- 113 Strauss RS. Comparison of serum concentrations of alpha-tocopherol and beta-carotene in a cross-sectional sample of obese and non-obese children (NHANES III). National Health and Nutrition Examination Survey. *J Pediatr* 1999;134:160-5.
- 114 Leo MA, Rosman AS, Lieber CS. Differential depletion of carotenoids and tocopherol in liver disease. *Hepatology* 1993;17:977-86.
- 115 Letteron P, Fromenty B, Terris B, Degott C, Pessayre D. Acute and chronic hepatic steatosis lead to in vivo lipid peroxidation in mice. *J Hepatol* 1996;24:200-8.
- 116 Nishikawa T, Edelstein D, Du XL, Yamagishi S, Matsumura T, Kaneda Y, et al. Normalizing mitochondrial superoxide production blocks three pathways of hyperglycaemic damage. *Nature* 2000;404:787-90.
- 117 Lieber CS. Cytochrome P-4502E1: its physiological and pathological role. *Physiol Rev* 1997;77:517-44.
- 118 Albano E, Clot P, Morimoto M, Tomasi A, Ingelman-Sundberg M, French SW. Role of cytochrome P4502E1-dependent formation of hydroxyethyl free radical in the development of liver damage in rats intragastrically fed with ethanol. *Hepatology* 1996;23:155-63.
- 119 Woodcroft KJ, Novak RF. Insulin effects on CYP2E1, 2B, 3A, and 4A expression in primary cultured rat hepatocytes. *Chem Biol Interact* 1997;107:75-91.
- 120 Woodcroft KJ, Novak RF. Insulin differentially affects xenobiotic-enhanced, cytochrome P-450 (CYP)2E1, CYP2B, CYP3A, and CYP4A expression in primary cultured rat hepatocytes. *J Pharmacol Exp Ther* 1999;289:1121-7.
- 121 Woodcroft KJ, Hafner MS, Novak RF. Insulin signalling in the transcriptional and posttranscriptional regulation of CYP2E1 expression. *Hepatology* 2002;35:263-73.
- 122 Weltman MD, Farrell GC, Hall P, Ingelman-Sundberg M, Liddle C. Hepatic cytochrome P450 2E1 is increased in patients with nonalcoholic steatohepatitis. *Hepatology* 1998;27:128-33.
- 123 Chitturi S, Weltman M, Farrell GC, McDonald D, Liddle C, Samarasinghe D, et al. HFE Mutations, hepatic iron, and fibrosis: ethnic-specific association of NASH with C282Y but not with fibrotic severity. *Hepatology* 2002;36:142-9.
- 124 Davis RJ, Corvera S, Czech MP. Insulin stimulates cellular iron uptake and causes the redistribution of intracellular transferrin receptors to the plasma membrane. *J Biol Chem* 1986;261:8708-11.
- 125 Ferrannini E. Insulin resistance, iron, and the liver. *Lancet* 2000;355:2181-2.
- 126 Kuhn LC, Hentze MW. Coordination of cellular iron metabolism by post-transcriptional gene regulation. *J Inorg Biochem* 1992;47:183-95.
- 127 Kang JO, Slivka A, Slater G, Cohen G. In vivo formation of hydroxyl radicals following intragastric administration of ferrous salt in rats. *J Inorg Biochem* 1989;35:55-69.
- 128 Britton RS. Metal-induced hepatotoxicity. *Semin Liver Dis* 1996;16:3-12.
- 129 Young SP, Aisen P. The Liver and Iron. In: *The liver: Biology and Pathobiology*. Third Edition, ed. Arias IM, Boyer JL, Fausto N, Jakoby WB, Schachter DA, Shafritz DA. Raven Press, Ltd, New York 1994, pp. 597-617.
- 130 Tsukamoto H. Iron regulation of hepatic macrophage TNF $\alpha$  expression. *Free Rad Biol Med* 2002;32:309-13.
- 131 Drenick EJ, Fislser J, Johnson D. Hepatic steatosis after intestinal bypass - prevention and reversal by metronidazole, irrespective of protein-calorie malnutrition. *Gastroenterology* 1982;82:535-48.
- 132 Lichtman SN, Keku J, Schwab JH, Sartor RB. Hepatic injury associated with small bowel bacterial overgrowth in rats is prevented by metronidazole and tetracycline. *Gastroenterology* 1991;100:513-9.
- 133 Pappo I, Bercovier H, Berry EM, Haviv Y, Gallily R, Freund HR. Polymyxin B reduces total parenteral nutrition-associated hepatic steatosis by its antibacterial activity and by blocking deleterious effects of lipopolysaccharide. *JPEN J Parenter Enteral Nutr* 1992;16:529-32.
- 134 Wigg AJ, Roberts-Thomson IC, Dymock RB, McCarthy PJ, Grose RH, Cummins AG. The role of small intestinal bacterial overgrowth, intestinal permeability, endotoxaemia, and tumour necrosis factor alpha in the pathogenesis of non-alcoholic steatohepatitis. *Gut* 2001;48:206-11.
- 135 Cope K, Risby T, Diehl AM. Increased gastrointestinal ethanol production in obese mice: implications for fatty liver disease pathogenesis. *Gastroenterology* 2000;119:1340-7.
- 136 Oneta CM. The role of Kupffer cells in alcoholic liver disease. In: *Alcohol in health and disease*. Ed. Agarwal DP, Seitz HK. Marcel Dekker, Inc, New York 2001, pp. 407-26.
- 137 Geerts A, DeBleser P, Hautekeete ML, Niki T, Wisse E. Fat-storing (Ito) cell biology. In: *The liver: Biology and Pathobiology*. Third Edition, ed. Arias IM, Boyer JL, Fausto N, Jakoby WB, Schachter DA, Shafritz DA. Raven Press, Ltd, New York 1994, pp. 819-38.
- 138 Gressner AM, Bachem MG. Molecular mechanisms of liver fibrogenesis - a homage to the role of activated fat-storing cells. *Digestion* 1995;56:335-46.
- 139 Seitz HK, Oneta CM. Alkoholische Hepatitis. In: *Klinische Gastroenterologie und Stoffwechsel*. Ed. By Adler G, Beglinger C, Manns MP, Müller-Lissner S, Schmiegel W. Springer Verlag, Heidelberg, 2000, pp. 445-54.
- 140 Washington K, Wright K, Shyr Y, Hunter EB, Olson S, Raiford DS. Hepatic stellate cell activation in non-alcoholic steatohepatitis and fatty liver. *Hum Pathol* 2000;31:822-8.
- 141 Niemelä O, Parkkila S, Juvonen RO, Viitala K, Gelboin HV, Pasanen M. Cytochromes P450 2A6, 2E1, and 3A and production of protein-aldehyde adducts in the liver of patients with alcoholic and non-alcoholic liver diseases. *J Hepatol* 2000;33:893-901.
- 142 Weltman MD, Farrell GC, Liddle C. Increased hepatocyte CYP2E1 expression in a rat nutritional model of hepatic steatosis with inflammation. *Gastroenterology* 1996;111:1645-53.

- 143 MacDonald GA, Bridle KR, Ward PJ, Walker NI, Houghlum K, George DK, et al. Lipid peroxidation in hepatic steatosis in humans is associated with hepatic fibrosis and occurs predominantly in acinar zone 3. *J Gastroenterol Hepatol* 2001; 16:599–606.
- 144 Matsuoka M, Tsukamoto H. Stimulation of hepatic lipocyte collagen production by Kupffer cell-derived transforming growth factor beta: implication for a pathogenetic role in alcoholic liver fibrogenesis. *Hepatology* 1990;112:599–605.
- 145 Wu J, Zern MA. Hepatic stellate cells: a target for the treatment of liver fibrosis. *J Gastroenterol* 2000;35:665–72.
- 146 Casini A, Pinzani M, Milani S, Grappone C, Galli G, Jezequel AM, et al. Regulation of extracellular matrix synthesis by transforming growth factor beta 1 in human fat-storing cells. *Gastroenterology* 1993;105:245–53.
- 147 Hasegawa T, Yoneda M, Nakamura K, Makino I, Terano A. Plasma transforming growth factor- $\alpha$ 1 level and efficacy of  $\alpha$ -tocopherol in patients with non-alcoholic steatohepatitis: a pilot study. *Aliment Pharmacol Ther* 2001;15:1667–72.
- 148 Paradis V, Dargere D, Vidaud M, De Gouvello AC, Huet S, Martinez V, et al. Expression of connective tissue growth factor in experimental rat and human liver fibrosis. *Hepatology* 1999;30:968–76.
- 149 Williams EJ, Gaca MD, Brigstock DR, Arthur MJ, Benyon RC. Increased expression of connective tissue growth factor in fibrotic human liver and in activated hepatic stellate cells. *J Hepatol* 2000;32:754–61.
- 150 Abou-Shady M, Friess H, Zimmermann A, di Mola FF, Guo XZ, Baer HU, et al. Connective tissue growth factor in human liver cirrhosis. *Liver* 2000;20:296–304.
- 151 Franklin TJ. Therapeutic approaches to organ fibrosis. *Int J Biochem Cell Biol* 1997;29:79–89.
- 152 Paradis V, Perlemuter G, Bonvoust F, Dargere D, Parfait B, Vidaud M, et al. High glucose and hyperinsulinemia stimulate connective tissue growth factor expression: a potential mechanism involved in progression to fibrosis in nonalcoholic steatohepatitis. *Hepatology* 2001;34:738–44.
- 153 Liu X, Wu H, Liu F, Huang M, Qiang O, Huang S. Effects of tumor necrosis factor alpha on the expression of connective tissue growth factor in hepatic stellate cells *Zhonghua Gan Zang Bing Za Zhi* 2001;9 Suppl: 15–7 [Abstract].
- 154 Marra F. Leptin and liver fibrosis: a matter of fat. *Gastroenterology* 2002;122:1529–32.
- 155 Goodpaster BH, Kelley DE, Wing RR, Meier A, Thaete FL. Effects of weight loss on regional fat distribution and insulin sensitivity in obesity. *Diabetes* 1999;48:839–47.
- 156 Scheen AJ. Aggressive weight reduction treatment in the management of type 2 diabetes. *Diabetes Metab* 1998;24: 116–23.
- 157 Franssila-Kallunki A, Rissanen A, Ekstrand A, Ollus A, Groop L. Effects of weight loss on substrate oxidation, energy expenditure, and insulin sensitivity in obese individuals. *Am J Clin Nutr* 1992;55:356–61.
- 158 Franssila-Kallunki A, Rissanen A, Ekstrand A, Ollus A, Groop L. Weight loss by very-low-calorie diets: effects on substrate oxidation, energy expenditure, and insulin sensitivity in obese subjects. *Am J Clin Nutr* 1992;56(Suppl 1):247S–248S.
- 159 Rosenfalck AM, Hendel H, Rasmussen MH, Almdal T, Anderson T, Hilsted J, Madsbad S. Minor long-term changes in weight have beneficial effects on insulin sensitivity and beta-cell function in obese subjects. *Diabetes Obes Metab* 2002; 4:19–28.
- 160 Greco AV, Mingrone G, Giancaterini A, Manco M, Morrioni M, Cinti S, et al. Insulin resistance in morbid obesity: reversal with intramyocellular fat depletion. *Diabetes* 2002;51:144–51.
- 161 Bosello O, Armellini F, Zamboni M, Fitchet M. The benefits of modest weight loss in type II diabetes. *Int J Obes Relat Metab Disord* 1997;21(Suppl 1): S10–3.
- 162 Eriksson S, Eriksson KF and Bondesson L. Non-alcoholic steatohepatitis in obesity: a reversible condition. *Acta Med Scand* 1986;220:83–8.
- 163 Palmer M, Schaffner F. Effect of weight reduction on hepatic abnormalities in overweight patients. *Gastroenterology* 1990;99:1408–13.
- 164 Geloneze B, Tambascia MA, Pareja JC, Repetto EM, Magna LA. The insulin tolerance test in morbidly obese patients undergoing bariatric surgery. *Obes Res* 2001;9:763–9.
- 165 Letiexhe MR, Scheen AJ, Gerard PL, Desai C, Lefebvre PJ. Insulin secretion, clearance and action before and after gastroplasty in severely obese subjects. *Int J Obes Relat Metab Disord* 1994;18:295–300.
- 166 Dixon JB, O'Brien PE. Health outcomes of severely obese type 2 diabetic subjects 1 year after laparoscopic adjustable gastric banding. *Diabetes Care* 2002;25:358–63.
- 167 Ranlov I, Hardt F. Regression of liver steatosis following gastroplasty or gastric bypass for morbid obesity. *Digestion* 1990; 47:208–14.
- 168 Silverman EM, Sapala JA and Appelman HD. Regression of hepatic steatosis in morbidly obese persons after gastric bypass. *Am J Clin Pathol* 1995;104:23–31.
- 169 O'Leary J. Liver failure after jejunoileal bypass: an appraisal. *Int J Obes* 1981;5:531–5.
- 170 Baker AL, Elson CO, Jaskan J and Boyer JL. Liver failure with steatonecrosis after jejunoileal bypass: recovery with parenteral nutrition and re-anastomosis. *Arch Intern Med* 1979; 139:289–92.
- 171 Ryan AS. Insulin resistance with aging: effects of diet and exercise. *Sports Med* 2000;30:327–46.
- 172 Hughes VA, Fiatarone MA, Fielding RA, Kahn BB, Ferrara CM, et al. Exercise increases muscle GLUT-4 levels and insulin action in subjects with impaired glucose tolerance. *Am J Physiol* 1993;264:E855–62.
- 173 Stumvoll M, Nurjhan N, Perriello G, Dailey G, Gerich JE. Metabolic effects of metformin in non-insulin-dependent diabetes mellitus. *N Engl J Med* 1995;333:550–4.
- 174 Coyle WJ, Delaney N, Yoshibashi A, et al. Metformin treatment in patients with non-alcoholic steatohepatitis normalizes LFTs and improves histology [abstract]. *Gastroenterology* 1999;116:1198.
- 175 Marchesini G, Brizi M, Bianchi G, Tomassetti S, Zoli M, Melchionda N. Metformin in non-alcoholic steatohepatitis. *Lancet* 2001;358:893–4.
- 176 Phillips PJ, Scicchitano R, Clarkson AR, Gilmore HR. Metformin associated lactic acidosis. *Aust N Z J Med* 1978;8: 281–4.
- 177 Sulkin TV, Bosman D, Krentz AJ. Contraindications to metformin therapy in patients with NIDDM. *Diabetes Care* 1997; 20:925–8.
- 178 Krentz AJ. Non-alcoholic steatohepatitis. *Lancet* 1999;354: 1300.
- 179 Urso R, Visco-Comandini U. Metformin in non-alcoholic steatohepatitis. *Lancet* 2002;359:355–6.
- 180 Babich MM, Pike I, Shiffman ML. Metformin-induced acute hepatitis. *Am J Med* 1998;104:490–2.
- 181 Swislocki AL, Noth R. Case report. Pseudohepatotoxicity of metformin. *Diabetes Care* 1998;21:677–8.
- 182 Komers R, Vrana A. Thiazolidinediones – tools for the research of metabolic syndrome X. *Physiol Res* 1998;47:215–25.
- 183 Saltiel AR. New perspectives into the molecular pathogenesis and treatment of type 2 diabetes. *Cell* 2001;104:517–29.
- 184 Hauner H. The mode of action of thiazolidinediones. *Diabetes Metab Res Rev* 2002;18:S10–S15.
- 185 Hube F, Hauner H. The two tumor necrosis factor receptors mediate opposite effects on differentiation and glucose metabolism in human adipocytes in primary culture. *Endocrinology* 2000;141:2582–8.
- 186 Hotamisligil GS, Spiegelman BM. Tumor necrosis factor alpha: a key component of the obesity-diabetes link. *Diabetes* 1994;43:1271–8.
- 187 Gitlin N, Julie NL, Spurr CL, Lim KN, Juarbe HM. Two cases of severe clinical and histologic hepatotoxicity associated with troglitazone. *Ann Intern Med* 1998;129:36–8.
- 188 Shibuya A, Watanabe M, Fujita Y, Saigenji K, Kuwao S, Takahashi H, et al. An autopsy case of troglitazone-induced fulminant hepatitis. *Diabetes Care* 1998;21:2140–3.
- 189 Kohloser J, Mathai J, Reichheld J, Banner BF, Bonkovsky HL. Hepatotoxicity due to troglitazone: report of two cases and review of adverse events reported to the United States Food and Drug Administration. *Am J Gastroenterol* 2000; 95:272–6.
- 190 Schiano T, Dolehide K, Hart J, Baker AL. Severe but reversible hepatitis induced by troglitazone. *Dig Dis Sci* 2000; 45:1039–42.
- 191 Li H, Heller DS, Leevy CB, Zierer KG, Klein KM. Troglitazone-induced fulminant hepatitis: report of a case with autopsy findings. *J Diabetes Complications* 2000;14:175–7.
- 192 Menon KVN, Angulo P, Lindor KD. Severe cholestatic hepatitis from troglitazone in a patient with nonalcoholic steatohepatitis and diabetes mellitus. *Am J Gastroenterol* 2001;96: 1631–4.
- 193 Scheen AJ. Hepatotoxicity with thiazolidinediones; is it a class effect? *Drug Saf* 2001;24:873–88.

- 194 Forman LM, Simmons DA, Diamond RH. Hepatic failure in a patient taking rosiglitazone. *Ann Intern Med* 2000;132:118-21.
- 195 Al-Salman J, Arjomand H, Kemp DG, Mittal M. Hepatocellular injury in a patient receiving rosiglitazone. A case report. *Ann Intern Med* 2000;132:121-4.
- 196 Maeda K. Hepatocellular injury in a patient receiving pioglitazone [Letter]. *Ann Intern Med* 2001;135:306.
- 197 May LD, Lefkowitz JH, Kram MT, Rubin DE. Mixed hepatocellular-cholestatic liver injury after pioglitazone therapy. *Ann Intern Med* 2002;136:449-52.
- 198 Caldwell SH, Hespeneheide EE, Redick JA, Lezzoni JC, Battle EH, Sheppard BL. A pilot study of a thiazolidinedione, troglitazone, in nonalcoholic steatohepatitis. *Am J Gastroenterol* 2001;96:519-25.
- 199 Lebovitz HE, Kreider M, Freed MI. Evaluation of Liver Function in Type 2 Diabetic Patients During Clinical Trials: Evidence that rosiglitazone does not cause hepatic dysfunction. *Diabetes Care* 2002;25:815-21.
- 200 Mingrone G, DeGaetano A, Greco AV, Capristo E, Benedetti G, Castagneto M, et al. Reversibility of insulin resistance in obese diabetic patients: role of plasma lipids. *Diabetologia* 1997;40:599-605.
- 201 Unger RH. Lipotoxic diseases. *Rev Ann Med* 2002;53:319-36.
- 202 Basaranoglu M, Acbay O, Sonsuz A. A controlled trial of gemfibrozil in the treatment of patients with nonalcoholic steatohepatitis. *J Hepatol* 1999;31:384.
- 203 Saibara T, Onishi S, Ogawa Y, Yoshida S, Enzan H. Bezafibrate for tamoxifen-induced non-alcoholic steatohepatitis. *Lancet* 1999;353:1802.
- 204 Pierce EH, Chesler DL. Possible association of granulomatous hepatitis with clofibrate therapy. *N Engl J Med* 1978;299:314.
- 205 Migneco G, Mascarella A, La Ferla A, Attianese R. Clofibrate hepatitis. A case report. *Minerva Med* 1986;77:799-800.
- 206 Valmalle R, Bacq Y, Furet Y, Dorval E, Barbieux JP, Metman EH. Fatal acute hepatitis during treatment with perhexiline maleate and bezafibrate. *Gastroenterol Clin Biol* 1989;13:530-1.
- 207 Gendreau-Tranquart C, Barbieux JP, Gillion JM, Furet Y, Picon L, Dorval ED, et al. A case of hepatitis caused by xifone and bezafibrate. *Gastroenterol Clin Biol* 1989;13:427.
- 208 Bonkovsky HL. Iron as a comorbid factor in chronic viral hepatitis. Iron deficiency and iron overload. *Am J Gastroenterol* 2002;97:1-4.
- 209 Kang JO. Chronic iron overload and toxicity: clinical chemistry perspective. *Clin Lab Sci* 2001;14:209-19.
- 210 Bendich A, Machlin LJ. Safety of oral intake of vitamin E. *American Journal of Clinical Nutrition* 1988;48:612-9.
- 211 Pryor WA. Vitamin E and heart disease: basic science to clinical intervention trials. *Free Radic Biol Med* 2000;28:141-64.
- 212 Lavine JE. Vitamin E treatment of non-alcoholic steatohepatitis in children: a pilot study. *J Pediatr* 2000;136:734-8.
- 213 Hasegawa T, Yoneda M, Kakamura K, Yokohama S, Tamori K, Sato Y. Diagnostic significance of measurement of serum transforming growth factor beta1 level and effect of alpha-tocopherol in patients with non-alcoholic steatohepatitis. *Gastroenterology* 1997;112:A1278.
- 214 Best CH, Ridout JH, Lucas CC. Alleviation of dietary cirrhosis with betaine and other lipotropic agents. *Can J Physiol Pharmacol* 1969;47:73-9.
- 215 Neuschwander-Tetri BA. Betaine: An old therapy for a new scourge. *Am J Gastroenterol* 2001;96:2534-6.
- 216 Abdelmalek MF, Angulo P, Jorgensen RA, Sylvestre PB, Lindor KD. Betaine, a promising new agent for patients with non-alcoholic steatohepatitis: results of a pilot study. *Am J Gastroenterol* 2001;96:2711-7.
- 217 Oneta CM, Pöschl G, Seitz HK. Therapy of alcoholic liver disease. In: *Acute and chronic liver diseases: Molecular biology and clinics*. Ed. by Schmid R, Bianchi L, Blum HE, Gerok W, Maier KP, Stalder GA. Falk Symposium 87. Kluwer Academic Publishers. Dordrecht, pp. 126-36.
- 218 Salmi HA, Sarna S. Effect of silymarin on chemical, functional and morphological alterations of the liver. A double blind controlled study. *Scand J Gastroenterol* 1982;17:517-21.
- 219 Ferenci P, Dragosics B, Dittrich H, Frank H, Benda L, Lochs H, et al. Randomized controlled trial of silymarin treatment in patients with cirrhosis of the liver. *J Hepatol* 1989;9:105-13.
- 220 Velussi M, Cernigoj AM, Viezolli L, Dapas F, Caffau C, Zilli M. Silymarin reduces hyperinsulinemia, malondialdehyde levels and daily insulin need in cirrhotic diabetes patients. *Current Ther Res* 1993;53:533-45.
- 221 Velussi M, Cernigoj AM, De Monte A, Dapas F, Caffau C, Zilli M. Long-term (12 months) treatment with an antioxidant drug (silymarin) is effective on hyperinsulinemia, exogenous insulin need and malondialdehyde levels in cirrhotic diabetic patients. *J Hepatol* 1997;26:871-9.
- 222 Pares A, Planas R, Torres M, Caballeria J, Viver JM, Acero D, et al. Effects of silymarin in alcoholic patients with cirrhosis of the liver: results of a controlled, double-blind, randomized and multicenter trial. *J Hepatol* 1997;26:871-9.
- 223 Lieber CS. Hepatic, metabolic, and nutritional disorders of Alcoholism. From pathogenesis to therapy. In: *Alcohol in health and disease*. Ed. Agarwal DP, Seitz HK. Marcel Dekker, Inc, New York 2001, pp. 335-68.
- 224 Guma C, Bviola L, Thome M, Galdame O, Albarez E. Ursodeoxycholic acid in the treatment of non-alcoholic steatohepatitis: results of a prospective clinical controlled trial [abstract]. *Hepatology* 1997;26:3887A.
- 225 Ceriani R, Bunati S, Morini L, et al. Effect of ursodeoxycholic acid plus diet in patients with non-alcoholic steatohepatitis [abstract]. *Hepatology* 1998;28:386A.
- 226 Vajro P, Francese A, Valerio G, Iannucci MP, Aragione N. Lack of efficacy of ursodeoxycholic acid for the treatment of liver abnormalities in obese children. *J Pediatr* 2000;136:739-43.
- 227 Stiehl A, Benz C, Sauer P. Mechanism of hepatoprotective action of bile salts in liver disease. *Gastroenterol Clin North Am* 1999;28:195-209.
- 228 Charlton M, Kasparova P, Weston S, Lindor K, Maor-Kendler Y, Wiesner RH, et al. Frequency of non-alcoholic steatohepatitis as a cause of advanced liver disease. *Liver Transpl* 2001;7:608-14.
- 229 Kim WR, Poterucha JJ, Porayko MK, Dickerson ER, Steers JL, Wiesner RH. Recurrence of non-alcoholic steatohepatitis following liver transplantation. *Transplantation* 1996;62:1802-5.
- 230 Contos MJ, Cales W, Sterling RK, Luketic VA, Shiffman ML, Mills AS, et al. Development of non-alcoholic fatty liver disease after orthoptic liver transplantation for cryptogenic cirrhosis. *Liver Transpl* 2001;7:363-73.
- 231 Yu AS, Keefe EB. NADLF and NASH: important diseases before and after liver transplantation. *Hepatology* 2001;34:842-3.

## The many reasons why you should choose SMW to publish your research

### What Swiss Medical Weekly has to offer:

- SMW's impact factor has been steadily rising, to the current 1.537
- Open access to the publication via the Internet, therefore wide audience and impact
- Rapid listing in Medline
- LinkOut-button from PubMed with link to the full text website <http://www.smw.ch> (direct link from each SMW record in PubMed)
- No-nonsense submission – you submit a single copy of your manuscript by e-mail attachment
- Peer review based on a broad spectrum of international academic referees
- Assistance of our professional statistician for every article with statistical analyses
- Fast peer review, by e-mail exchange with the referees
- Prompt decisions based on weekly conferences of the Editorial Board
- Prompt notification on the status of your manuscript by e-mail
- Professional English copy editing
- No page charges and attractive colour offprints at no extra cost

### Editorial Board

Prof. Jean-Michel Dayer, Geneva  
 Prof. Peter Gehr, Berne  
 Prof. André P. Perruchoud, Basel  
 Prof. Andreas Schaffner, Zurich  
 (Editor in chief)  
 Prof. Werner Straub, Berne  
 Prof. Ludwig von Segesser, Lausanne

### International Advisory Committee

Prof. K. E. Juhani Airaksinen, Turku, Finland  
 Prof. Anthony Bayes de Luna, Barcelona, Spain  
 Prof. Hubert E. Blum, Freiburg, Germany  
 Prof. Walter E. Haefeli, Heidelberg, Germany  
 Prof. Nino Kuenzli, Los Angeles, USA  
 Prof. René Lutter, Amsterdam,  
 The Netherlands  
 Prof. Claude Martin, Marseille, France  
 Prof. Josef Patsch, Innsbruck, Austria  
 Prof. Luigi Tavazzi, Pavia, Italy

We evaluate manuscripts of broad clinical interest from all specialities, including experimental medicine and clinical investigation.

We look forward to receiving your paper!

Guidelines for authors:

[http://www.smw.ch/set\\_authors.html](http://www.smw.ch/set_authors.html)

### Impact factor Swiss Medical Weekly



All manuscripts should be sent in electronic form, to:

EMH Swiss Medical Publishers Ltd.  
 SMW Editorial Secretariat  
 Farnsburgerstrasse 8  
 CH-4132 Muttenz

Manuscripts: [submission@smw.ch](mailto:submission@smw.ch)  
 Letters to the editor: [letters@smw.ch](mailto:letters@smw.ch)  
 Editorial Board: [red@smw.ch](mailto:red@smw.ch)  
 Internet: <http://www.smw.ch>