

# Associated vascular lesions in patients with spontaneous coronary artery dissection

Stefan Toggweiler<sup>a</sup>, Marietta Puck<sup>a</sup>, Christoph Thalhammer<sup>b</sup>, Robert Manka<sup>a,c</sup>, Michael Wyss<sup>c</sup>, Deniz Bilecen<sup>d</sup>, Roberto Corti<sup>a</sup>, Beatrice R. Amann-Vesti<sup>b</sup>, Thomas F. Lüscher<sup>a</sup>, Christophe A. Wyss<sup>a</sup>

<sup>a</sup> Cardiovascular Center, Cardiology, University Hospital Zurich, Switzerland

<sup>b</sup> Cardiovascular Center, Angiology, University Hospital Zurich, Switzerland

<sup>c</sup> Institute for Biomedical Engineering, University Hospital Zurich, Switzerland

<sup>d</sup> University Hospital Bruderholz, Switzerland

## Summary

**AIM:** To identify vascular abnormalities in patients presenting with spontaneous coronary artery dissection (SCAD).

**METHODS:** We performed a whole-body MR angiography and a duplex sonography of the renal and carotid arteries in 12 patients (9 women, 3 men) with SCAD to identify vascular abnormalities.

**RESULTS:** MR angiography revealed abnormalities of the renal arteries in 3/12 patients (25%). All 3 patients were women, 2 presented with changes suggesting fibromuscular dysplasia (FMD), 1 had a spontaneous renal artery dissection. No other vascular abnormalities were identified in any of the patients. Duplex sonography confirmed MR findings and showed non-significant renal artery stenoses in both patients with FMD.

**CONCLUSIONS:** Abnormalities of the renal arteries were found in 3/12 (25%) of the patients with SCAD. No other vascular abnormalities were identified. Additional diagnostic tests of the renal arteries such as renal artery angiography or duplex sonography may be considered in patients presenting with SCAD.

**Key words:** dissection; fibromuscular dysplasia; acute coronary syndromes; women; myocardial infarction.

## Introduction

Spontaneous coronary artery dissection (SCAD) occurs typically in younger women with otherwise low cardiovascular risk [1–5].

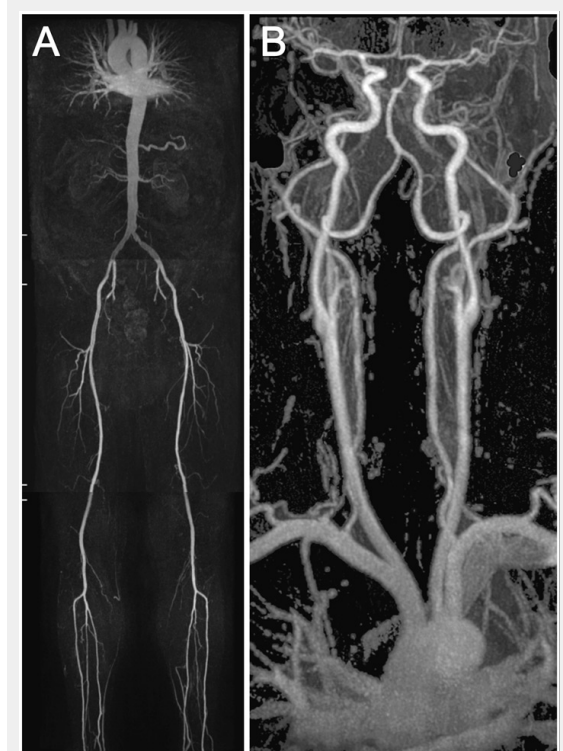The etiology of SCAD remains unclear. Vigorous exercise, vasospasm, coronary artery ectasy, oral contraceptives/hormones, cocaine and cyclosporine have been associated with the condition. Finally, an association of SCAD and fibromuscular dysplasia (FMD) has been suggested [6].

As of now, no study has investigated whether patients with SCAD also present with abnormalities in vessels other than the coronaries. The aim of this study was to investigate

whether patients presenting with spontaneous coronary artery dissections (SCAD) have lesions in other vessels than the coronaries thus reflecting a systemic disease.

## Methods

**Patient population and study protocol.** The University Hospital Zurich is a tertiary referral clinic treating about 500 acute coronary syndromes (ACS, i.e., unstable angina pectoris and acute myocardial infarction) each year. Between



**Figure 1**

An example showing the MR whole body angiography. The first part of the MR whole body angiography included thoracic/renal-, pelvis/thigh-, knee/calf-stations (A). The second part included the thoracic/carotid-station (B).

January 2003 and December 2009, we identified a total of 24 patients who presented consecutively at the cardiac catheterisation laboratory with SCAD as the cause of ACS which represented 0.7% of all ACS seen at our institution. Patients with SCAD and relevant atherosclerotic coronary artery disease were excluded since dissection may be a manifestation of a plaque rupture.

Out of these 24 patients, one patient had to be excluded due to an implanted ICD which is a contraindication for MR tomography. Two patients died after hospital admission and could not be investigated. Two were living abroad, four were not reachable and five refused to participate in the study. The remaining 12 patients were included in the study. All patients were examined utilising whole-body MR angiography and duplex sonography of the carotid and renal arteries. Clinical and medical history of the index event was taken utilising a questionnaire. The study was approved by the local ethics committee and all included patients provided written informed consent.

### MR whole-body angiography

All MR angiography (MRA) examinations were performed on a 1.5-T whole-body MR system (Philips Achieva, Release 2.6, Philips Healthcare, Best, the Netherlands) with a gradient strength of 30 mT/m and a slew rate of 150 (mT/m/msec) according to previously described protocols [7, 8]. The scanning protocol involved a 2 step approach. The first part of the examination was in feet first, supine position, for the renal arteries down to the calf arteries with automatic table movement between the stations, using a 12-element phased-array peripheral vascular coil (Philips Healthcare). A biphasic intravenous administration of gadobenate dimeglumine with 0.15 mmol per kilogram of body weight at flow rates of 2.0 ml/sec followed by 0.033 mmol per kilogram of body weight at flow rates of 0.9 ml/sec, followed by a 30 mL saline flush at a flow rate of 0.8 ml/sec (fig. 1A). In the second part of the examination a 16 -element phased-array Neurovascular coil (Philips Healthcare) was used for the carotid and thoracic arteries in head first and supine position. An intravenous administration of gadobenate dimeglumine with 0.15 mmol per kilogram of body weight at flow rates of 1.5 ml/sec followed by a 30 ml saline flush at a flow rate of 1.5 ml/sec (fig. 1B). The angiograms were analysed by a board-certified radiologist (DB) and a skilled vascular specialist (CT) independently, in case of differing findings an additional consensus reading was performed.

### Duplex sonography

In all patients, colour coded duplex ultrasound of the extracranial cerebral arteries and the renal artery was performed. A high-end ultrasound machine (iU22, Philips Healthcare) with a linear 9–3 MHz or 17–5 MHz (carotid artery) and a curved 5–1 MHz (renal artery) transducer was used by an experienced investigator (CT). All vessels were examined using B-mode ultrasound, colour Doppler imaging and Doppler spectral analysis. Examination of the extracranial cerebral arteries included the common, external and internal carotid artery, as well as the vertebral and subclavian artery. Intima media thickness of both common carotid arteries was measured using an integrated quantification soft-

ware package of the ultrasound machine (QLAB, Philips Healthcare) [9]. IMT was analysed over a vessel length of 10 mm and reported as mean millimeters and technical success [%] as a quality control. Investigation of the renal perfusion included Doppler spectral analysis in different areas of the renal artery and the documentation of the intrarenal perfusion including measuring the resistive index in three areas of the renal parenchyma (upper pole, middle, lower pole). A significant (>70%) stenosis of the renal artery was excluded with a peak systolic velocity lower than 200 cm/s or a renal aortal ratio lower than 2.5 [10].

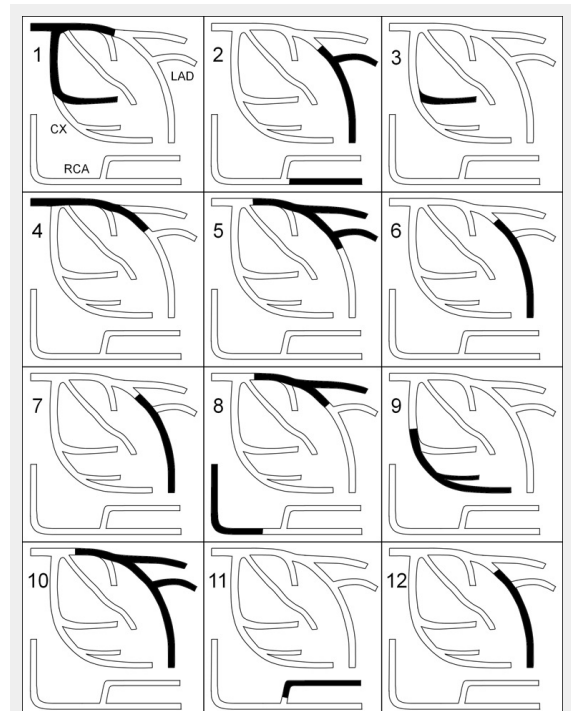
### Statistical analysis

Continuous variables with a normal distribution are described as means with standard deviations. Discrete variables are presented as frequencies and percentages.

## Results

### Patient characteristics

A total of 12 patients with SCAD were investigated, 9 (75%) women, mean age at the time of SCAD was  $48 \pm 10$  years (range: 35 to 65 years). Patients presented with ST elevation myocardial infarction (STEMI,  $n = 8$ ) or Non-STEMI (NSTEMI,  $n = 4$ ). All patients had chest pain at rest, all but one had an elevated Troponin. Possible risk factors for SCAD were present in 5 patients: sport or exercise during the same day in 3, pregnancy within 6 month in 2, a positive family history for dissections in 2. Baseline characteristics are presented in table 1.



**Figure 2**

Segmental distribution of coronary artery dissections in patients with (1–3) and without (4–12) renal artery abnormalities.

### Coronary angiography and treatment

As shown in table 2 and figure 2, multivessel involvement was present in 3 (25%). All patients presented with typical findings of SCAD such as distal, long lesions, abrupt demarcation from normal proximal segments, double lumen, spiral lucency and contrast staining. Initial treatment was conservative in 7 (58%) patients, balloon dilatation was performed in 2 (17%) and balloon dilatation with stent implantation in the remaining 3 (25%). An intra-aortal balloon pump (IABP) was inserted in 3 (25%) patients. One patient subsequently required surgical revascularisation with coronary artery bypass grafting. Median length of hospital stay was 6 days ranging from 2 to 17 days. After a follow-up of 444 and 782 days, 2 (17%) patients had a recurrent coronary artery dissection in a different vascular territory.

### MR whole body angiography

MRA and duplex sonography were performed after a median of 1,036 (range: 78–1938) days after the SCAD. Abnormalities of the renal arteries were found in 3/12 (25%, table 2), all were women. Two patients showed a transverse striated “string of beads” angiographic appearance of the renal artery, consistent with fibromuscular dysplasia (fig. 3, patients 1 and 2). In 1 patient an ostial dissection of the left renal artery without a significant stenosis was found (fig. 3,

patient 3). MRA of the extracranial arteries was normal in all patients.

### Duplex sonography

Pathologic findings of the renal artery were found in 2 patients (table 2). A <70% stenosis of the middle part (peak systolic velocity of 210 cm/s) of the right renal artery was observed in a 63 year old woman and a <50% stenosis (peak systolic velocity of 130 cm/s) in a 40 year old woman (fig. 3, patients 1 and 2). Discrete wall thickening of the carotid bulb was found in 3 patients, all other carotid arteries were normal. Intima media thickness was  $0.54 \pm 0.15$  on the right side and  $0.55 \pm 0.12$  on the left side. No dissections were identified by Duplex sonography.

### Discussion

To our knowledge, this is the first study to investigate associated vascular lesions in patients with spontaneous coronary artery dissection using whole-body MR angiography and duplex sonography. We were able to identify abnormalities of the renal arteries in 3/12 (25%) patients, all women. MRA suggested fibro-muscular dysplasia of the renal arteries in 2 and a spontaneous dissection of the renal artery in 1 patient. Two of the 3 patients with renal artery abnormalities presented with multivessel dissections. Spontaneous dissection of the renal arteries is a common presenta-

**Table 1:** Baseline characteristics in patients with (1–3) and without (4–12) renal artery abnormalities.

Nr	Age years	Sex	HTN	Risk factors	Clinical presentation	BP Sys/Dia	Leuk	CRP	Peak CK	LV-EF
1	63	F	Yes	None	STEMI	92/59	11.6	21	3,120	52
2	40	F	Yes	Pregnancy, Sport	NSTEMI	140/91	12.0	156	128	65
3	55	F	Yes	None	STEMI	92/63	13.4	2	545	60
4	49	M	No	positive FH	NSTEMI	104/52	9.5	20	73	70
5	39	M	No	Sport	STEMI	100/70	6.6	3	1,837	38
6	51	F	No	None	STEMI	109/58	14.4	<1	2,293	50
7	40	F	No	Positive FH	STEMI	108/74	10.1	<1	1,041	57
8	65	M	No	None	STEMI	100/51	8.3	13	412	71
9	40	F	Yes	None	NSTEMI	142/88	7.8	11	286	75
10	35	F	No	Pregnancy, Sport	STEMI	100/76	12.0	7	620	50
11	54	F	Yes	None	NSTEMI	183/97	6.4	<1	513	55
12	47	F	No	None	STEMI	124/69	7.7	2	249	55

HTN: hypertension; BP: blood pressure in mm Hg; Leuk: Leukocyte count \*10<sup>9</sup>; CRP: C reactive protein in mg/l; CK: creatinine kinase; LV-EF: left-ventricular ejection fraction in %; STEMI: ST elevation myocardial infarction; NSTEMI: non-ST elevation myocardial infarction.

**Table 2:** Treatment, outcome, MR and duplex findings in patients with (1–3) and without (4–12) renal artery abnormalities.

Nr	Culprit	Angiographic findings	Initial treatment	Outcome	MR findings	Duplex findings
1	PL/CX	Spiral lesion, contrast staining	DES	Uncomplicated	Bilat RA FMD	Stenosis right RA
2	PDA	Two distal lesions with double lumen	Med	Recurrent dissection	Right RA FMD	Stenosis right RA
3	PL/CX	Distal spiral lesion, contrast staining	Med	Uncomplicated	Left RA Dissection	Normal
4	LM	Long spiral lesion with double lumen	Med	Uncomplicated	Normal	Normal
5	Prox LAD	Long lesion with contrast staining	Med	Recurrent dissection	Normal	Normal
6	Mid LAD	Long distal spiral lesion, contrast staining	DES	Uncomplicated	Normal	Normal
7	Mid LAD	Long distal spiral lesion, contrast staining	Med	Uncomplicated	Normal	Normal
8	Prox LAD	Abrupt long lesions with double lumen	DES	Uncomplicated	Normal	Normal
9	Mid CX	Distal spiral lesion with staining	POBA	Uncomplicated	Normal	Normal
10	Prox LAD	Abrupt long lesion with contrast staining	Med	Required ACBP	Normal	Normal
11	PL/RCA	Long distal spiral lesion	Med	Uncomplicated	Normal	Normal
12	Mid LAD	Long lesion with abrupt demarcation	POBA	Uncomplicated	Normal	Normal

PL: posterolateral branch; CX: circumflex; PDA: posterior descending artery; LM: left main; LAD: left anterior descending; RCA: right coronary artery; DES: drug eluting stent; Med: medical treatment; POBA: balloon angioplasty; FMD: fibromuscular dysplasia; RA: renal artery; bilat: bilateral.

tion of FMD [11, 12] suggesting that renal artery changes as they occur in FMD were found in all 3 patients with vascular abnormalities. No other relevant vascular abnormalities were found.

### Comparison with previous studies

The prevalence of FMD in the general population is not precisely known. Five reports on angiographic findings in a total of 5138 potential kidney donors found 194 subjects (3.8%) with evidence of renovascular FMD [13–17]. In our study, 25% of the patients with SCAD had changes suggestive of FMD (95% Wilson-confidence interval 9–53%). Although this is a small study, these data suggest that SCAD may be caused by renal artery FMD in some patients.

Spontaneous coronary dissection is a rare form of ACS. In our hospital, 0.7% of all ACS were identified to be due to SCAD. In another report by Mortensen et al., the incidence of SCAD among patients with ACS was 0.2% [18]. Early mortality in such patients is usually high [19]. Case reports of patients with SCAD and FMD have previously been published [20, 21]. One report by Pate et al. included seven women with documented medial pattern of renal FMD and acute coronary syndromes [6]. These patients presented with coronary stenoses in which the proximal vessel appeared normal but in the middle or distal segment there was an abrupt transition to diffuse obliterative disease.

### Clinical implications

According to the findings of our study, a diagnostic study such as MR angiography, Duplex sonography, renal artery angiography or an aortogram of the renal and visceral segments following coronary angiography in patients presenting with SCAD may be considered to identify possible ab-

normalities of the renal arteries. A better understanding of diseases that may cause SCAD (e.g., FMD) may help in initial risk stratification at presentation, acute treatment and long-term counselling of these often very unsettled patients.

### Limitations

Due to the low prevalence of the disease investigated, the number of patients included in this study is small. Most of the MR- and colour-Doppler examinations were carried out late after the SCAD, and it is possible that we did not detect transient vascular abnormalities. The study did not include a matched control group of healthy individuals.

### Conclusions

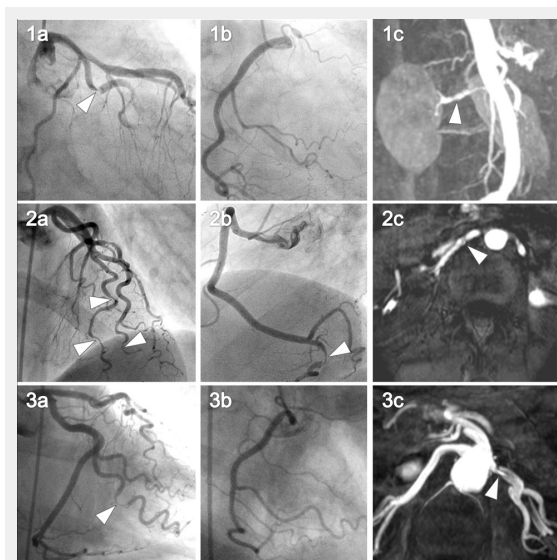
Abnormalities of the renal arteries were found in 3/12 (25%) of the patients with SCAD. No other vascular abnormalities were identified. Additional diagnostic tests of the renal arteries such as MR angiography, duplex sonography or angiography should be considered in patients presenting with SCAD.

**Funding / potential competing interests:** Dr. Toggweiler is supported by a grant of the Swiss National Foundation.

**Correspondence:** Christophe Wyss, MD, Cardiovascular Center, Cardiology, University Hospital Zurich, Raemistrasse 100, CH-8091 Zurich, Switzerland, [christophe.wyss\[at\]usz.ch](mailto:christophe.wyss[at]usz.ch)

### References

- 1 Leone F, Macchiusi A, Ricci R, Cerquetani E, Reynaud M. Acute myocardial infarction from spontaneous coronary artery dissection: a case report and review of the literature. *Cardiol Rev.* 2004;12:3–9.
- 2 Mahenthiran J, Revankar R, Koka V, Hoo J, Shenoy M. Spontaneous coronary artery dissection presenting as acute myocardial infarction. *J Natl Med Assoc.* 2000;92:87–90.
- 3 DeMaio SJ, Jr., Kinsella SH, Silverman ME. Clinical course and long-term prognosis of spontaneous coronary artery dissection. *Am J Cardiol.* 1989;64:471–4.
- 4 Bac DJ, Lotgering FK, Verkaaik AP, Deckers JW. Spontaneous coronary artery dissection during pregnancy and post partum. *Eur Heart J.* 1995;16:136–8.
- 5 Jorgensen MB, Aharonian V, Mansukhani P, Mahrer PR. Spontaneous coronary dissection: a cluster of cases with this rare finding. *Am Heart J.* 1994;127:1382–7.
- 6 Pate GE, Lowe R, Buller CE. Fibromuscular dysplasia of the coronary and renal arteries? *Catheter Cardiovasc Interv.* 2005;64:138–45.
- 7 Wyttenbach R, Braghetti A, Wyss M, Alerci M, Briner L, Santini P, et al. Renal artery assessment with nonenhanced steady-state free precession versus contrast-enhanced MR angiography. *Radiology.* 2007;245:186–95.
- 8 Willinek WA, Gieseke J, Conrad R, Strunk H, Hoogeveen R, von Falkenhausen M, et al. Randomly segmented central k-space ordering in high-spatial-resolution contrast-enhanced MR angiography of the supraaortic arteries: initial experience. *Radiology.* 2002;225:583–8.
- 9 Lim TK, Lim E, Dwivedi G, Kooner J, Senior R. Normal value of carotid intima-media thickness – a surrogate marker of atherosclerosis: quantitative assessment by B-mode carotid ultrasound. *J Am Soc Echocardiogr.* 2008;21:112–6.
- 10 Staub D, Canevascini R, Huegli RW, Aschwanden M, Thalhammer C, Imfeld S, et al. Best duplex-sonographic criteria for the assessment of renal artery stenosis – correlation with intra-arterial pressure gradient. *Ultraschall Med.* 2007;28:45–51.



**Figure 3**

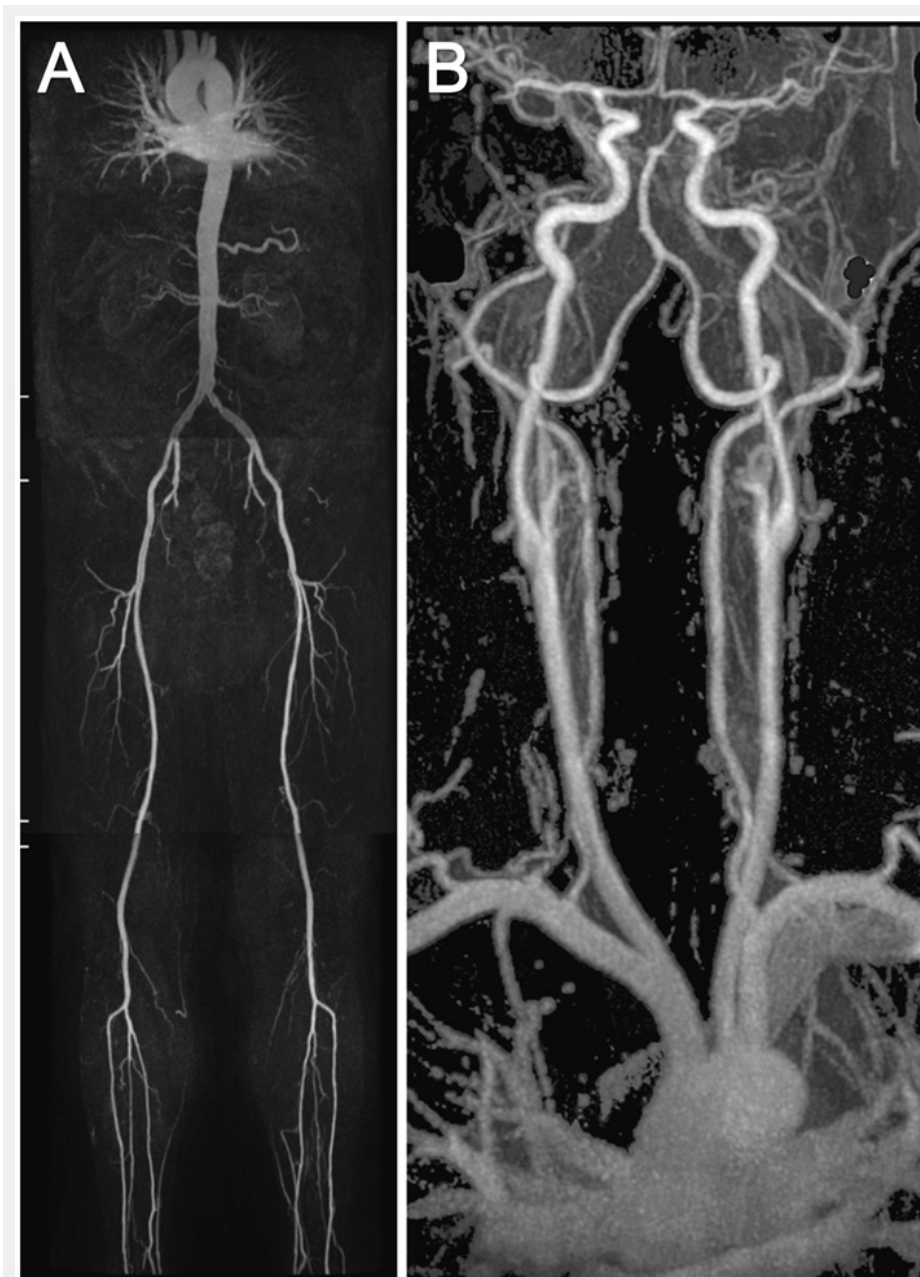Coronary angiography and renal MR angiography of the 3 women with renal artery abnormalities.

The left (images 1a, 1b, 1c) and right coronary (images 2a, 2b, 2c) angiography is shown for all three patients with the corresponding renal artery abnormalities (images 3a, 3b, 3c). Arrows in images 1a–c and 2a–c point at spontaneous coronary artery dissections. Arrows in images 3a–c point at renal artery fibromuscular dysplasia (3a, 3b) and renal artery dissection (3c).

- 11 Lacombe M. Isolated spontaneous dissection of the renal artery. *J Vasc Surg.* 2001;33:385–91.
- 12 Paris B, Bobrie G, Rossignol P, Le Coz S, Chedid A, Plouin PF. Blood pressure and renal outcomes in patients with kidney infarction and hypertension. *J Hypertens.* 2006;24:1649–54.
- 13 Spring DB, Salvatierra O, Jr., Palubinskas AJ, Amend WJ, Jr., Vincenti FG, Feduska NJ. Results and significance of angiography in potential kidney donors. *Radiology.* 1979;133:45–7.
- 14 Cragg AH, Smith TP, Thompson BH, Maroney TP, Stanson AW, Shaw GT, et al. Incidental fibromuscular dysplasia in potential renal donors: long-term clinical follow-up. *Radiology.* 1989;172:145–7.
- 15 Neymark E, LaBerge JM, Hirose R, Melzer JS, Kerlan RK Jr, Wilson MW, et al. Arteriographic detection of renovascular disease in potential renal donors: incidence and effect on donor surgery. *Radiology.* 2000;214:755–60.
- 16 Andreoni KA, Weeks SM, Gerber DA, Fair JH, Mauro MA, McCoy L, et al. Incidence of donor renal fibromuscular dysplasia: does it justify routine angiography? *Transplantation.* 2002;73:1112–6.
- 17 Lorenz EC, Vrtiska TJ, Lieske JC, Dillon JJ, Stegall MD, Li X, et al. Prevalence of renal artery and kidney abnormalities by computed tomography among healthy adults. *Clin J Am Soc Nephrol.* 2010;5:431–8.
- 18 Mortensen KH, Thuesen L, Kristensen IB, Christiansen EH. Spontaneous coronary artery dissection: a Western Denmark Heart Registry study. *Catheter Cardiovasc Interv.* 2009;74:710–7.
- 19 Koller PT, Cliffe CM, Ridley DJ. Immunosuppressive therapy for peripartum-type spontaneous coronary artery dissection: case report and review. *Clin Cardiol.* 1998;21:40–6.
- 20 Lie JT, Berg KK. Isolated fibromuscular dysplasia of the coronary arteries with spontaneous dissection and myocardial infarction. *Hum Pathol.* 1987;18:654–6.
- 21 Brodsky SV, Ramaswamy G, Chander P, Braun A. Ruptured cerebral aneurysm and acute coronary artery dissection in the setting of multivascular fibromuscular dysplasia: a case report. *Angiology.* 2007;58:764–7.



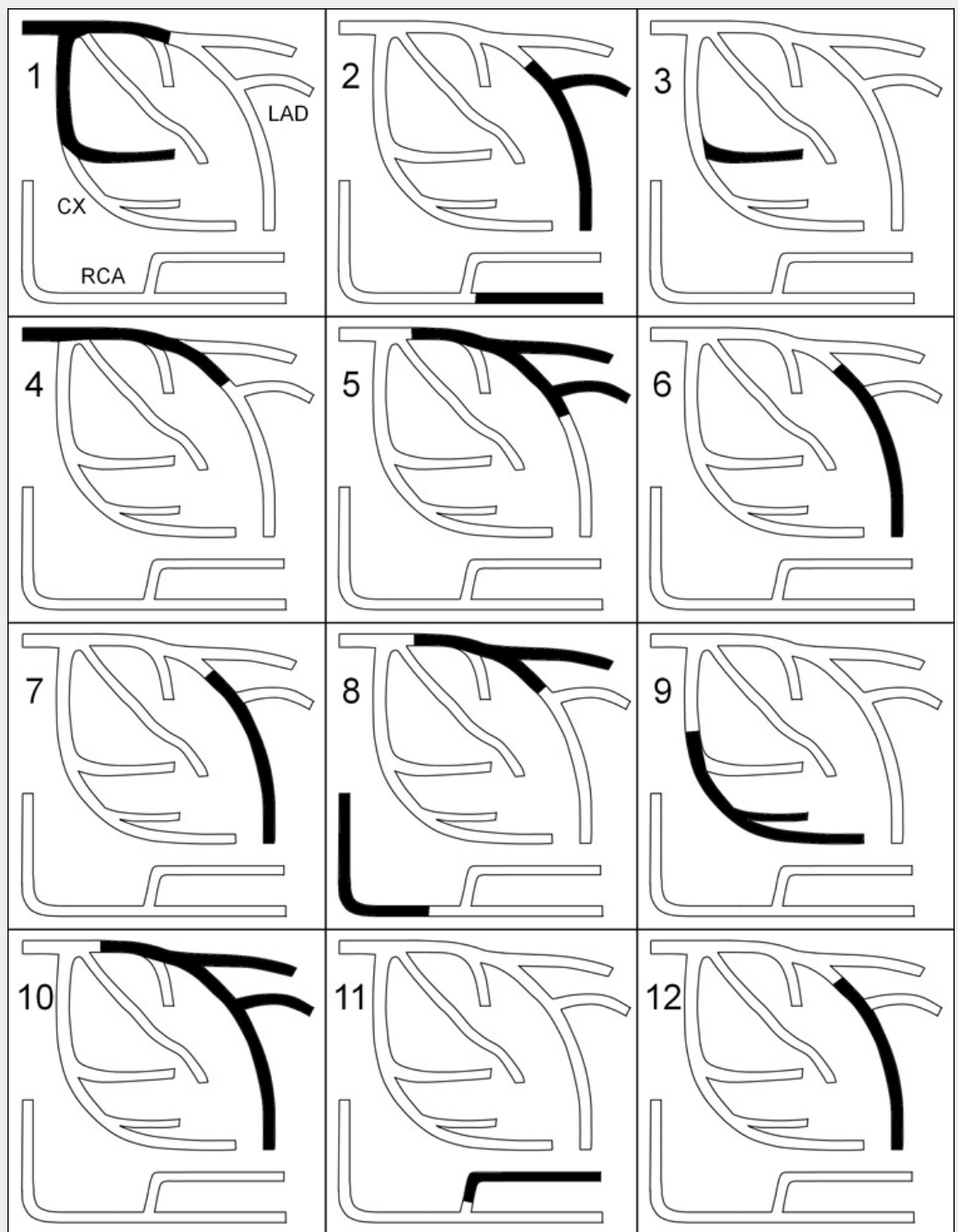
## Figures (large format)



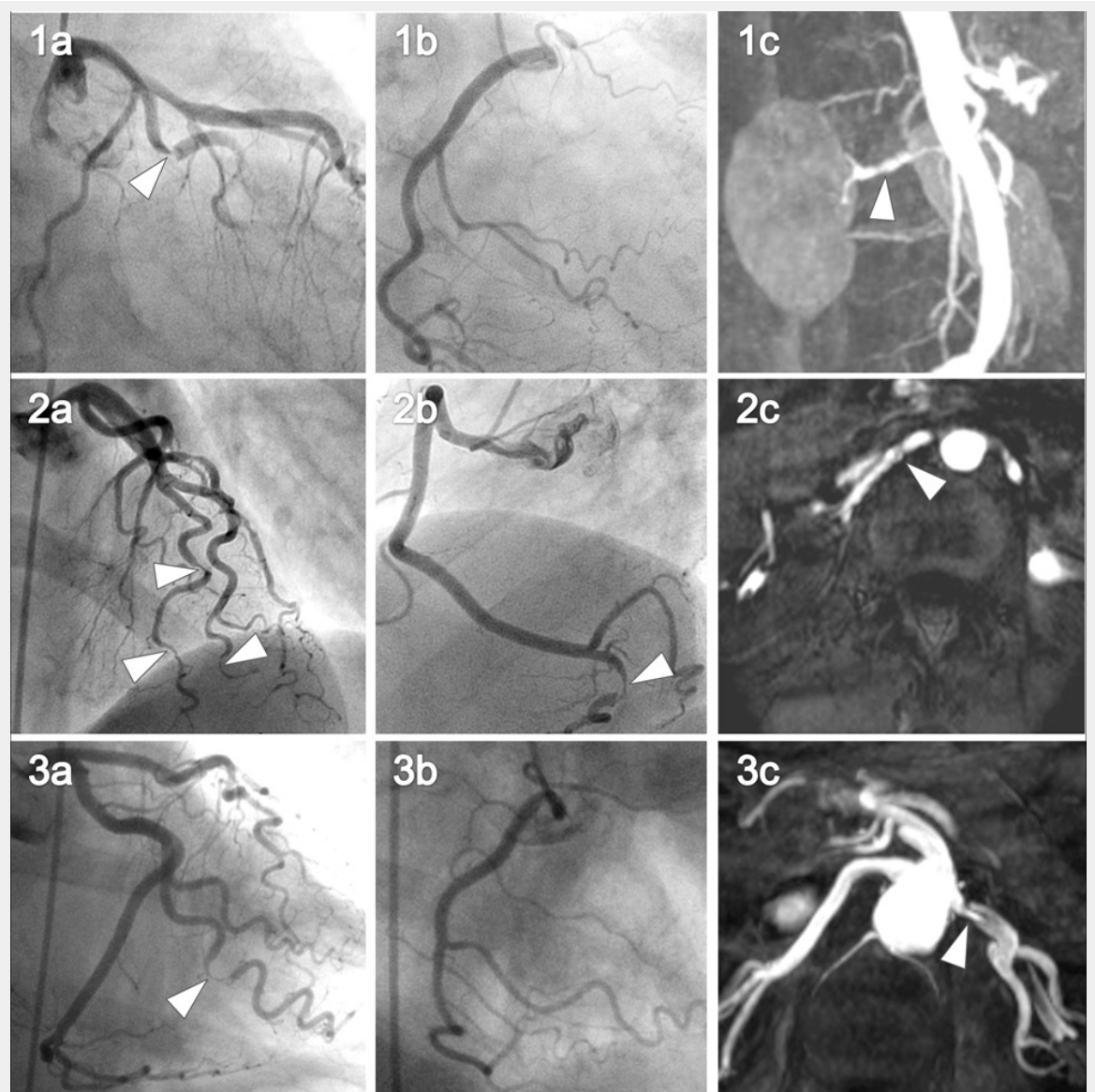
**Figure 1**

An example showing the MR whole body angiography.

The first part of the MR whole body angiography included thoracic/renal-, pelvis/thigh-, knee/calf-stations (A). The second part included the thoracic/carotid-station (B).



**Figure 2**  
Segmental distribution of coronary artery dissections in patients with (1–3) and without (4–12) renal artery abnormalities.



**Figure 3**

Coronary angiography and renal MR angiography of the 3 women with renal artery abnormalities.

The left (images 1a, 1b, 1c) and right coronary (images 2a, 2b, 2c) angiography is shown for all three patients with the corresponding renal artery abnormalities (images 3a, 3b, 3c). Arrows in images 1a–c and 2a–c point at spontaneous coronary artery dissections. Arrows in images 3a–c point at renal artery fibromuscular dysplasia (3a, 3b) and renal artery dissection (3c).